


Icon smooth surface

Case Reports

A series of case reports showing clinical challenges and their treatment solutions with Icon smooth surface.



Statement of Responsibility

The company DMG Dental-Material Gesellschaft mbH (DMG) is only the editor of this book Icon Case Reports (Case Reports).

All cases presented in the Case Reports are to be used only as a case study example and are not intended to replace medical advice offered by physicians. Diagnosis, treatments and medical procedures described in the presented cases are showing views, opinions and experimental examples of the respective author / physician and do not necessarily reflect the official policy or position of DMG. Assumptions and any application and / or preparation of Icon made within the Case Reports are solely those made and created by the authors and are not intended to replace reader's sole and independent judgment, verification of diagnoses, treatments and therapies. Therefore, with respect to the Case Reports neither DMG nor the authors can accept any legal responsibility for any errors or omissions that may be made or for the results obtained from the Case Reports. In particular, DMG does not assume any liability or responsibility for the accuracy, completeness, or usefulness of any information provided in Case Reports.

All content and images used in the Case Reports are owned or licensed by DMG. Unauthorized use is prohibited.

Content

CHAPTER 1: CARIOGENIC WHITE SPOT LESIONS.

Camouflage of a fluorotic change in the enamel with superimposed post-orthodontic decalcifications.	10
<i>Prof. Dr. Michael Knösel</i>	
Masking White Spot Lesions with Icon.	13
<i>Dr. Ingo Frank</i>	
Masking and arresting of caries during treatment with brackets.	16
<i>Prof. Dr. Hendrik Meyer-Lückel, Dr. Richard Johannes Wierichs, Fidaa Shikh Ali</i>	
Resin Infiltration of (Icon DMG) Post Orthodontic White Spot Lesions.	20
<i>Dr. Carla Cohn</i>	

CHAPTER 2: FLUOROSIS - MILD, MODERATE OR SEVERE.


Effective and predictable masking of mild to moderate fluorosis with in-office bleaching prior to resin infiltration.	24
<i>PD. Dr. Michael Wicht, Christoph Schoppmeier</i>	
Icon resin infiltration.	27
<i>Gabriela Caldeira Andrade Americano, Prof. Dr. Vera Mendes Soviero</i>	
Association of resin infiltration and composite resin on the treatment of severe dental fluorosis.	30
<i>Prof. Dr. Leandro Augusto Hilgert, Marília Bizinoto Silva Duarte</i>	
Fluorosis infiltration – Case study of a young patient.	34
<i>Dr. Arzu Tuna, Dr. Umut Baysal, Dr. Rainer Valentin</i>	
Resin Infiltration showing immediate esthetic improvement in non-pitted fluorosis.	36
<i>Prof. Dr. Neeraj Gugnani</i>	
Resin infiltration as a micro invasive treatment for fluorosis.	38
<i>Prof. Dr. Leandro Augusto Hilgert, Marília Bizinoto Silva Duarte</i>	
Case Report: Masking of fluorosis by resin infiltration.	42
<i>Prof. Dr. Sebastian Paris</i>	
Minimally invasive aesthetic restoration for severe dental fluorosis – combination resin infiltrating with at-home bleaching.	44
<i>Dr. Ryan Li</i>	
A noninvasive approach to treating white enamel lesions.	48
<i>Dr. Alexander Aresdahl</i>	
Masking Fluorotic Lesions with Icon.	50
<i>Associate Prof. Dr. Giuseppe Allocca</i>	

CHAPTER 3: TRAUMATIC HYPOMINERALISATION.

Treatment of traumatic hypomineralized teeth.	54
<i>Dr. Jean-Pierre Attal</i>	
Non-Invasive treatment of enamel hypomineralizations with Icon.	56
<i>Prof. Dr. Zafer Cehreli</i>	
Resin-infiltration procedure of white spots.	58
<i>Dr. Erik-Jan Muts</i>	
Minimally invasive approach in the treatment of enamel white spot lesions due to traumatic injuries of primary tooth: a clinical case.	61
<i>Dr. Ali Salehi</i>	
Deep Infiltration for traumatic hypomineralization: an esthetic and conservative treatment.	64
<i>Dr. Marie Clement</i>	

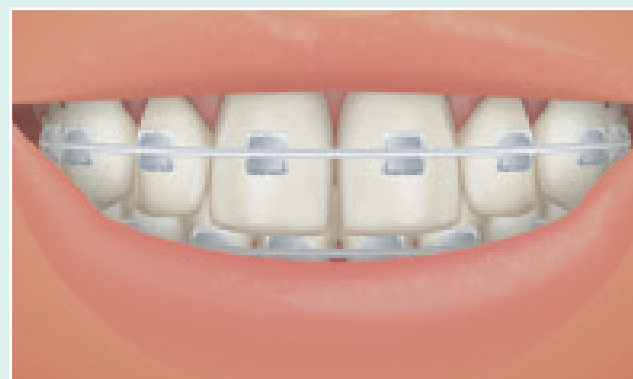
CHAPTER 4: MOLAR INCISOR HYPOMINERALISATION (MIH).

A new concept for treating enamel opacities.	68
<i>Prof. Dr. Nabiha Douki Zbidi, Dr. Omar Marouane, Dr. Fadwa Chtioui</i>	
Deep infiltration of MIH lesions: the use of transillumination as a diagnostic tool.	70
<i>Associate Prof. Carlos Rocha Gomes Torres, Associate Prof. Alessandra Bühler Borges.</i>	
Micro-invasive esthetic treatment for MIH lesions.	76
<i>Associate Prof. Carlos Rocha Gomes Torres, Daniele Mara da Silva Ávila, DDS, Ms, PhD Student</i>	



Cariogenic white spot lesions.

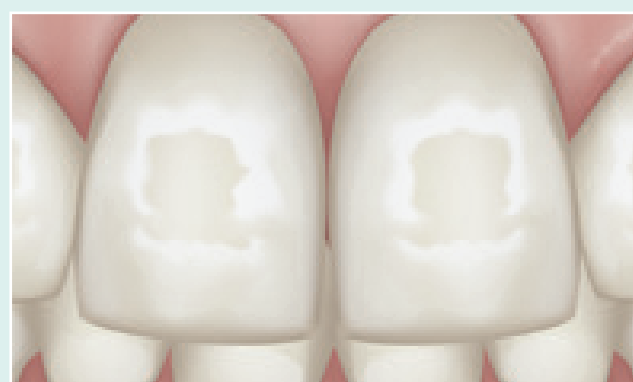Dental history and visual diagnosis.



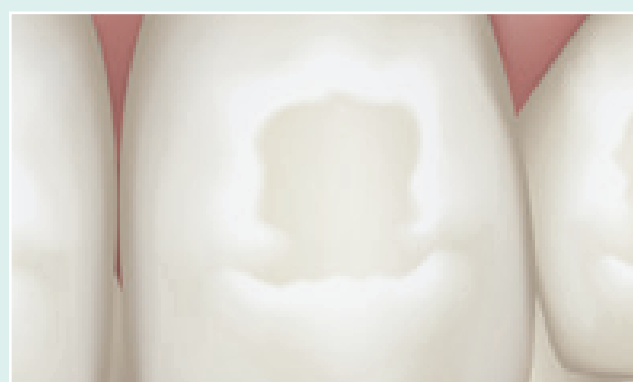
Patient history or etiology. Orthodontic treatment with fixed brackets.



Affected tooth/teeth. One or more teeth depending on the oral hygiene.



Localization. Typical around brackets. Mostly cervical.



Border. Well-demarcated.

Dental caries is one of the most prevalent diseases in the world and by far the most prevalent disease of the oral cavity. It is caused by the metabolic activity of the oral biofilm, which is triggered by the frequent intake of fermentable carbohydrates such as sugars. Characteristic for caries is a loss of minerals of the affected dental hard tissues. In younger patients, caries mostly starts in the dental enamel. The early and medium stages of the disease are characterized by an increased porosity of the affected enamel, which clinically appears as a white chalky spot due to increased light scattering between the crystals and the pores. In later stages the porous enamel breaks down and forms characteristic cavities.

Dental caries is a dynamic disease in which phases of mineral loss and mineral gain alternate. If mineral loss outbalances mineral gain, the disease progresses and the lesions are called »active«. If, however mineral gain predominates, lesions may arrest. Mineral gain is usually confined to the outermost 30-200 μm in the so-called surface layer of the lesion, whereas the lesion body remains porous. Therefore, even arrested lesions still look opaque and often are hard to discriminate from active lesions.

Caries lesions only form in tooth surfaces where dental plaque is allowed to grow for longer periods, the so-called predilection sites. As most of these sites are hidden, initial caries usually is not an esthetic problem. However, during treatment with orthodontic brackets caries lesions may also form in buccal free smooth surfaces. After debonding of brackets, these lesions usually can be arrested quite easily by brushing and fluoride application. However, the unaesthetic appearance of the whitish spots often persists or even gets worse due to inclusion of food stains in the surface layer, which makes the lesions look brownish.

Caries infiltration originally was developed to arrest non-cavitated caries lesions. One positive side-effect of the treatment is that the whitish color of enamel lesions disappears during and after infiltration as the infiltrated resin reduces the light scattering between the enamel crystals. In this way lesions can be camouflaged and an esthetic improvement can be achieved quite easily with only minimal substance loss.

Prof. Dr. Sebastian Paris

Camouflage of a fluorotic change in the enamel with superimposed post- orthodontic decalcifications.

Prof. Dr. Michael Knösel

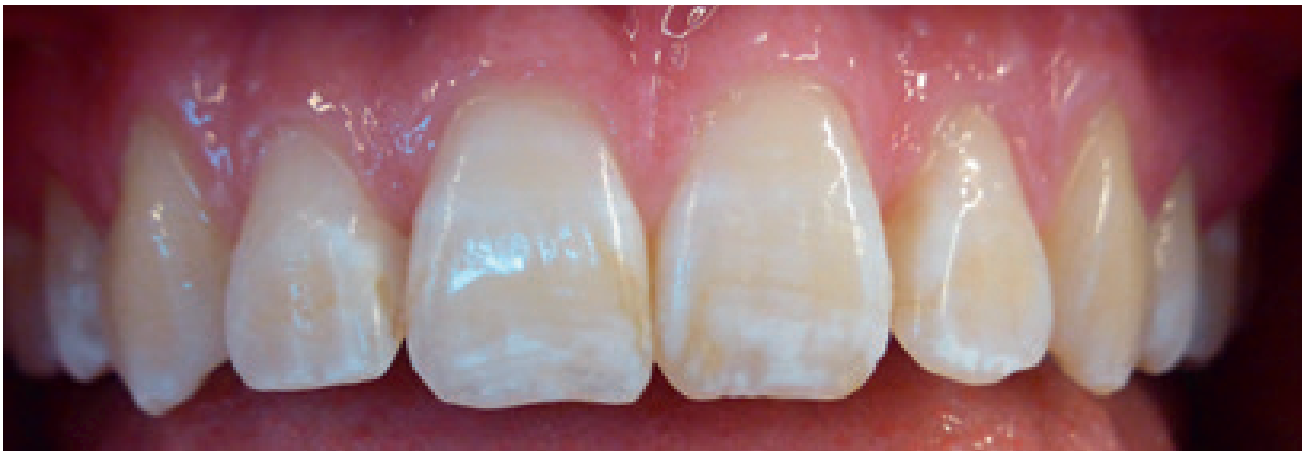

Fig. 1

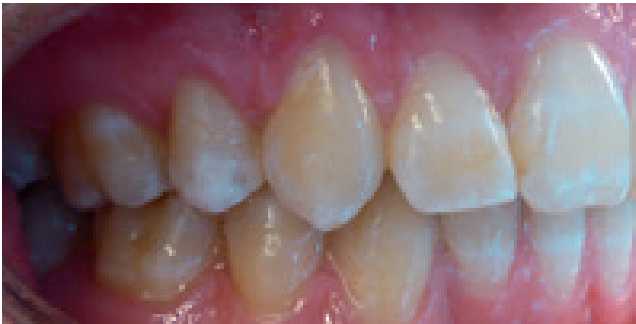

Fig. 2

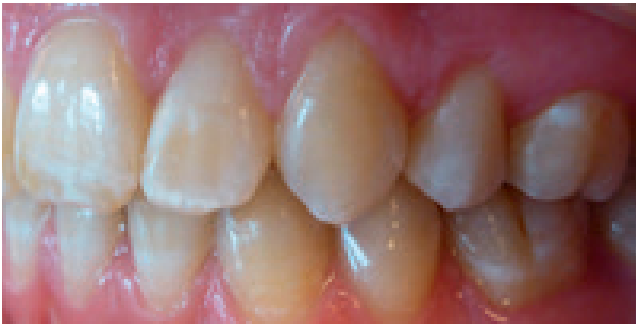

Fig. 3

Fig.1-3: Initial situation: Enamel fluorosis with superimposed post-orthodontic decalcifications.

A 16 year-old patient presented with a request for visual improvement of the anterior esthetics impaired by irregularly distributed whitish enamel spots. A treatment performed elsewhere with fixed orthodontic devices (multi-bracket (MB) devices) was completed roughly one year before; in the course of this treatment four premolars were removed and the gaps closed. The subsequent retention of the final result was performed with fixed retainers in the upper and lower jaws, which were in situ at the time of presentation. In a visual and tactile examination the whitish opaque spots were diagnosed, because of their striated appearance without sharply defined edges, as fluorotic change in the enamel, visible in a varied

distribution on all present teeth, and, in the case of the premolars in particular, very clearly including the occlusal surfaces. Furthermore, under closer examination and after drying, it was possible to identify a border around the area that was previously covered by the bracket bases of the MB device, in particular on the maxillary canines and lateral and central incisors. Moreover, striated changes could also be seen underneath the former bracket bases. The suspicion that the patient has an enamel fluorosis with superimposed post-orthodontic decalcifications is consistent with the information provided by the patient in relation to a worsening of the spotting during the MB treatment.

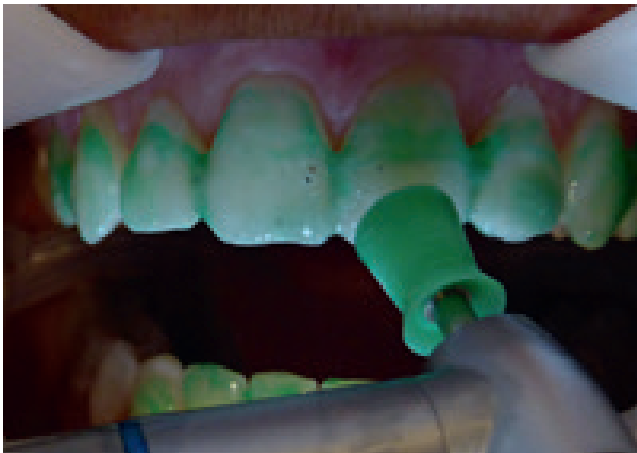

Fig. 4: Use of a hand-made micro-abrasive slurry of roughly 15% HCl/pumice powder (acid-pumice technique) with a polishing cup at low rotational speed.

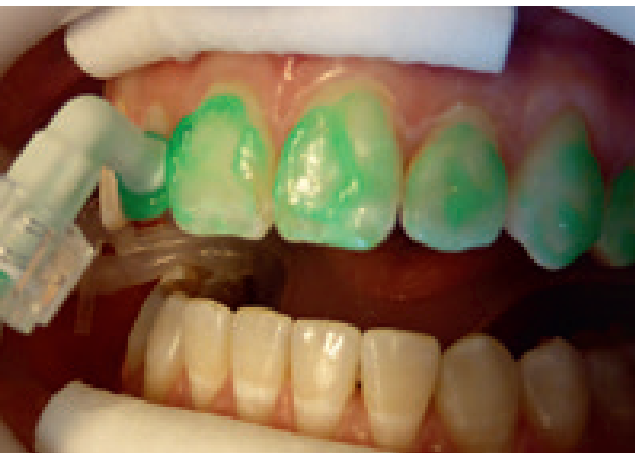

Fig. 5: Application of Icon-Etch for two minutes.

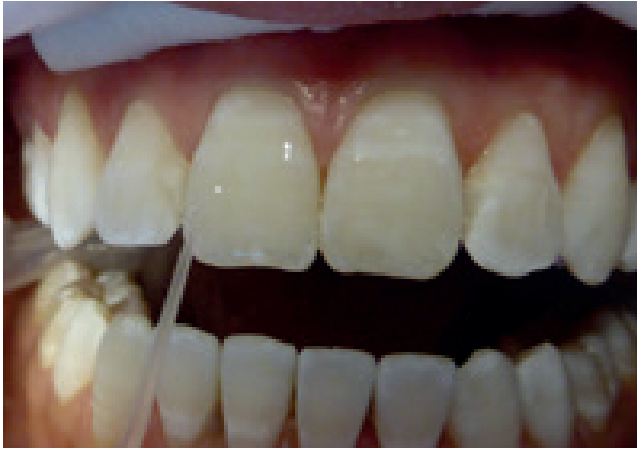

Fig. 6: Drying with Icon-Dry.

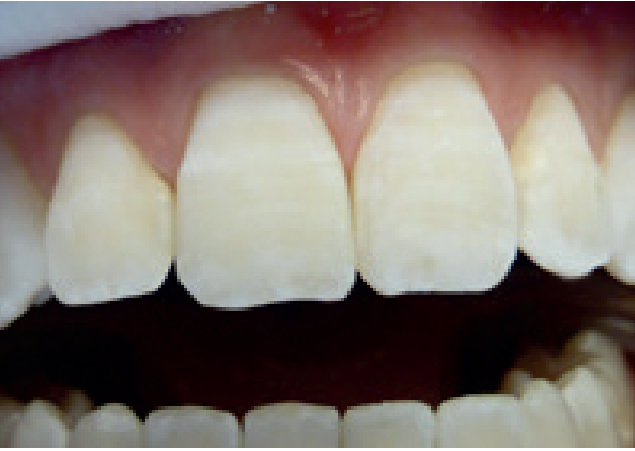

Fig. 7: Result after etching with Icon-Etch five times.

The patient had previously found information on potential forms of treatment on the Internet and volunteered a strong desire for infiltration treatment to improve the dentofacial esthetics. Together with the patient, the scope of the treatment was determined: treatment of the changes in enamel in the esthetically relevant areas of teeth 15-25 (with teeth 14/24 missing) and 33-43. For successful treatment of pronounced fluorotic enamel changes and also deep WSL, the literature describes micro-abrasive slurries comprising roughly 15% HCl/pumice powder (acid-pumice technique) [1-4]. Because using an infiltration technique exclusively was deemed difficult given the initial situation (enamel fluorosis with superimposed post-orthodontic decalcifications, and some micro-cracked enamel structures as on tooth 12), it was decided to proceed with a combined method to improve the result of the fluorosis infiltration: The HCl acid gel contained in the infiltration kit and pumice powder (Ernst Hinrichs Dental, Goslar) were used to prepare a slurry to selectively pre-treat areas with deep fluorotic changes. This was done by carefully working on the affected teeth 15-25 and 33-43 with a polishing cup and the slurry at a low rotational speed. After the slurry was rinsed away, the infiltration treatment followed, with the HCl gel applied to the affected enamel areas and left for two minutes in each case.

Applying a rubber dam, in particular in the area of the lower incisors, often prevents conditioning and infiltration of the areas near the gingiva; this measure was therefore deliberately avoided. After the gel was rinsed away, drying was performed in each case with the ethanol contained in the kit. Drying with ethanol is vital for achieving the capillary effect required for infiltration; it also makes it possible to assess the esthetic result that can be expected. This assessment was performed together with the patient; in this case, the HCl steps were repeated five times to prepare the enamel surfaces sufficiently to achieve the desired esthetic result. This was followed by infiltration; the infiltrant was left for three minutes and subsequently light-polymerized. A second infiltrant application was performed, which is recommended with a reaction time of one minute to compensate for the composite polymerization shrinkage, followed by further light-curing and polishing of the infiltrated enamel areas. After infiltration, a significant masking was apparent, deemed highly satisfactory by the patient, of both the fluorotic enamel areas and the enamel areas decalcified by the orthodontic treatment.

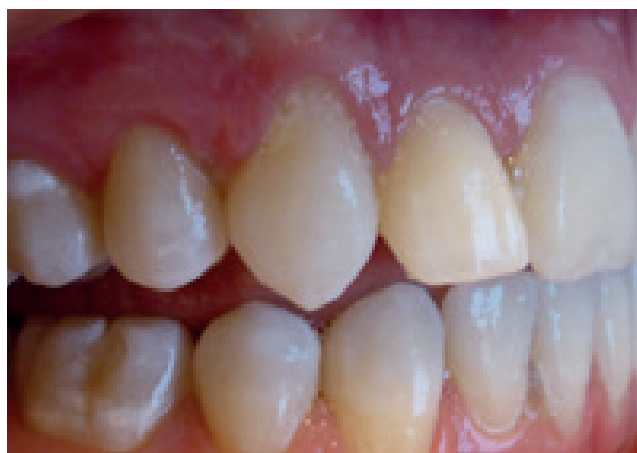

Fig. 8

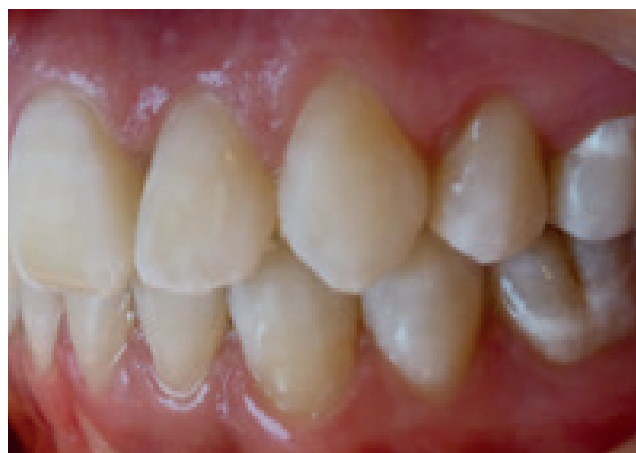

Fig. 9

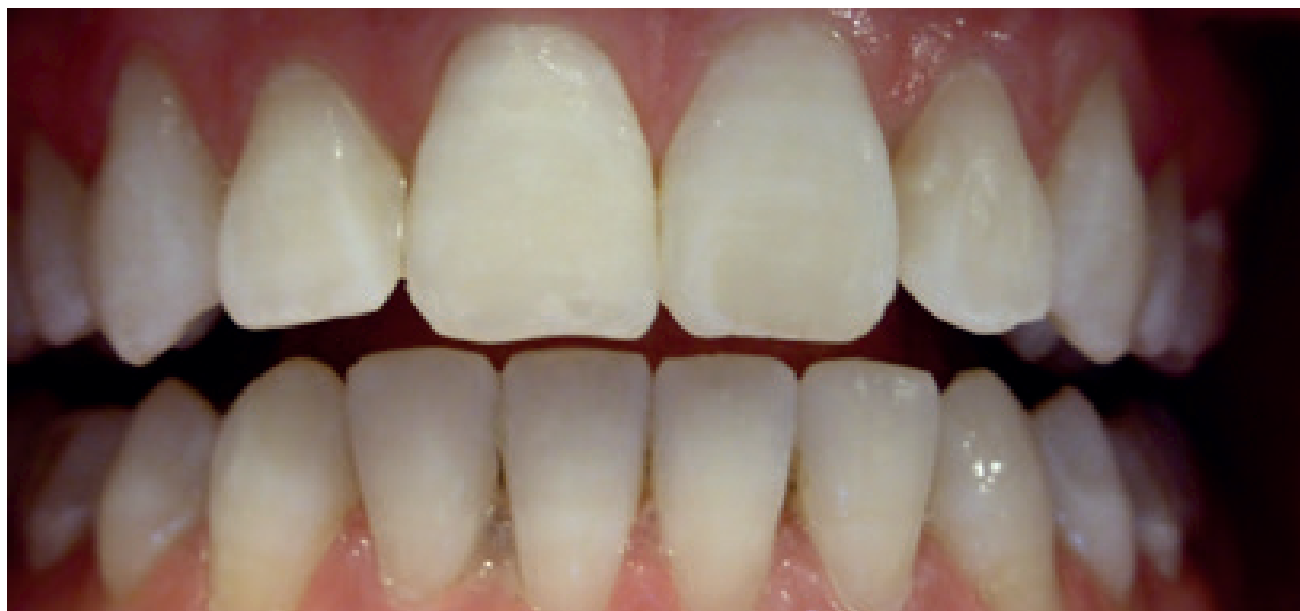

Fig. 10

Fig: 8-10: Significant masking after infiltration, deemed highly satisfactory by the patient, of both the fluorotic enamel areas and the enamel areas decalcified by the orthodontic treatment.

Key Learnings

- Icon infiltration treatment can get satisfactory esthetic results on the patients suffering from both post-orthodontic decalcifications and fluorosis.
- In order to remove the well mineralized enamel surface layer, Icon-Etch gel can be combined with microabrasion pumice and can even be used for more than three times.
- Icon-Dry can predict the esthetic result after Icon-Infiltrant. This assessment should be performed together with the patient.

References

1. Welbury RR, Carter NE. The hydrochloric acid-pumice microabrasion technique in the treatment of post-orthodontic decalcification. *Br J Orthod.* 1993;20:181–185
2. Croll TP, Cavanaugh RR. Enamel color modification by controlled hydrochloric acid-pumice abrasion. I. Technique and examples. *Quintessence Int.* 1986;17:81–87.
3. Murphy TC, Willmot DR, Rodd HD. Management of postorthodontic demineralized white lesions with microabrasion: a quantitative assessment. *Am J Orthod Dentofacial Orthop.* 2007;131:27–33.
4. Akin M, Basciftci FA. Can white spot lesions be treated effectively? *Angle Orthod.* 2012;82:770–775.)

Masking White Spot Lesions with Icon.

Dr. Ingo Frank

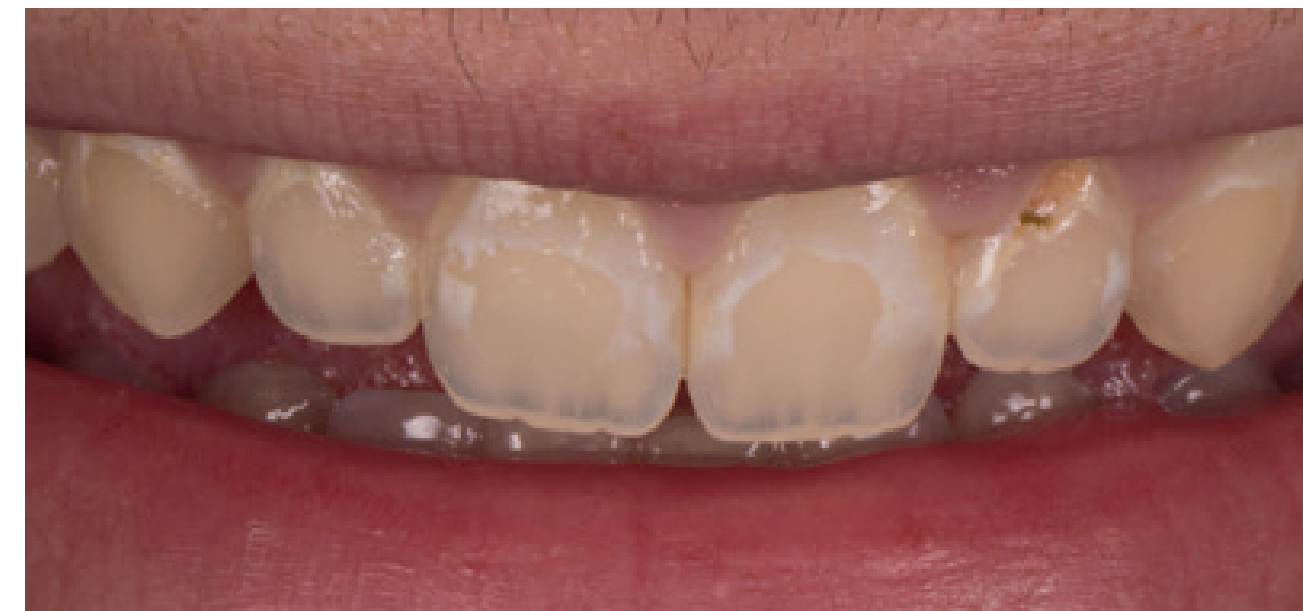

Fig. 1: Initial situation before treatment with Icon.

White spot lesions are early signs of demineralization under an apparently intact enamel surface layer. These early enamel lesions show a whitish appearance as a result of an increased porosity within the lesion due to mineral loss [1].

In case of poor oral hygiene or salivary hypofunction even on buccal surfaces of the teeth a plaque accumulation can result in white spot lesions [2]. Especially in patients that underwent orthodontic treatment with brackets white spot lesions can occur due to the difficulties to clean the area adjacent to the bracket. Several clinical studies show a high prevalence of white spot lesions after bracket removal [3, 4].

With preventive strategies like improvement of the oral hygiene and topical fluoride application there is a good chance of arresting early lesions. Though the caries progression may be stopped the whitish appearance often remains as the remineralization is superficial and there is still a porous lesion body underneath [2]. In addition to that stains can be incorporated into the lesion with the result of a brownish appearance of the lesion (brown spots) which often leads to even more esthetic deficiencies. That is why the dentist may become confronted with the patients desire to rehabilitate esthetics. Treating non-cavitated white spot lesions may include tooth

bleaching, micro-abrasion, composite fillings or even prosthetic restorations like veneers or combinations of these treatments [5]. All these options are quite invasive implying tooth structure loss. As a micro-invasive alternative caries infiltration (Icon) can be applied to prevent further caries progression. It imbeds the adjunctive effect of masking the whitish appearance of the lesions.

With the infiltrant the porosities in the lesion body are occluded. Therefore, this treatment may be used not only to arrest enamel lesions but also to improve the esthetic appearance of buccal white spots.

Clinical case report

A 19 year-old male patient complained about the appearance of his upper front teeth due to whitish lesions on the vestibular surfaces. He had an orthodontic treatment with brackets during adolescence and when the brackets were removed the white spot lesions became apparent.

In order to fulfill the patient's desire of an esthetic improvement we suggested an Icon treatment to mask the lesions.

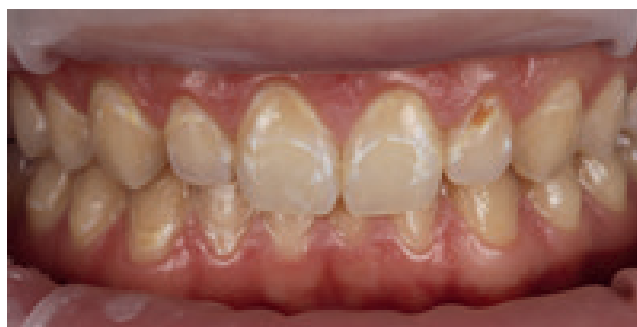

Fig. 2

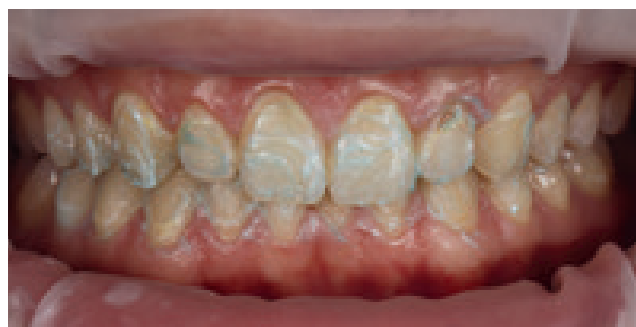

Fig. 3

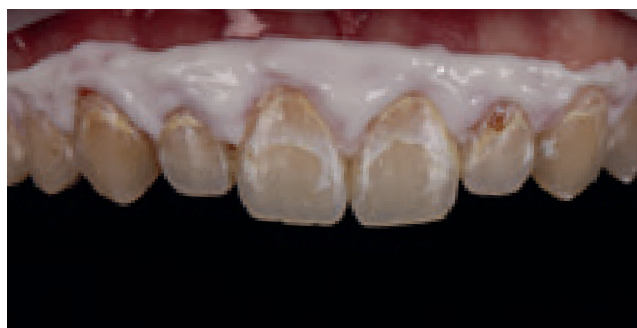


Fig. 4

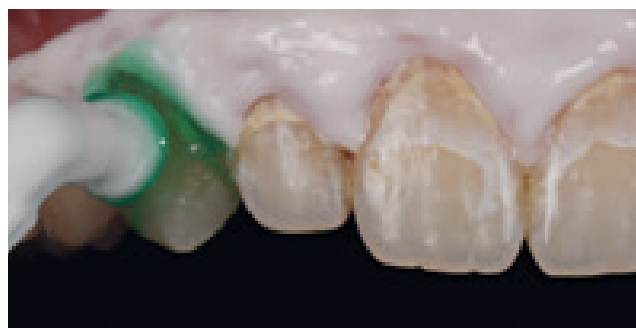

Fig. 5

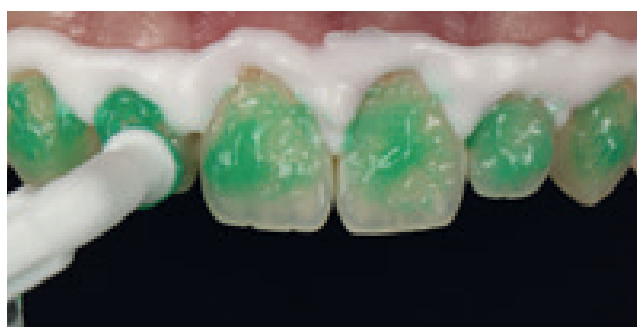

Fig. 6

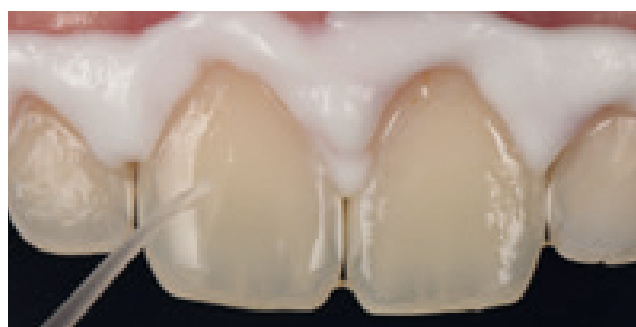

Fig. 7

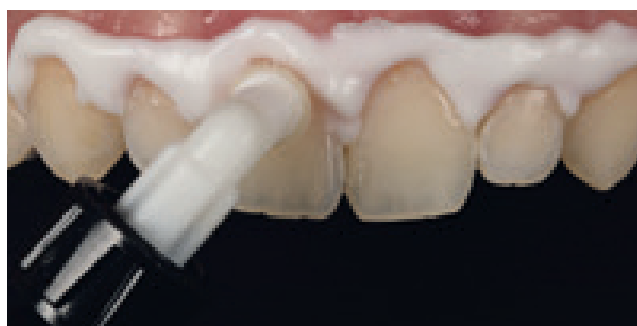

Fig. 8

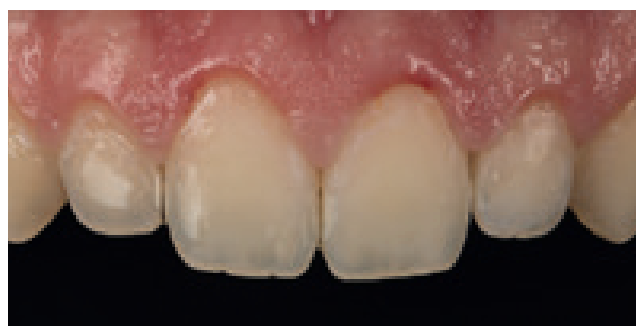

Fig. 9

Fig. 2: In order to get an accessible isolated working field optragate was applied. Fig. 3: Professional cleaning of the vestibular surfaces with fluoride free prophylaxis paste. Fig. 4: For the application of Icon an optimal dry working field is mandatory. Furthermore any contact of the material with the gingiva should be avoided. In this case the liquid dam was applied. Fig. 5: Application of the Icon-Etch for 2 minutes to condition the lesion surface. Fig. 6: The etching gel is covering all white spot lesions of the vestibular surface of the teeth 13-23. The cavitated lesion on the vestibular surface of tooth 22 has been treated with a composite filling. After 2 minutes the etching gel is removed with water spray for 30 seconds and the surface is dried. Fig. 7: When Icon-Dry is applied, the lesions disappear for the

wetting moment. This gives the operator a preview of the results. If the whitish-opaque coloration on the etched enamel diminishes, the procedure can be continued with the infiltrant application. If the lesions are still visible, the etching step should be repeated. After 30 seconds the surfaces are thoroughly dried with oil free and water-free air. Fig. 8: Application of the infiltrant. Fig. 9: After the infiltrant has been applied on all treated surfaces, the infiltrant is set for 3 minutes. Excess material is removed with a cotton wad and dental floss before it is light cured for 40s. This infiltrant step is repeated letting the infiltrant set again for 1 minute before excess removal and light curing. Finally the surfaces are polished.

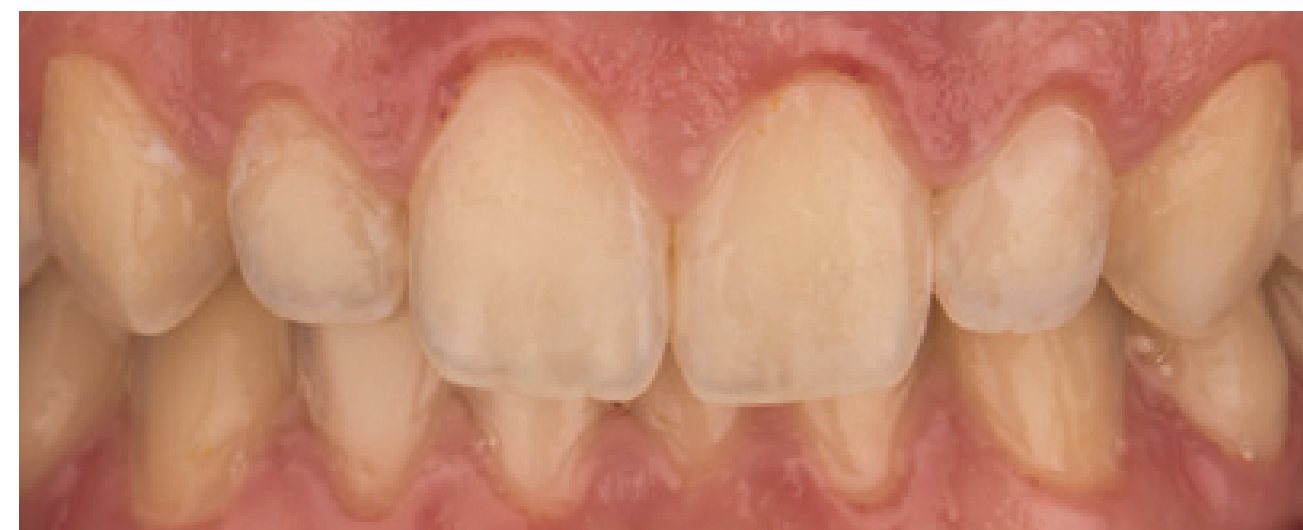

Fig. 10: Final result after Icon treatment.

The white spot lesions are masked and a highly satisfying result with large improvement of the esthetic appearance could be achieved.

Discussion

The manifestation of white spot lesions after bracket removal is a common side effect due to the impeded oral hygiene adjacent to the bracket during orthodontic treatment [3, 4, 6]. As esthetic demands of the patients arise dentists do not only have to take care of preventing a further progression of the lesions but also have to deal with the patient's wishes of masking these lesions which can be esthetic compromising. In contrast to other treatment options like composite filling, micro-abrasion or bleaching, Icon offers a micro-invasive treatment tool without drilling that can not only stop the lesions progressions but also can mask the whitish appearance of the white spot lesions. In case of adjacent cavitated lesions Icon can be successfully combined with a conventional filling in this area. When the cavitated lesion is restricted to enamel the infiltrant even enhances the shear bond strength of the adhesive [7]. Filling procedure and infiltration can be combined in one step. When the cavitation involves dentin the filling should be performed before the Icon treatment as the hydrochloric acid of the Icon-Etch might lead to a decrease of shear bond strength of the adhesive to dentin [8].

Conclusion

With Icon white spot lesions can be masked effectively. It is micro-invasive to the treated enamel surfaces, prevents further demineralization and is easy in handling and application. In case of white spot lesions occurring next to cavitated lesions Icon can successfully be combined with a conventional filling of the cavitated lesion.

Key Learnings

- Infiltration treatment can be combined with direct composite restoration when both white spots and cavitated caries lesion exist on enamel.
- When the cavitated lesion is restricted to enamel the infiltrant even enhances the shear bond strength of the adhesive. Filling procedure and infiltration can be combined in one step.
- When the cavitation involves dentin, the filling should be performed before the Icon treatment as the hydrochloric acid of the Icon-Etch might lead to a decrease of shear bond strength of the adhesive to dentin.

References

- Lee JH, Kim DG, Park CJ, Cho LR. Minimally invasive treatment for esthetic enhancement of white spot lesion in adjacent tooth. *The journal of advanced prosthodontics*. 2013;5(3):359-63.
- Paris S, Meyer-Lueckel H. Masking of labial enamel white spot lesions by resin infiltration – a clinical report. *Quintessence international*. 2009;40(9):713-8.
- Gorelick L, Geiger AM, Gwinnett AJ. Incidence of white spot formation after bonding and banding. *American journal of orthodontics*. 1982;81(2):93-8.
- Hadler-Olsen S, Sandvik K, El-Agroudi MA, Ogaard B. The incidence of caries and white spot lesions in orthodontically treated adolescents with a comprehensive caries prophylactic regimen – a prospective study. *European journal of orthodontics*. 2012;34(5):633-9.
- Kim S, Kim EY, Jeong TS, Kim JW. The evaluation of resin infiltration for masking labial enamel white spot lesions. *International journal of paediatric dentistry / the British Paedodontic Society [and] the International Association of Dentistry for Children*. 2011;21(4):241-8.
- Richter AE, Arruda AO, Peters MC, Sohn W. Incidence of caries lesions among patients treated with comprehensive orthodontics. *American journal of orthodontics and dentofacial orthopedics : official publication of the American Association of Orthodontists, its constituent societies, and the American Board of Orthodontics*. 2011;139(5):657-64.
- Jia L, Stawarczyk B, Schmidlin PR, Attin T, Wiegand A. Effect of caries infiltrant application on shear bond strength of different adhesive systems to sound and demineralized enamel. *J Adhes Dent*. 2012 Dec;14(6):569-74.
- Jia L, Stawarczyk B, Schmidlin PR, Attin T, Wiegand A. Influence of caries infiltrant contamination on shear bond strength of different adhesives to dentin. *Clinical oral investigations*. 2013;17(2):643-8.

Masking and arresting of caries during treatment with brackets.

Prof. Dr. Hendrik Meyer-Lückel, Dr. Richard Johannes Wierichs, Fidaa Shikh Ali

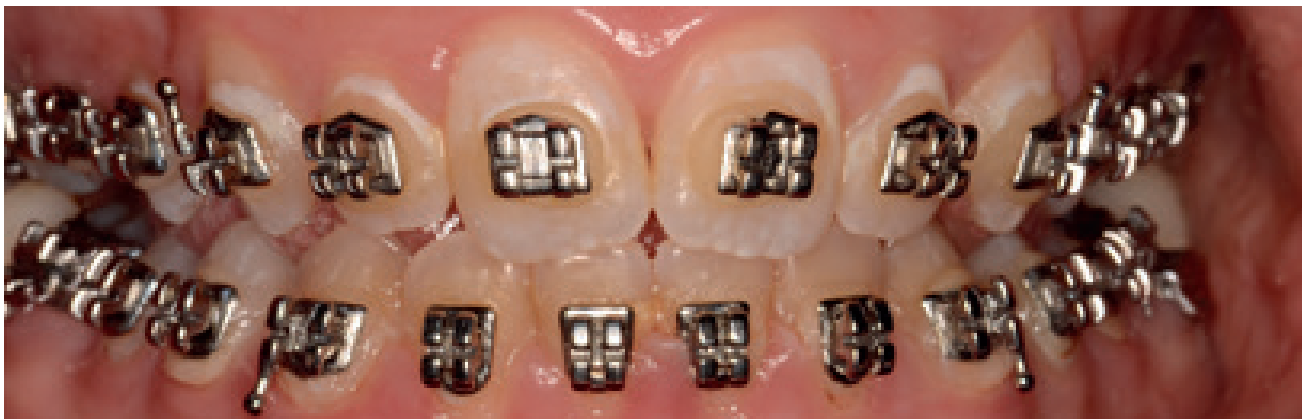

Fig. 1: Situation before treatment.

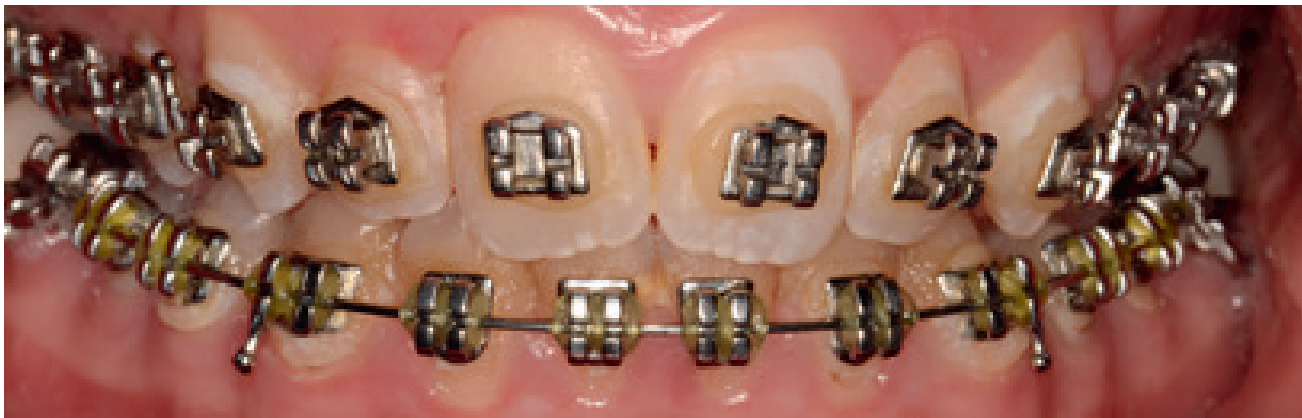


Fig. 2: One week after treatment.

Introduction

White spot lesions (WSL) are non-cavitated caries lesions that are often observed in the esthetical visible area [2,7]. During orthodontic treatment with fixed elements (brackets) plaque retention is increased resulting in a higher risk for new WSL [16]. In a study on premolars being referred for extraction it could be shown that the development of WSL occurs within 4 weeks under fixed, but non-cemented orthodontic bands [12]. Due to the design of orthodontic appliances biofilm is frequently not sufficiently removed by oral hygiene measures. It is, thus, no surprise that after orthodontic treatment a WSL prevalence between 11 % [18] and 97 % [1] and a WSL incidence between 7 % [17] and 73 % [15] has been reported. The varying values can be explained by, firstly, different examination methods and, secondly, by the use of different thresholds to detect WSL.

To prevent caries lesions during orthodontic treatment an optimal oral hygiene is crucial [16]. However, if WSL are detected after an orthodontic treatment it seems to be related to the type of lesion whether a complete remineralization can be achieved [12]. On the one hand, slightly visible, initial WSL often completely remineralize in saliva, since fixed elements – increasing the plaque retention – have been removed. The remineralizing effect can be increased by the additional use of fluoride e.g. in form of fluoride varnish [12,17]. On the other hand, clearly visible, severe WSL cannot be visually masked by saliva and fluoride alone. They remain visible for life. Thus, for severe WSL more invasive treatments are indicated. During orthodontic treatment rapid debonding may be required unless oral hygiene and fluoride regimens are followed accurately [12] whereas after orthodontic treatment the appearance of the WSL should be masked.

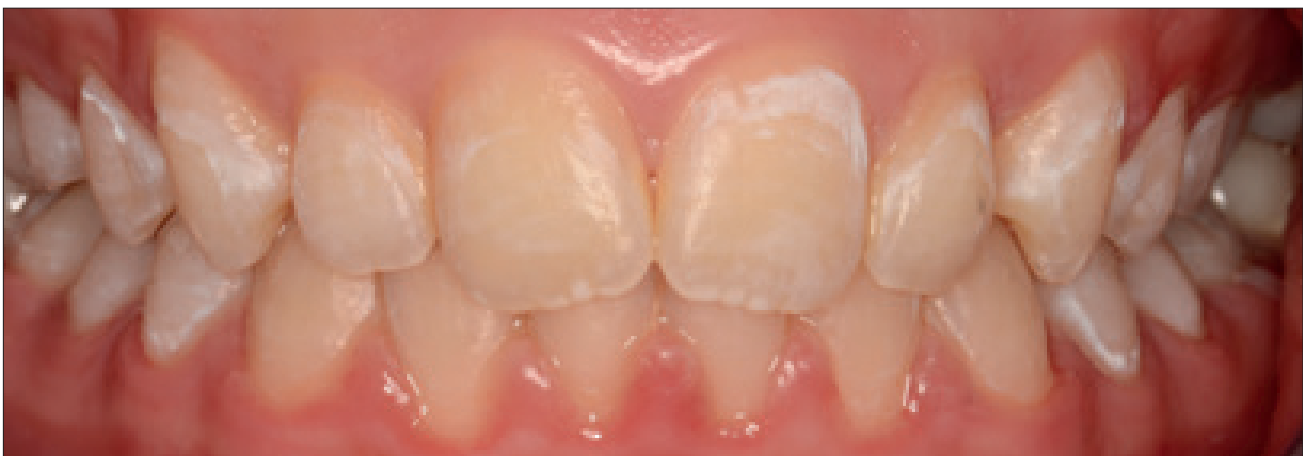

Fig. 3: Directly after removal of the brackets.

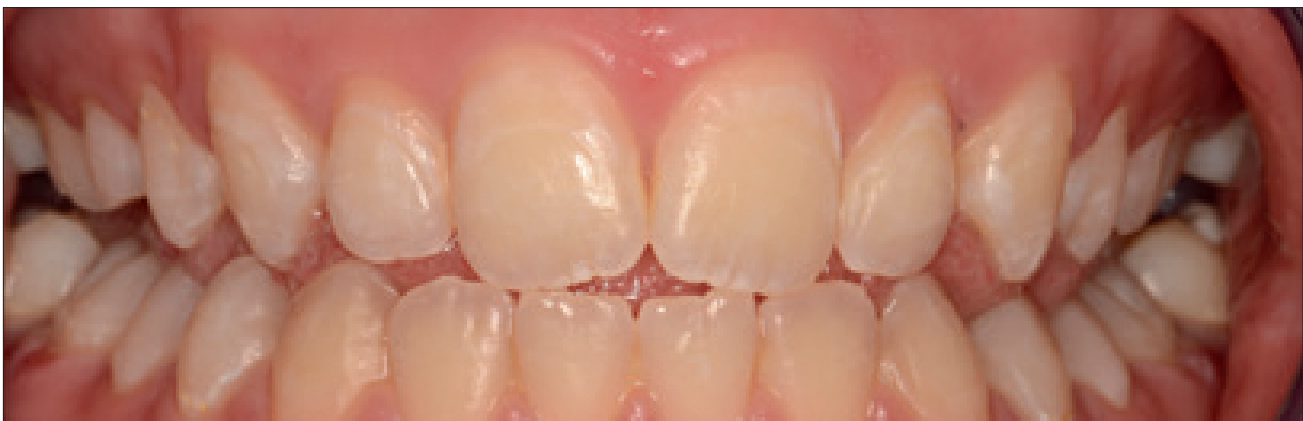

Fig. 4: One week after removal of the brackets and after infiltration of the control teeth.

Caries infiltration is one method to mask initial non-cavitated lesions. By infiltrating the lesion microporosities of the carious enamel are obturated. Thus, the caries progression is arrested. Furthermore, due to the similar refractive index of the infiltrant (RI of infiltrant 1.52) compared with apatite (RI=1.62), light scattering is reduced and visual color differences to enamel are decreased directly after application. Thus, the visual appearance of the lesion is changed positively and the WSL appears less white than before; in other word: the lesion is masked [10, 14].

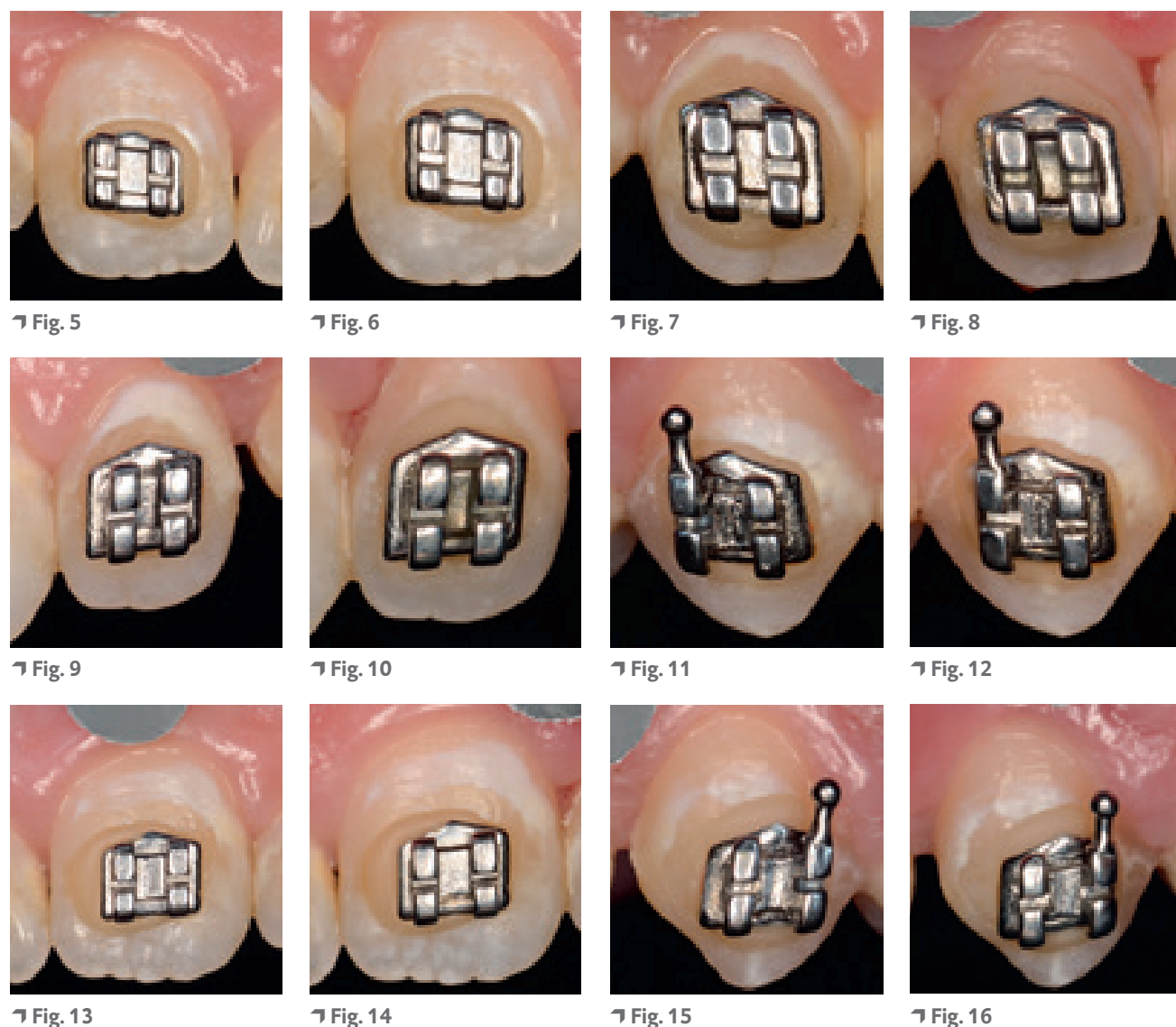
In several studies on WSL – being diagnosed after orthodontic treatment with fixed elements – a positive masking effect after the infiltration was observed [3, 4, 5, 6, 8, 9]. Furthermore, the masking effect was classified as satisfactory (although not complete) in further studies [4, 5, 8, 11]. Interestingly, the time between debonding and infiltration seems to play an important role in order to allow an effective masking of WSL [9]. The shorter the time after debonding the better the masking effect. This observation was supported in a second non-controlled study [13]. In this study the masking effect of caries infiltration was examined during the treatment with fixed orthodontic elements. Immediately after the detection of a WSL the bracket was removed, the WSL was infiltrated and the bracket was rebonded. During the subsequent 10-month follow-up 92.5 % of the infiltrated WSL showed no further worsening.

On the basis of the previous studies the success of the masking effect seems to depend on the time between detection of the WSL, debonding and infiltration. Shorter time periods between

debonding and infiltration seem to mask WSL more effectively. This raises the question if the esthetical outcome can be optimized by infiltrating WSL during the orthodontic treatment. Moreover, infiltration during orthodontic treatment arrests the lesion progress at an earlier point in time.

Case report

A 15-year-old female patient complained of white spots in the esthetical visible area. The lesions were observed after a 24-month orthodontic treatment with fixed elements. The patient's main concern was to stop lesion progression with a minimal-invasive treatment without interrupting the orthodontic treatment. The patient was in good general health. ICDAS criteria were used for the visual-tactile assessment of the WSL [11]. Furthermore, photo documentation was performed to assess the severity of the lesions [19]. The clinical examination revealed an ICDAS level of 2 for six teeth, two of these being active lesions. The patient was asked to participate in a monocentric, controlled, randomized split-mouth study. After informed consent teeth with WSL were randomly divided into two groups. Without removing the brackets, teeth in the control group (teeth 13, 21, 23) were treated with a fluoride varnish (Tiefenfluorid®, Humanchemie, Alfeld/Leine) and those in the test group (teeth 12, 11, 22) were infiltrated with a low-viscosity polymer (Icon-Infiltrant, DMG, Hamburg) and subsequently fluoridated in the same way as the control group.



Tiefenfluorid® was applied on all teeth as followed:

- Application of the primary application solution (1 min per tooth)
- Application of the secondary application solution (1 min per tooth)

The infiltration was performed as followed:

- a. Etching the teeth with Icon-Etch (15% HCl gel for 2 min)
- b. Removing Icon-Etch and Rinsing by using the multifunction syringe (30 s per tooth)
- c. Drying the teeth by using the multifunction syringe (30 s per tooth)
- d. Application of Icon-Dry (30 s per tooth)
- e. Drying the teeth by using the multifunction syringe (10 s per tooth)
- f. Application of Icon-Infiltrant (3 min per tooth)
- g. Removing excess material with a foam pellet
- h. Light-curing (40 s per tooth)
- i. Application of Icon-Infiltrant (1 min per tooth)
- j. Removing excess material with a foam pellet
- k. Light-curing (40 s per tooth)
- l. Polishing (dark orange and light orange Soflex disc or pink and gray rubber polisher) and Occlubrush

The steps (a-e) were repeated up to three times – if necessary – until a satisfactory esthetic result was achieved. Afterwards Tiefenfluorid® was applied as described above.

The ICDAS score was evaluated at various points in time: before treatment (baseline), one day after the treatment (d1), one week after the treatment (d7), directly after removal of the brackets (removal) – the control teeth were infiltrated during this appointment – and one week after infiltration of the control teeth (r7) (Figs. 1-4). In the present case report the time between baseline and removal was roughly two months. In the actual study, a minimum time interval of at least six months is planned to allow a more precise assessment of the control group.

For colorimetric analysis the CIE L*a*b* values were measured using Photoshop CS 6 (Adobe, USA). Color differences between carious and healthy enamel (ΔE) were then calculated [19].

At baseline no significant difference in ICDAS-values (average \pm standard deviation) and the ΔE -values (mean ΔE : 18.68; SD:5.26) between the control and test group were observed. One day after (d1) and one week after (d7) the treatment a significant reduction in the ΔE -values could be observed in the test group (Figs. 5-10), whereas no significant change could be observed in the control

group (Figs. 11-16). One week after the treatment (d7), the WSL were masked more completely than one day after infiltration (d1). Two of the three teeth in the test group (11,12) showed a reduction in the ICDAS level from 2 to 1 one day after (d1) as well as one week (d7) after treatment. Contrastingly, no change in the ICDAS level could be observed in the control group. In both groups the colorimetric analysis correlated with the clinical outcome.

Conclusion

The visual appearance of WSL were improved by caries infiltration. The patient reported no significant adverse event after infiltration.

Fig. 1: Situation before treatment.

Fig. 2: Situation one week after treatment.

Fig. 3: Situation directly after debonding.

Fig. 4: Situation one week after debonding and infiltration of the teeth in the control group.

Fig. 5, 7, 9: Test teeth 11, 12, 22 before treatment.

Fig. 6, 8, 10: Test teeth 11, 12, 22 one week after treatment.

Fig. 11, 13, 15: Control teeth 13, 21, 23 before treatment.

Fig. 12, 14, 16: Control teeth 13, 21, 23 one week after treatment.

Key Learnings

Shorter time periods between debonding and infiltration seem to mask WSL more effectively.

Infiltration can be performed during orthodontic treatment and can arrest lesion progression at an earlier point in time.

References

1. Boersma JC, van der Veen MH, Lagerweij MD, Bokhout B, Prah Andersen B: Caries prevalence measured with QLF after treatment with fixed orthodontic appliances: influencing factors. *Caries Research* 2005;39:41-47.
2. Buchalla W: Histologisches und klinisches Erscheinungsbild der Karies; in Meyer-Lückel H, Paris S, Ekstrand KR (eds): *Karies: Wissenschaft und Klinische Praxis*. Thieme, 2012, pp 43-69.
3. Eckstein A, Helms HJ, Knösel M: Camouflage effects following resin infiltration of postorthodontic white-spot lesions in vivo: One-year follow-up. *Angle Orthodontist* 2015;85:374-380.
4. Feng C, Liu R, Liu R, Zhao Q, Chu X: [Effect of infiltration resin on the color masking of labial enamel white spot lesions]. *West China Journal of Stomatology* 2013;31:597-599.
5. Feng CH, Chu XY: [Efficacy of one year treatment of icon infiltration resin on post-orthodontic white spots]. *Journal of Peking University Health Sciences* 2013;45:40-43.
6. Hammad SM, El Banna M, El Zayat I, Mohsen MA: Effect of resin infiltration on white spot lesions after debonding orthodontic brackets. *American Journal of Dentistry* 2012;25:3-8.
7. Hellwig E, Klimek J, Attin T: Ätiologie, Histologie und Epidemiologie der Karies und anderer Zahnhartsubstanzdefekte; in Hellwig E, Klimek J, Attin T (eds): *Einführung in die Zahnerhaltung: Prüfungswissen Kariologie, Endodontologie und Parodontologie*. Deutscher Zahnärzte Verlag 2010, pp 15-76.
8. Kim S, Kim EY, Jeong TS, Kim JW: The evaluation of resin infiltration for masking labial enamel white spot lesions. *International Journal of Paediatric Dentistry* 2011;21:241-248.
9. Knösel M, Eckstein A, Helms HJ: Durability of esthetic improvement following Icon resin infiltration of multibracket-induced white spot lesions compared with no therapy over 6 months: a single-center, split-mouth, randomized clinical trial. *American Journal of Orthodontics and Dentofacial Orthopedics* : 2013;144:86-96.
10. Meyer-Lückel H, Paris S: Kariesinfiltration; in Meyer-Lückel H, Paris S, Ekstrand KR (eds): *Karies: Wissenschaft und Klinische Praxis*. Thieme, 2012, pp 271-283.
11. Neuhaus KW, Graf M, Lussi A, Katsaros C: Late infiltration of post-orthodontic white spot lesions. *Journal of Orofacial Orthopedics* 2010;71:442-447.
12. Øgaard B: White Spot Lesions During Orthodontic Treatment: Mechanisms and Fluoride Preventive Aspects. *Seminars in Orthodontics* 2008;14:183-193.
13. Ogodescu A, Ogodescu E, Talpos S, Zetu I: [Resin infiltration of white spot lesions during the fixed orthodontic appliance therapy]. *Revista medico-chirurgicala a Societati de Medici si Naturalisti din Iasi* 2011;115:1251-1257.
14. Paris S, Schwendicke F, Keltsch J, Dorfer C, Meyer-Lueckel H: Masking of white spot lesions by resin infiltration in vitro. *Journal of Dentistry* 2013;41 Suppl 5:e28-34.
15. Richter AE, Arruda AO, Peters MC, Sohn W: Incidence of caries lesions among patients treated with comprehensive orthodontics. *American Journal of Orthodontics and Dentofacial Orthopedics* : 2011;139:657-664.
16. Sander FM: Prophylaxe und Zahnpflege in der Kieferorthopädie; in Sander FG, Schwenzler N, Ehrenfeld M (eds): *Kieferorthopädie*. Georg Thieme Verlag, 2011, pp 44-57.
17. Shafi I: Fluoride varnish reduces white spot lesions during orthodontic treatment. *Evidence-based Dentistry* 2008;9:81.
18. Tufekci E, Dixon JS, Gunsolley JC, Lindauer SJ: Prevalence of white spot lesions during orthodontic treatment with fixed appliances. *The Angle Orthodontist* 2011;81:206-210.
19. Wierichs RJ, Kogel J, Lausch J, Esteves-Oliveira M, Meyer-Lueckel H: Effects of Self-Assembling Peptide P11-4, Fluorides, and Caries Infiltration on Artificial Enamel Caries Lesions in vitro. *Caries Research* 2017;51:451-459.

Resin Infiltration of (Icon DMG) Post Orthodontic White Spot Lesions.

Dr. Carla Cohn

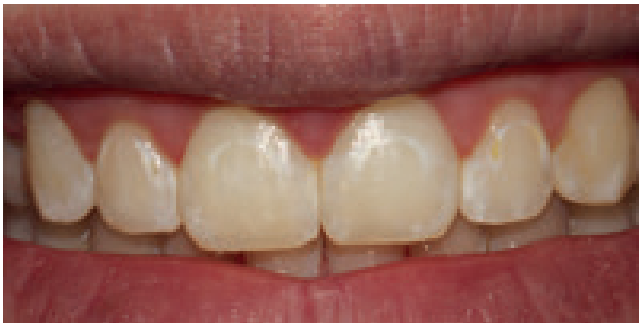


Fig. 1

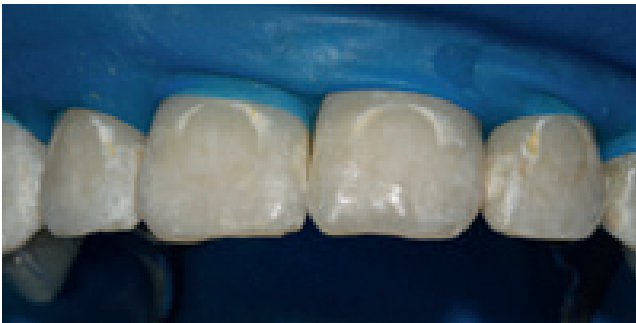

Fig. 2

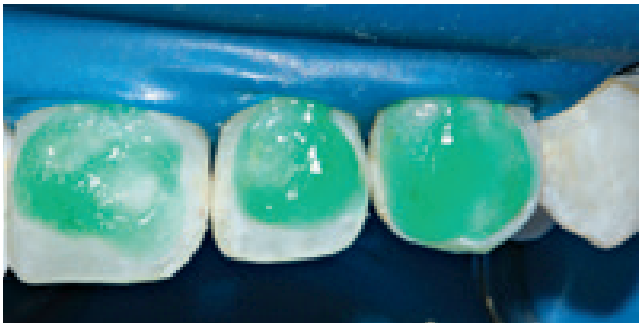

Fig. 3

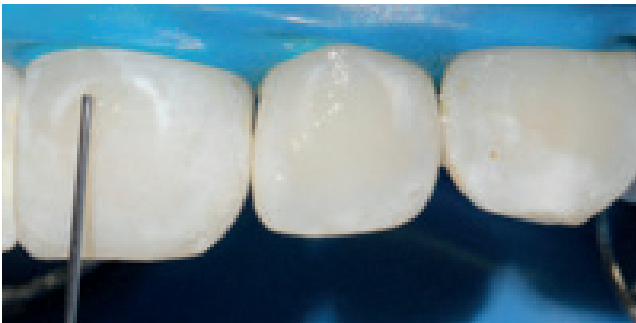

Fig. 4

Post-orthodontic decalcifications or »white spot lesions« are a significant aesthetic challenge. They have been reported at incidences as high as 73 % - 95 % [1, 2]. The prevalence of white spot lesions is so high due to several factors. Oral hygiene for patients with orthodontic appliances, bands and brackets is a challenge. Besides maneuvering around and cleaning between orthodontic hardware, it provides an increase in surface area for plaque and biofilm to accumulate. Add to this a teenaged patient, the most common recipient of orthodontic treatment, who may present with a lack of motivation to maintain oral hygiene and a high caries risk scenario ensues. White spot lesions can develop in as little as one month [3, 4, 5]. The lesions are often detected after debonding. Patients, parents, orthodontists and general dentists all have the same perception; that the appearance of white spot lesions is highly undesirable [6]. Studies show that resin infiltration (Icon DMG) proves to be most effective at masking white spot lesions [7] and more resistant to formation of new white spot lesions when compared to treatment with therapeutic fluoride solutions [8]. Furthermore the colour stability of caries infiltrated

teeth is durable [9, 10]. Case studies have been reported with excellent outcomes [11, 12]. In instances in which white spot lesions are treated during active orthodontic therapy, the question of bond strength to treated surfaces must be raised. It has been shown that resin infiltration of demineralized enamel does not affect the bond strength of orthodontic brackets [13].

Case Study

Post orthodontic white spot lesions treated with resin infiltration (Icon DMG).
Fig. 1: Pre-operative photograph.
Fig. 2: Dry field is essential for success. Rubber dam is placed to isolate the field and should be inverted, or ideally ligated, to prevent leakage or saliva contamination.
Fig. 3: Prophylaxis with non-fluoridated pumice is completed; teeth are rinsed, then dried. Icon-Etch (hydrochloric acid) is applied, extrude the Icon-Etch by twisting the syringe. Etch should extend approximately 2 mm around the edges of the lesion and be placed

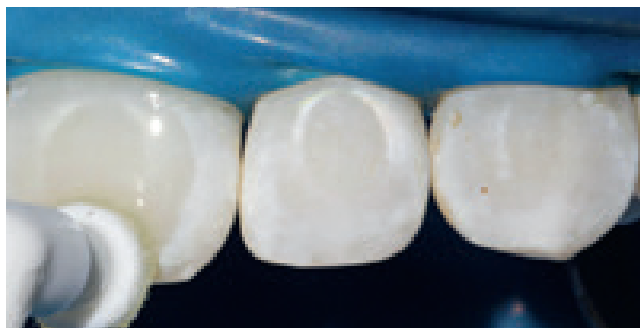

Fig. 5

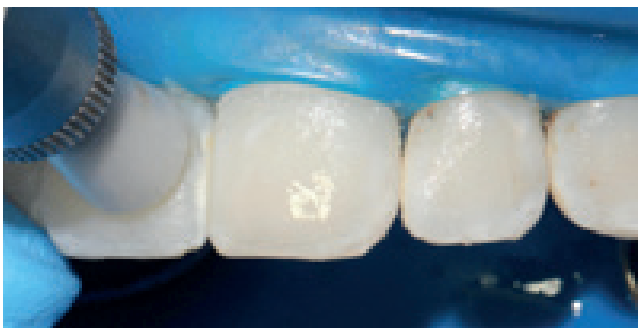

Fig. 6

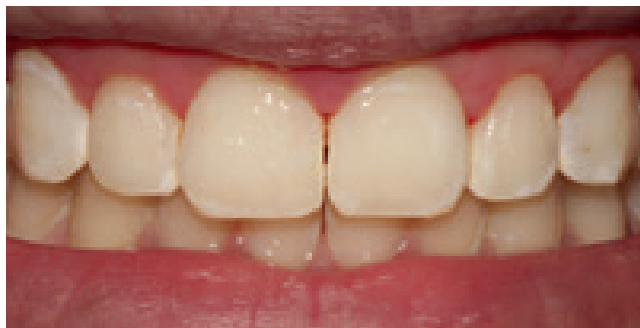

Fig. 7

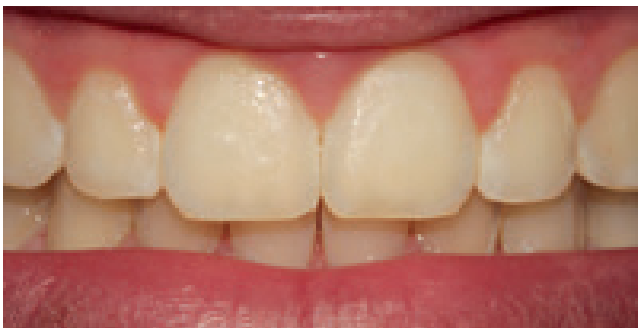

Fig. 8

for 2 minutes. Once in place the etch gel should be agitated with an instrument as it will buffer shortly after contact with the surface of the tooth. Etching process was repeated a second time for this case. For long standing white spot lesions the Icon-Etch step may be repeated.
Fig. 4: Rinse for 30 seconds and dry completely with oil free air. Application of Icon-Dry (99% ethanol) to the dried surface. Icon-Dry can indicate the final result after infiltration. Since the result was satisfactory, the ethanol was let on the surface for 30s to promote a thorough desiccation of the enamel, followed by air-drying.
Fig. 5: Application of Icon-Infiltrant by twisting the syringe. At this point remove direct overhead light source to avoid premature curing of the infiltrant. Continue »feeding« infiltrant to lesion for 3 minutes.
Fig. 6: Remove any excess material and light cure. Repeat the infiltration process with a new vestibular tip for 1 minute. Remove excess again and light cure. Final polish with Shofu OneGloss.
Fig. 7: Immediate post-operative photo.
Fig. 8: Recall post-operative photo (two months).

Conclusion


Micro-invasive treatment of post orthodontic white spot lesions can be completed in approximately 15 minutes chair time per tooth without mechanical removal of tooth structure or use of local anaesthetic. Excellent immediate post-operative results followed by long lasting beauty and stability.

Key Learnings

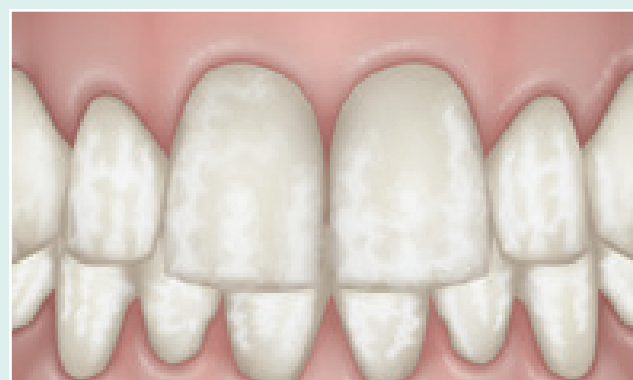- Recognize the aetiology and prevalence of post orthodontic decalcification/white spot lesions.
- Understand the success and effectiveness treatment of post orthodontic decalcification/white spot lesions with resin infiltration.
- Follow the clinical procedure of micro-invasive resin infiltration of smooth surface lesions.

References

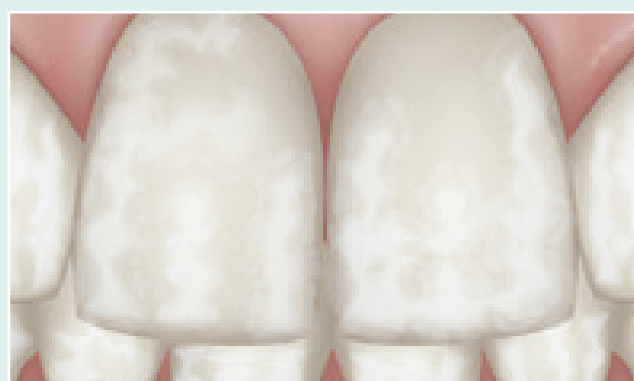- Richter AE, Arruda AO, Peters MC, And Sohn W. Incidence of caries lesions for patients treated with comprehensive orthodontics. J Dent Res 88 (Spec Iss A): Abstract Miami meeting 2009
- Lovrov S, Hertrich K, Hirschfelder U. Enamel demineralization during fixed orthodontic treatment - incidence and correlation to various oral hygiene parameters. J Orofac Orthop. 2007; 68: 353 - 63.
- Øgaard B, Rolla G, Arends J Orthodontic appliances and enamel demineralization Part 1 Lesion development Am J Orthod Dentofacial Orthop 1988; 94:68 - 73.
- O'Reilly MM Featherstone JDB Demineralization and remineralization around orthodontic appliances: An in vivo study. Am J Orthod Dentofacial Orthop 1987; 92: 33 - 40.
- Gorton J, Featherstone JDB, In vivo inhibition of demineralization around orthodontic brackets Am J Orthod Dentofacial Orthop 2003; 123: 10 - 14.
- Maxfield B, Hamdan A, Tufekci E, Shroff B, Best A, Lindauer S, Development of white spot lesions during orthodontic treatment: Perceptions of patients, parents, orthodontists, and general dentists, Am Journal of Orthod and Dentofac Orthop March 2012; 141, 3, 337 - 343.
- Kim S, Shin JH, Kim EY, Lee SY, Yoo SC. The evaluation of resin infiltration for masking labial enamel white spot lesions. Caries Res 44: 171-248, Abs. 47, (2010).
- Rocha Gomes Torres C, Marcondes Sarmiento Torres L, Silva Gomes I, Simões de Oliveira R, Bühler Borges A. Effect of caries infiltration technique and fluoride therapy on the color masking of white spot lesions. 2010, Data on file. DMG, Hamburg, Germany.
- Luebbbers D, Spieler-Husfeld K, Staude C. In vitro color stability of infiltrated carious lesions. 2009, Data on file. DMG, Hamburg, Germany.
- Phark JH, Duarte S. Clinical performance and color stability of infiltrated smooth surface lesions. 2010, Data on file. DMG, Hamburg, Germany.
- Shivanna V, Shivakumar B. Novel treatment of white spot lesions: A report of two cases. J Conserv Dent 2011;14:423-6.
- Glazer H, Treating White Spots: New Caries Infiltration Technique, Dentistry Today October 2009; Vol 28, No 10.
- Phark JH, Choo KM, Duarte S, Sadan A. Influences on Bond Strength of Orthodontic Brackets. J Dent Res 89 (Spec Iss A): 1320 (2010).



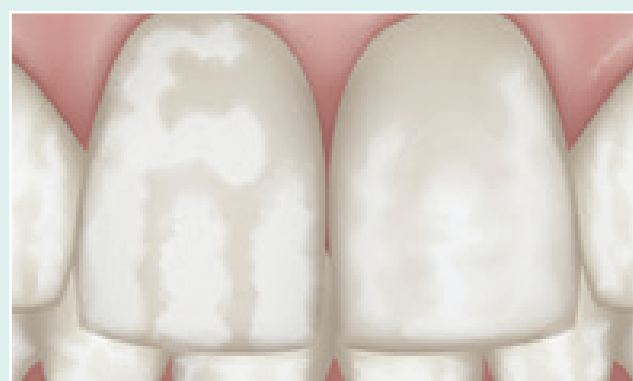Patient history or etiology. Ingestion of excessive fluoride during enamel formation.



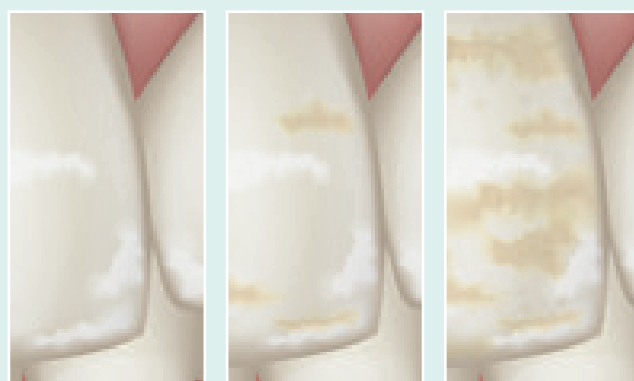
Affected tooth/teeth. A varying number of teeth. Bilateral, symmetrical developmental enamel opacities.



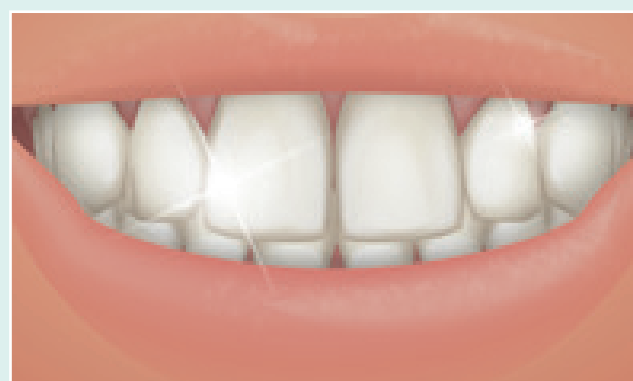
Localization. Whole enamel surfaces can be affected, depending on the severity.



Border. Irregular, distinct or diffuse opacities.



Color. From tiny white specks or streaks to dark brown stains and rough, pitted enamel, depending on the severity.



Other unaffected teeth. Smooth and glossy. They should also be a pale creamy white.

Fluorosis - mild, moderate or severe.

Dental history and visual diagnosis.

Fluoride has an important and determinant role in dental caries prevention. However, excess and constant exposure to this chemical element during enamel formation may result in fluorosis, and its severity is directly related to the amount of fluoride which the patient contacted during enamel formation/maturation. [1,3]

Clinically, mild dental fluorosis is characterized by a diffuse whitish opaque appearance caused by a porous/hypomineralized subsurface enamel with an intact surface layer. In cases in which higher concentrations or prolonged fluoride exposure occurred, moderate and more severe fluorosis present a clinical aspect ranging from more extensive and opaque whitish or brownish stained enamel to pitted enamel lesions that occur pre- or post-eruptively due to deeper defects in enamel formation/mineralization. [1,6]

Of all permanent teeth, the anterior teeth are more likely to be affected by fluorosis, since the period of development and maturation of these teeth coincides with the beginning of exposure to fluoride during the second and third year of life. [1,3]

The alteration in esthetic perception caused by fluorosis, according to its severity, can generate frustration, embarrassment and

concern when smiling, as well as potential impact in quality of life of adults and children. [4,6] More recently, resin infiltration has emerged as a viable alternative for esthetic treatment of lesions classified as mild to moderate. [2,5,7]

In milder fluorosis, the shallower subsurface porosities are usually adequately infiltrated and the esthetic results commonly pleasant. In moderate or severe fluorosis, an initial mechanical wear of the surface of the affected enamel might be required before resin infiltration, that is followed by increments of composite resins, as illustrated in some clinical cases presented in this book.

Prof. Dr. Leandro Augusto Hilgert

References

1. Aoba, T., & Fejerskov, O. (2002). Dental fluorosis: Chemistry and biology. *Critical Reviews in Oral Biology and Medicine*, 13(2), 155–170.
2. Auschill, T. M., Schmidt, K. E., & Arweiler, N. B. (2015). Resin Infiltration for Aesthetic Improvement of Mild to Moderate Fluorosis: A Six-month Follow-up Case Report. *Oral Health & Preventive Dentistry*, 13(4), 317–322.
3. Denbesten, P., & Li, W. (2011). Chronic fluoride toxicity: dental fluorosis. *Monographs in Oral Science*, 22, 81–96.
4. Do, L. G., & Spencer, A. (2007). Oral Health-Related Quality of Life of Children by Dental Caries and Fluorosis Experience. *Journal of Public Health Dentistry*, 67(3), 132–139.
5. Gughani, N., Pandit, I. K., Gupta, M., Gughani, S., Soni, S., & Goyal, V. (2017). Comparative evaluation of esthetic changes in nonpitted fluorosis stains when treated with resin infiltration, in-office bleaching, and combination therapies. *Journal of Esthetic and Restorative Dentistry*, 29(5), 317–324.
6. Martínez-Mier, E. A., Maupomé, G., Soto-Rojas, A. E., Ureña-Cirett, J. L., Katz, B. P., & Stookey, G. K. (2004). Development of a questionnaire to measure perceptions of, and concerns derived from, dental fluorosis. *Community Dental Health*, 21(4), 299–305.
7. Muñoz, M. A., Arana-Gordillo, L. A., Gomes, G. M., Gomes, O. M., Bombarda, N. H. C., Reis, A., & Loguercio, A. D. (2013). Alternative esthetic management of fluorosis and hypoplasia stains: Blending effect obtained with resin infiltration techniques. *Journal of Esthetic and Restorative Dentistry*, 25(1), 32–39.

Effective and predictable masking of mild to moderate fluorosis with in-office bleaching prior to resin infiltration.

PD. Dr. Michael Wicht, Christoph Schoppmeier

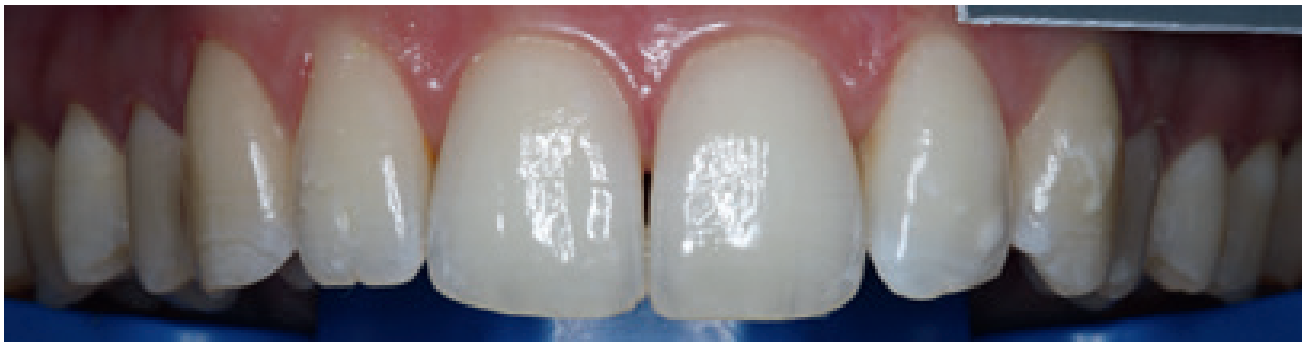

Fig. 1: Base status. Case 1.

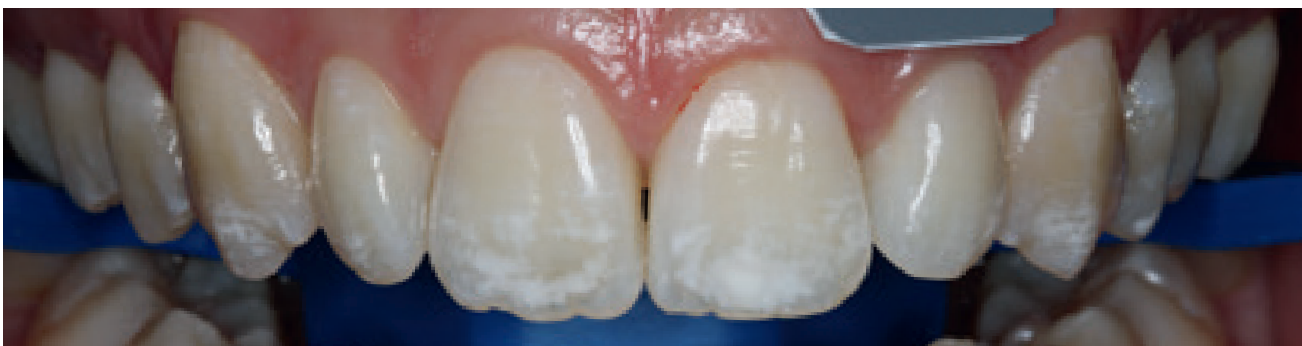

Fig. 2: Base status. Case 2.

The prevalence of dental fluorosis varies significantly among different countries depending on the level of water fluoridation and the use of fluoridated products in patients' early childhood. In Germany the prevalence is estimated around 10-15 % [3] with most of the alterations being mild to moderate expressed as whitish opacities either localised or widely spread over the enamel surface. Recently, no strong evidence regarding the masking effect of whitish discoloration with resin infiltration was reported in a systematic review disregarding the origin of the alteration [2]. However, case reports [1, 7] and excellent clinical results achieved in our dental school support the theory that resin infiltration is a treatment alternative to direct and indirect composite or ceramic restorations. In-office or home bleaching with hydrogen or carbamide peroxide has also been reported to improve the overall aesthetic appearance of very mild and mild fluorosis yielding a more homogeneous colour [6]. Other approaches comprise micro-abrasion and the use of sodium hypochlorite in particular in discoloured teeth [4].

According to Perdigao [5] the combination of both, at home bleaching and subsequent resin infiltration led to impeccable clinical results in masking enamel fluorosis discolorations. Based on positive results mostly published in case reports we hypothesised that in-office bleaching prior to resin infiltration improves the quantifiable and self-assessed aesthetic effect in mild to moderate dental fluorosis. 26 patients were included in a RCT. The test group received an in-office light enhanced power bleaching with 25 % hydrogen peroxide (Zoom, Philips, NL); the control group was pre-treated accordingly using an ACP gel (Relief Oral Care Gel, Philips, NL) instead of the active substance. After two weeks both groups were infiltrated (Icon, DMG, Germany). Digital images were taken at every appointment and after 1, 3 and 6 months respectively. Based on calibrated images Delta E-values between health enamel surface and fluorosis Spots were calculated. Additionally patients' were asked as to how they judge their overall appearance on a VAS (1-10).

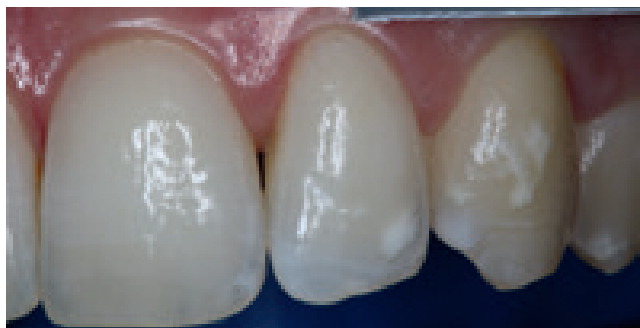

Fig. 3

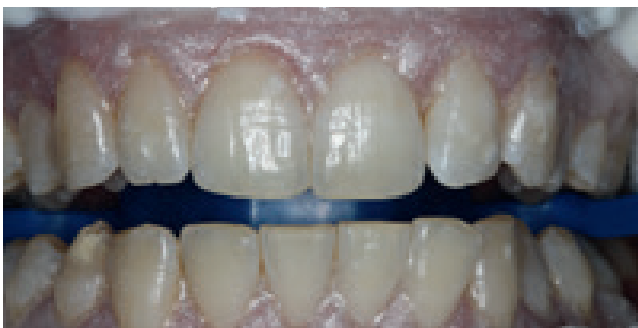

Fig. 4

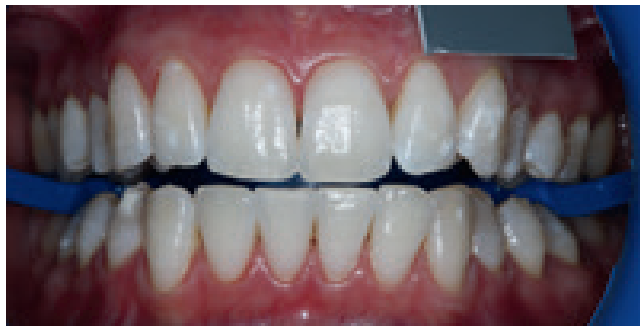


Fig. 5

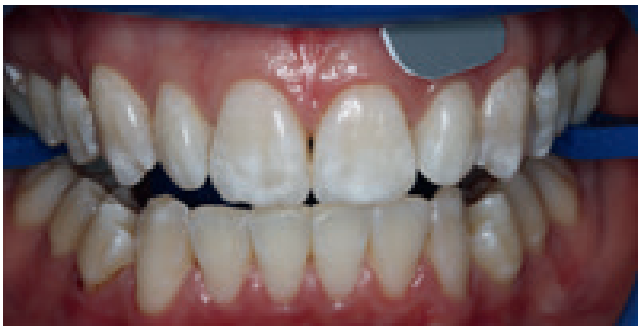

Fig. 6

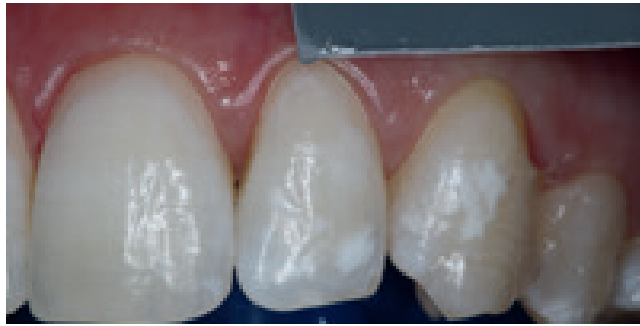

Fig. 7

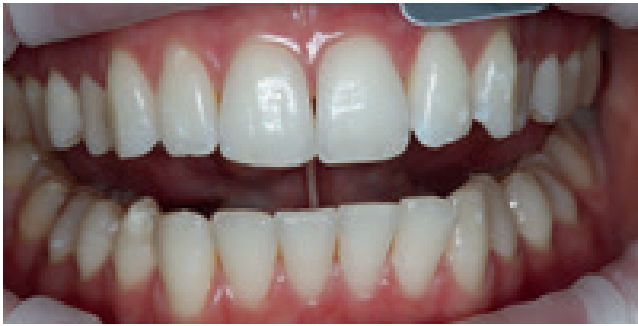

Fig. 8

Statistical analyses (mixed linear model) revealed that resin infiltration alone leads to a significant masking of discoloured enamel opacities most likely connected with dental fluorosis. In office bleaching with 25 % H₂O₂ following Icon infiltration treatment significantly improves Delta E values and the self estimated appearance after 6 months. The following two clinical cases visualise the treatment protocol and clinical results up to 6 months follow-up.

Cases

Two female patients (24 and 27 yrs.) exhibiting mild (case 1) and moderate (case 2) dental fluorosis particularly on their upper front teeth. Both patients applied for inclusion in the above-mentioned clinical trial and were proven to meet the inclusion criteria.

Fig. 3: Close up case one 21-23. Marked opacities in the incisal region become more pronounced after desiccation.

Fig. 4: In-office bleaching (case one). Patients were prepared for in-office bleaching using the Zoom kit (Philips, NL). Liquid dam is thoroughly applied along the gingival margin in both, the bleaching and infiltration procedure. Every patient in the test group received 3 cycles of light enhanced power bleaching each cycle lasting for 15 minutes.

Fig. 5 and 6: Bleaching results. After bleaching teeth are obviously brighter in both cases. Patients preferred that bleached look, however Delta E-values do not decrease significantly. These patient-centered findings are not in line with our personal observations. It appears that not only the sound but also the fluorotic enamel appears brighter after bleaching leading to an overall lighter appearance than the baseline status.

Fig. 7: Close up case one 21-23. After bleaching the teeth appear brighter including the discoloured areas. The contrast is not levelled out but rather more pronounced most probably enhanced by desiccation directly after treatment.

Fig. 8: Case 1 before infiltration. After in-office bleaching we waited for 2 weeks before the infiltration procedure. After rehydration the teeth appear more uniform yet brighter in colour. The treatment protocol intended application of hydrochloric acid for 6 minutes (three rounds, 2 minutes each) and 10 minutes of infiltration and one additional minute after the initial infiltrating procedure. The prolonged etching and infiltration increases the probability to sufficiently remove the intact surface layer and allows the infiltrant to homogeneously fill up deeper porosities. Apart from these modifications the infiltration process was performed as recommended by the manufacturer.

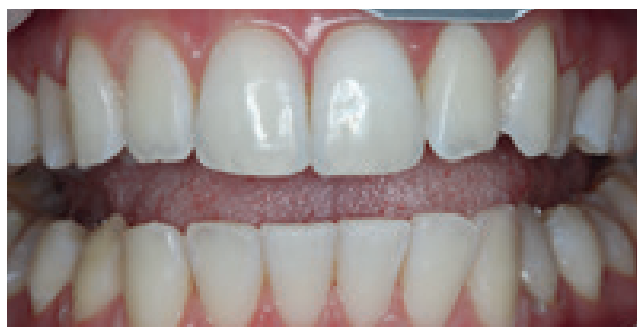

Fig. 9

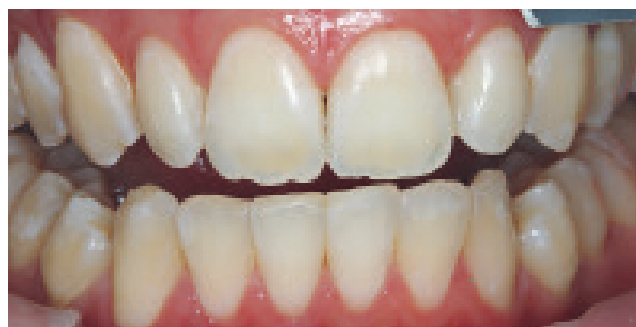

Fig. 10

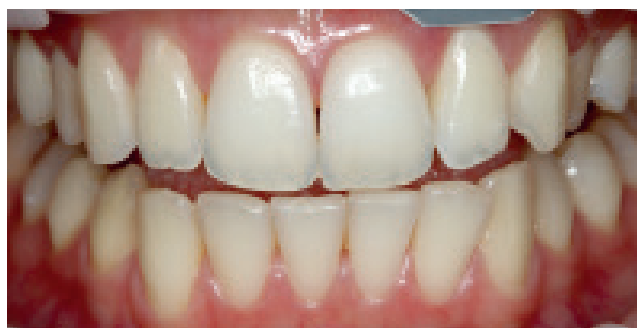

Fig. 11

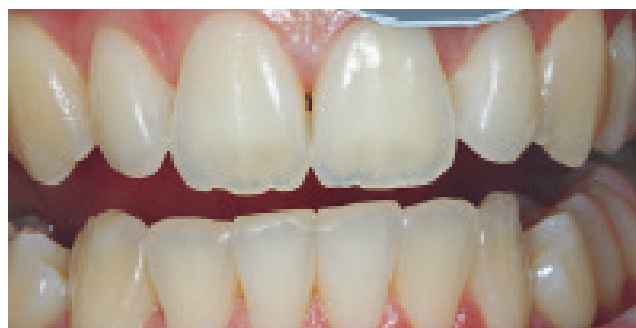

Fig. 12

Fig. 9 and 10: Results immediately after infiltration.

In both cases the masking was almost complete with a more or less homogeneous colour. As a side effect teeth may tend to appear yellowish directly after treatment. On the one hand this phenomenon is ascribed to the photo initiator camphor quinone used in the product on the other hand white opacities that gave the affected teeth a whiter look will obviously and intentionally disappear. It is advisable to inform patients about this likely effect beforehand. We observed a tendency towards remission of this effect during the observation period.

Fig. 11 and 12: Highly satisfied patients with almost complete masking of the fluorotic enamel.

In general, patients in both groups appreciated the infiltration as a non to micro-invasive treatment option. The combination of in-office bleaching and infiltration at a later time led to superior results regarding Delta-E and self-estimated VAS values. Interestingly, both outcomes correlate significantly indicating that objectively measured parameters are in line with a patient-centred outcome.

Key Learnings

- Patients who feel impaired by mild to moderate fluorosis have many treatment options to choose from. With direct composite restorations or veneers on the rather invasive and the latter definitely on the costlier side, resin infiltration is comparably little invasive and less expensive.
- Infiltrating fluorotic teeth is a predictable and efficient treatment option, however prolonged hydrochloric etching and infiltration time may be advantageous.
- Bleaching combined with infiltration significantly enhances the masking effect as indicated by the improved Delta-E values and patients' satisfaction.

References

- Auschill, T. M., Schmidt, K. E., Arweiler, N. B.: Resin Infiltration for Aesthetic Improvement of Mild to Moderate Fluorosis: A Six-month Follow-up Case Report. *Oral Health Prev Dent* 13, 317-322 (2015)
- Borges, A. B., Caneppele, T. M., Masterson, D., Maia, L. C.: Is resin infiltration an effective esthetic treatment for enamel development defects and white spot lesions? A systematic review. *J Dent* 56, 11-18 (2017)
- Momeni, A., Neuhauser, A., Renner, N., Heinzel-Gutenbrunner, M., Abou-Fidah, J., Rasch, K., Kroplin, M., Fejerskov, O., Pieper, K.: Prevalence of dental fluorosis in German schoolchildren in areas with different preventive programmes. *Caries Res* 41, 437-444 (2007)
- Penumatsa, N. V., Sharanesh, R. B.: Bleaching of fluorosis stains using sodium hypochlorite. *J Pharm Bioallied Sci* 7, S766-768 (2015)
- Perdigao, J., Lam, V. Q., Burseth, B. G., Real, C.: Masking of Enamel Fluorosis Discolorations and Tooth Misalignment With a Combination of At-Home Whitening, Resin Infiltration, and Direct Composite Restorations. *Oper Dent* 42, 347-356 (2017)
- Shanbhag, R., Veena, R., Nanjannawar, G., Patil, J., Hugar, S., Vagrati, H.: Use of clinical bleaching with 35% hydrogen peroxide in esthetic improvement of fluorotic human incisors in vivo. *J Contemp Dent Pract* 14, 208-216 (2013)
- Wang, Y., Sa, Y., Liang, S., Jiang, T.: Minimally invasive treatment for esthetic management of severe dental fluorosis: a case report. *Oper Dent* 38, 358-362 (2013)

Icon resin infiltration.

Gabriela Caldeira Andrade Americano, Prof. Dr. Vera Mendes Soviero

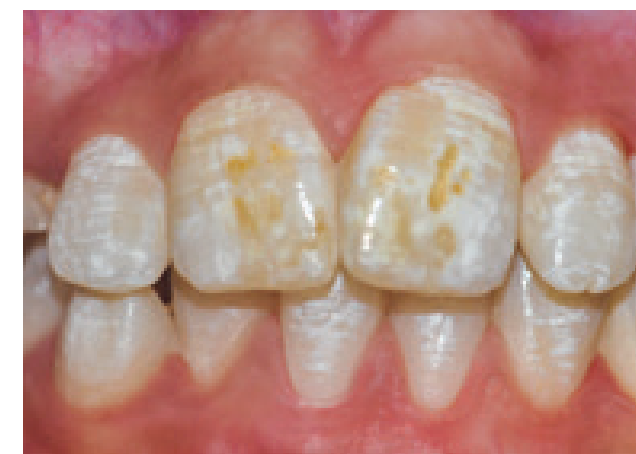
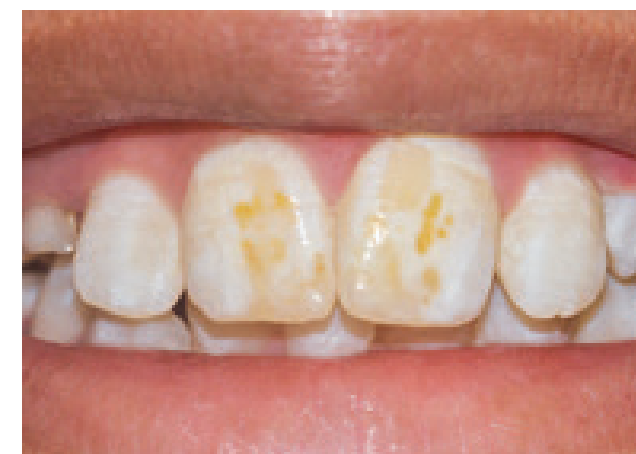
Fig. 1-2: Through a clinical exam, it was diagnosed that all of permanent anterior teeth, which were erupted, had fluorosis. However, the teeth 11 and 21 were more severely affected according to Thylstrup and Fejerskov index [12].

Abstract

Aesthetic problems due to Fluorosis can occur in children and adolescents. The aim was to describe a case report about the use of infiltrant resin to mask diffuse opacities. A male patient aged 12 years attended the Paediatric Dentistry clinic of the Rio de Janeiro State University, Rio de Janeiro, Brazil. Through a clinical exam, it was diagnosed that incisors had fluorosis. The teeth 12, 11, 21 and 22 were treated with infiltrant resin (Icon, DMG, Hamburg, Germany). All procedures were done in accordance with manufacturer instructions. Furthermore, Icon-Etch and Icon-Dry were applied three times in order to enhance the masking of the defects. The immediate result as well as 1 week and 4 months after the treatment were satisfactory. The use of infiltrant resin (Icon) can mask diffuse opacities improving the esthetics without a significant loss of tooth tissue.

Introduction

Aesthetic problems due to enamel developmental defects can occur in children and adolescents. Fluorosis is a defect of enamel mineralization, characterized by porosity of the enamel subsurface [1]. Clinically, fluorosis can be seen as slight accentuation of the perikymata, diffused opacities with a opaque white appearance or chalky white enamel with some yellow to brown staining and pitting [2]. There are several treatment options for aesthetic problems due to fluorosis, such as bleaching, microabrasion and restorative techniques. Bleaching therapy has been reported by being able to mask the blemishes and providing a more uniform appearance [3,4]. Microabrasion works well for shallow defects, but it can result in some reduction of enamel [5, 6.] Treatment with resin composites can correct or improve enamel imperfections [7], however this

procedure also ends up in a loss of tooth tissue. Infiltrant resin has masked white spot lesions [8, 9], because this resin has a refractive index similar to apatite crystals. Thereby, light refraction and, consequently, the colour differences of enamel are reduced [10]. As the fluorotic enamel is porous [11], the same as the white spot lesions, the resin infiltration can be a good alternative to mask the opacities. Thus, this paper aimed to describe a case report about the use of infiltrant resin (Icon, DMG, Hamburg, Germany) to mask diffuse opacities in permanent anterior teeth.

Case Report

The patient male, 12 years old, has been assisted at the Paediatric Dentistry clinic of the Rio de Janeiro State University, Rio de Janeiro, Brazil.

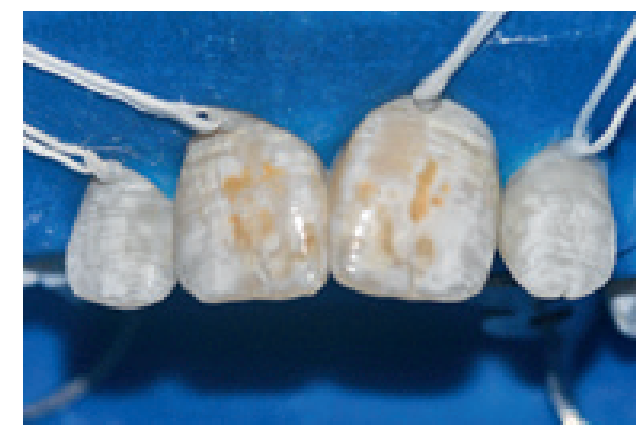

Fig. 3: Before the treatment with Icon, the teeth 12, 11, 21 and 22 were cleaned and a rubber dam was placed.

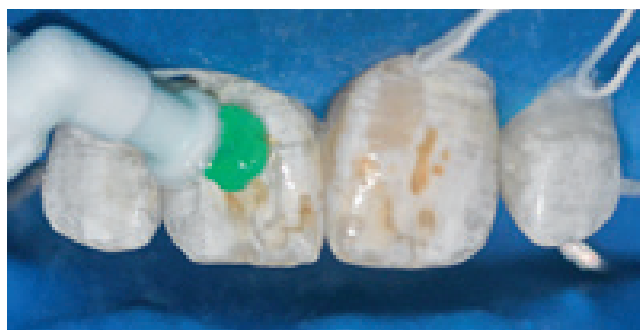

Fig. 4

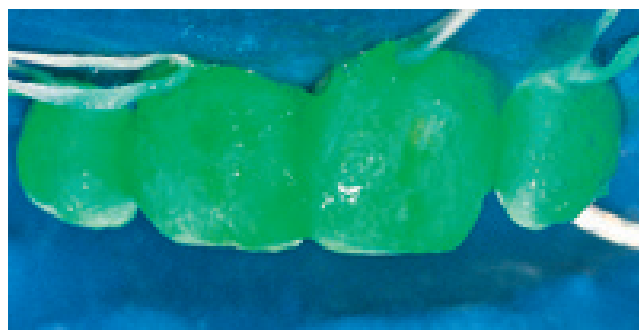


Fig. 5

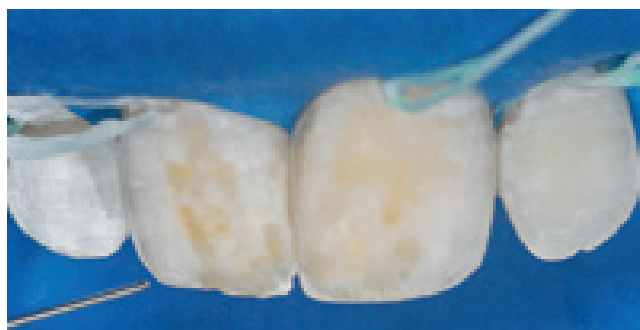

Fig. 6

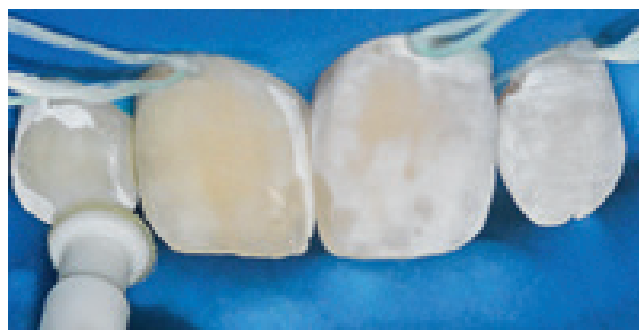

Fig. 7

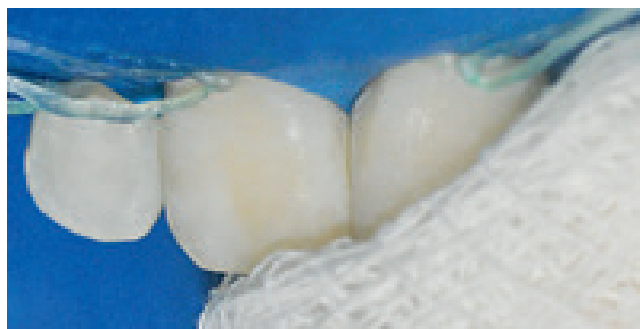

Fig. 8

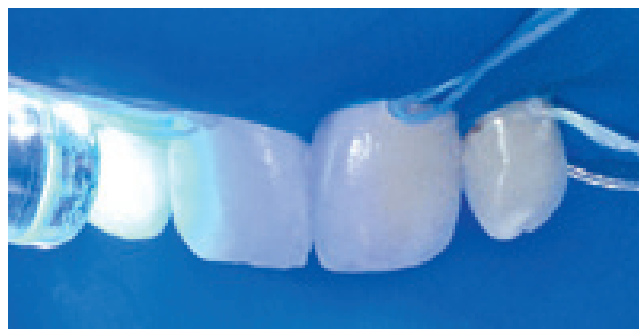

Fig. 9

Fig. 4-5: Icon-Etch was applied on the buccal surfaces of the upper incisors for 2 minutes. Fig. 6: Once the teeth were rinsed for 30 seconds and air-dried, Icon-Dry was used for 30 seconds. After the first acid-etching, part of the white diffuse opacities seemed masked when Icon-Dry was applied, but not the yellowish ones. Fig. 7: A second application of Icon-Etch was done for 2 minutes, followed by dry air and Icon-Dry. However, the yellowish opacities were still visible. Hence, a third application of Icon-Etch was done for 2 minutes. This time a gentle friction was done using Icon-Etch applicator on the yellowish areas. Finally, the yellowish opacities seemed masked when they were wetted by Icon-Dry. Fig. 8: All the surfaces were dried again, and Icon-Infiltrant was applied. The excess material was removed with gauzes. Fig. 9: First the infiltrant set for 3 minutes and then light-curing each tooth for 40 seconds.

Discussion

Whenever an aesthetic procedure is recommended, it should be based on patient's demand. Aesthetic perception is very much subjective and individual. An enamel defect can be an aesthetic problem for dentists, but not for patients. Furthermore, it can be argued that girls may be more concerned with their appearance than boys [6]. In the present case, the patient was a boy and felt really upset about the appearance of his teeth. Thus, the decision to treat the upper incisors aesthetically came from the patient's wish to have non-discolored teeth. Thereby, as the infiltrant resin has masked white spot lesions [8, 9], it was decided to use the Icon to mask the diffuse opacities. The colour difference of enamel between white spot lesions and sound enamel occurs because the refractive indices of enamel, water and air are different [9]. If lesion pores are filled with water or air, in other words, if lesions are wet or dried, they will appear opaque, because the refractive indices of water and air

are smaller than the enamel refractive index. When pores are filled with infiltrant resin, lesions are masked because the refractive indices of sound enamel and infiltrant are similar [9, 13]. As fluorotic enamel has a porous subsurface in the enamel below a well-mineralized surface [11] similar to white spot lesions, the infiltrant can behave in the same way as in white spot lesions. Diffuse opacities were well masked by the infiltrant in this clinical case. The application of Icon-Etch for three times was necessary to achieve a complete erosion of the surface layer allowing the infiltrant to penetrate as it happens in caries lesions [8, 14]. Compliance with manufacturer instructions on how to use the material may have contributed for the treatment success, for instance, the polishing of tooth surfaces. The polishing of treated areas enhances the colour stability of the masking probably due to reduction of the roughness. Clinical conditions, such as type of opacity and infiltration depth,

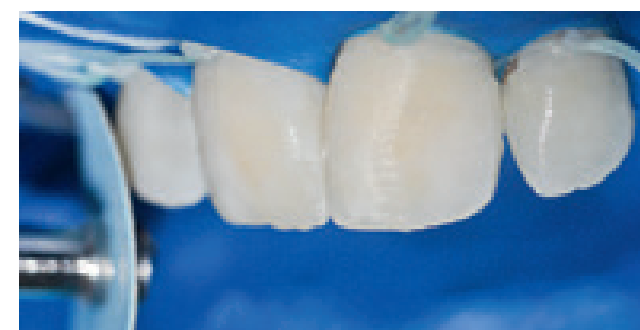

Fig. 10

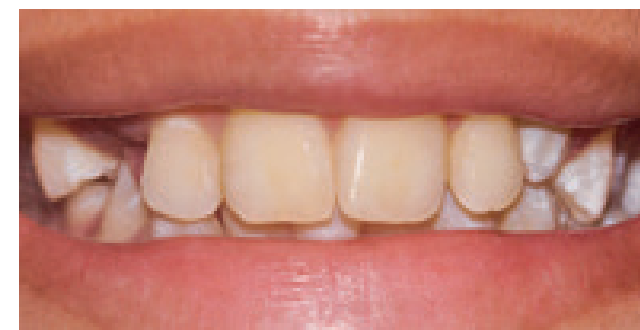

Fig. 11: The final aspects one week after the treatment.

Fig. 10: According to manufacturer instructions, the application of Icon-Infiltrant was repeated for 1 minute. To finalize the treatment, the tooth surfaces were polished with composite resin polishing discs.

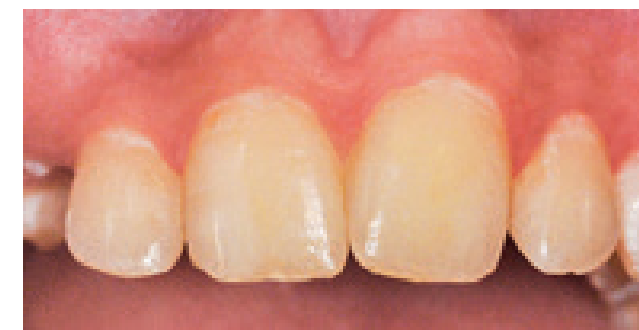

Fig. 12: Follow-up of 4 months. The guardians signed an informed consent form regarding all the procedures.

complete or incomplete infiltration, polymerization shrinkage as well as resin colour, can also interfere in the final result [10]. In this case, the rubber dam hampered Icon to set in the gingival margin. Nonetheless, even with slight blemishes in the gingival margin of the upper incisors, the patient was very satisfied with the treatment. Icon-Infiltrant has a lot advantages over other treatment techniques. The infiltrant can mask deeper lesions [9] without a significant loss of tooth tissue, which the microabrasion [5, 6] and restorations with resin composites are not able to do. Moreover, a resin layer is not necessary, once the material penetrates into the enamel [9]. The removal of the excess material with gauzes also retains the surface shape [15]. In contrast to the bleaching therapy, which can reduce the microhardness of demineralized enamel surfaces [16], the infiltrant resin can strengthen the enamel structure mechanically [17].

Conclusion

The use of Icon-Infiltrant can mask diffuse opacities improving the esthetics without a significant loss of tooth tissue.

Key Learnings

- The polishing of treated areas enhances the colour stability of the masking probably due to reduction of the roughness.
- In contrast to the bleaching therapy, which can reduce the microhardness of demineralized enamel surfaces [16], the infiltrant resin can strengthen the enamel structure mechanically [17].
- The use of infiltrant resin (Icon) can mask diffuse opacities improving the esthetics without a significant loss of tooth tissue.

References

- Fejerskov O, Johnson NW, Silverstone LM. The ultrastructure of fluorosed human dental enamel. *Scand J Dent Res*. 1974;82:357-72.
- Møller IJ. Fluorides and dental fluorosis. *Int Dent J*. 1982;32(2):135-47.
- Wright JT. The etch-bleach-seal technique for managing stained enamel defects in young permanent incisors. *Pediatr Dent* 2002;24:249-52.
- Bussadori SK, do Rego MA, da Silva PE, Pinto MM, Pinto AC. Esthetic alternative for fluorosis blemishes with the usage of a dual bleaching system based on hydrogen peroxide at 35%. *J Clin Pediatr Dent* 2004;28:143-6.
- Dalzell DP, Howes RI, Hubler PM. Microabrasion: effect of time, number of applications, and pressure on enamel loss. *Pediatr Dent* 1995;17:207-11.
- Wong FS, Winter GB. Effectiveness of microabrasion technique for improvement of dental aesthetics. *Br Dent J* 2002;193:55-8.
- Dietschi D. Optimizing smile composition and esthetics with resin composites and other conservative esthetic procedures. *Eur J Esthet Dent* 2008;3:14-29.
- Paris S, Meyer-Lueckel H. Masking of labial enamel white spot lesions by resin infiltration – a clinical report. *Quintessence Int* 2009;40:713-8.
- Kim S, Kim EY, Jeong TS, Kim JW. The evaluation of resin infiltration for masking labial enamel white spot lesions. *Int J Paediatr Dent* 2011;21:241-8.
- Paris S, Schwendicke F, Keltsch J, Dörfer C, Meyer-Lueckel H. Masking of white spot lesions by resin infiltration in vitro. *J Dent* 2013;41:28-34.
- Newbrun E, Brudevold F. Studies on the physical properties of fluorosed enamel I. Microradiographic studies. *Arch Oral Biol* 1960;2:15-20.
- Thylstrup A, Fejerskov O. Clinical appearance of dental fluorosis in permanent teeth in relation to histological changes. *Community Dent Oral Epidemiol*. 1978;6:329-37.
- Hosey MT, Deery C, Waterhouse PJ. *Paediatric Cariology*. London: Quintessence Essentials 2004.
- Knösel M, Eckstein A, Helms HJ. Durability of esthetic improvement following Icon resin infiltration of multibracket-induced White spot lesions compared with no therapy over 6 months: A single-center, split-mouth, randomized clinical trial. *Am J Orthod Dentofacial Orthop* 2013;144:86-96.
- Mueller J, Meyer-Lueckel H, Paris S, Hopfenmuller W, Kielbassa AM. Inhibition of lesion progression by the penetration of resins in vitro: influence of the application procedure. *Oper Dent* 2006;31:338-45.
- Basting RT, Rodrigues Júnior AL, Serra MC. The effect of 10% carbamide peroxide bleaching material on microhardness of sound and demineralized enamel and dentin in situ. *Oper Dent* 2001;26:531-9.
- Robinson C, Brookes SJ, Kirkham J, Wood SR, Shore RC. In vitro studies of the penetration of adhesive resins into artificial caries-like lesions. *Caries Res* 2001;35:136-41.
- Meyer-Lueckel H, Paris S. Improved resin infiltration of natural caries lesions. *J Dent Res* 2008;87:1112-6.

Association of resin infiltration and composite resin on the treatment of severe dental fluorosis.

Prof. Dr. Leandro Augusto Hilgert, Marília Bizinoto Silva Duarte

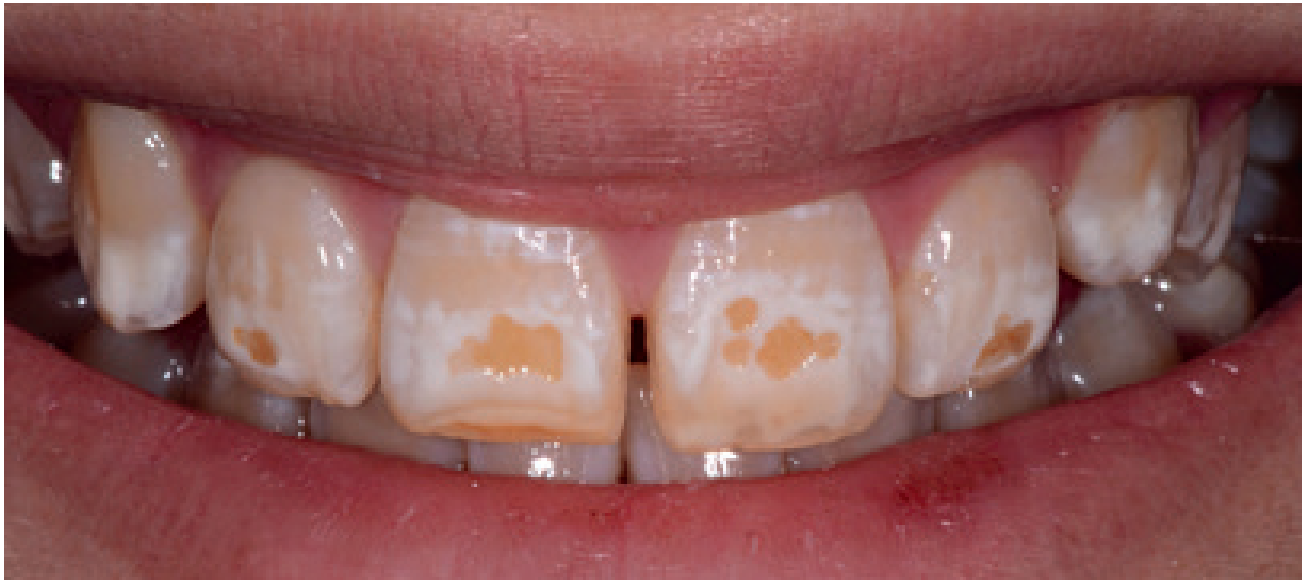

Fig.1: Base status.

Enamel developmental defects may negatively affect esthetics and patients' self-esteem [1]. This is particularly true for young patients. For these cases, treatments should be able to present an acceptable esthetic result without compromising much tooth structure (being minimally invasive). Resin infiltration has been shown to be a microinvasive treatment for white spot lesions, slight to moderate fluorosis and some other types of opacities [2, 3]. However, in more severe cases, in which tooth substance loss is already present and/or opacities are too opaque and deep, a combination of resin infiltration and composite resins may be an effective, fast and minimally invasive approach to improve esthetics («deep infiltration») [4]. Fluorosis is characterized by hypomineralization of the enamel [5]. In less severe cases the subsurface hypomineralized enamel may be resin infiltrated only in a true microinvasive treatment approach. The aim of this case report is to present a severe case of fluorosis in which due to enamel loss and deep opacities an association of resin infiltration and composite resin restorations was used on the treatment a young patient.

Case report
A young female patient presenting a severe case of fluorosis reached the University clinic seeking for esthetic treatment. During anamnesis it was revealed that the child was shy and afraid of smiling, and episodes of bullying at school have already happened due to the enamel development defects. However, there was a concern by the child and her mother on the possible complexity, costs and invasiveness of the necessary treatment approach. Intra oral examination showed a fluorosis graded as TF6, presenting regions of white opacities as well as some enamel pitting with substantial amount of enamel loss. Transillumination suggested areas of deeper hypomineralization (where light transmittance was blocked) as well as some areas with more shallow lesions. Proposed treatment plan was resin infiltration and small additions of composite resin. Patient and mother were explained on the treatment steps and the possible need for some localized wear of the enamel on the regions that already presented enamel pitting and discoloration and on the areas with deeper opacities.

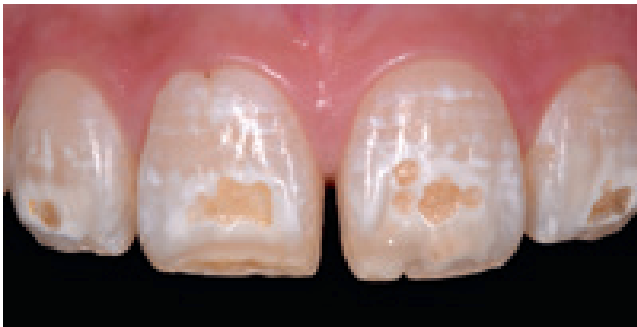

Fig. 2

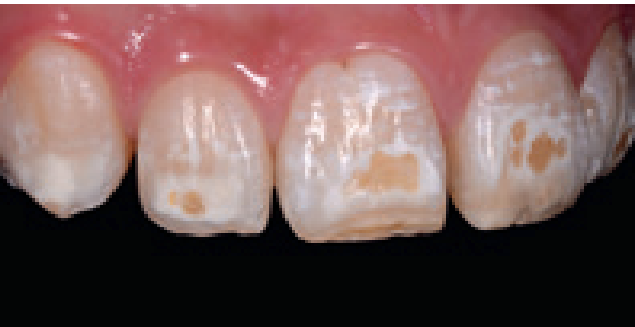

Fig. 3

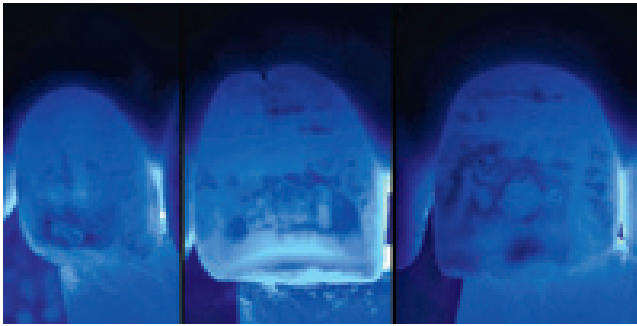


Fig. 4

Fig. 1-4: Figures 1, 2 and 3 present different views of the clinical case in which the patient presents fluorosis (TF6). Observe that there are areas with diffuse and slight white opacities, areas with very opaque white opacities and areas that already present enamel loss and some discoloration. In Figure 4 transillumination was performed to check light transmittance through the enamel, that may be a useful diagnostic tool since the deeper the enamel hypomineralization, the more light is blocked. Some areas of the affected anterior teeth area were suggested to present deeper lesions, that may impair a more complete resin infiltration without some previous wear of the enamel.

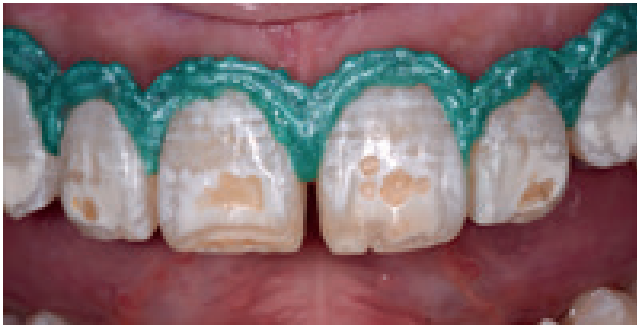


Fig. 5

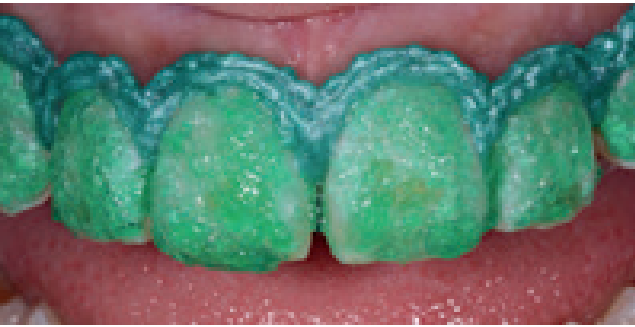

Fig. 6

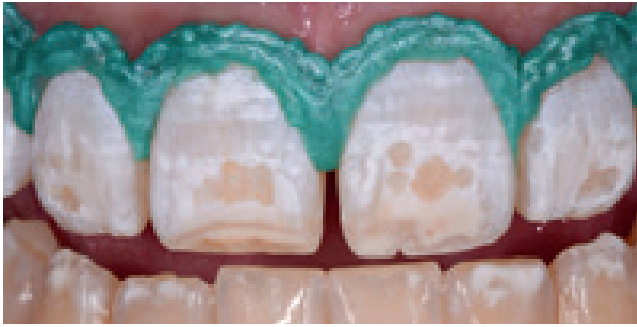

Fig. 7

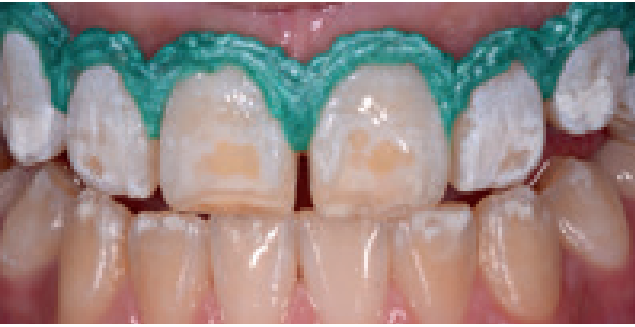

Fig. 8

Fig. 5-8: After isolation of the operatory field using lip retractors and a liquid dam to protect soft tissues (Fig. 5), Icon-Etch (hydrochloric acid) was applied on the surfaces for 2 mins (Fig. 6) aiming to remove the enamel surface layer and create access to the subsurface hypomineralized enamel (porous area). In Figure 7 it is possible to observe the matt appearance after the acid etching. In Figure 8, a drop of Icon-Dry (alcohol) was applied on the etched surfaces. After a few seconds, it is possible to see that some areas around the enamel pitting kept very white and opaque. This «optical test» after etching may be useful to indicate areas in which a more pronounced enamel wear is needed to create access to the hypomineralized layer. This extra step may be performed with repeated acid etchings or, in deeper lesions, with air abrasion or rotary instruments.

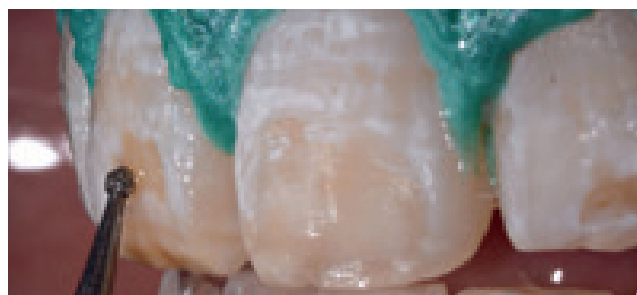

Fig. 9



Fig. 10

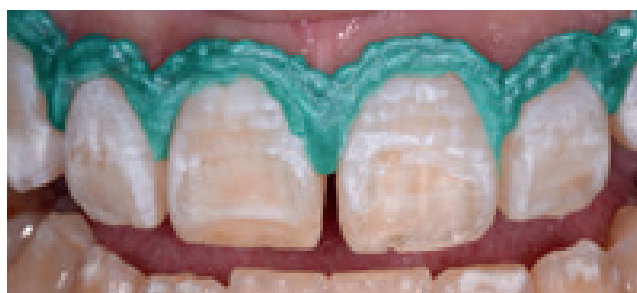

Fig. 11

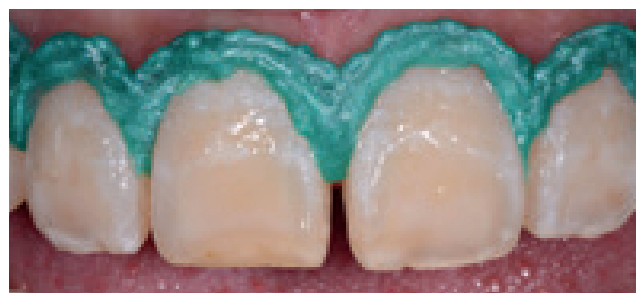

Fig. 12

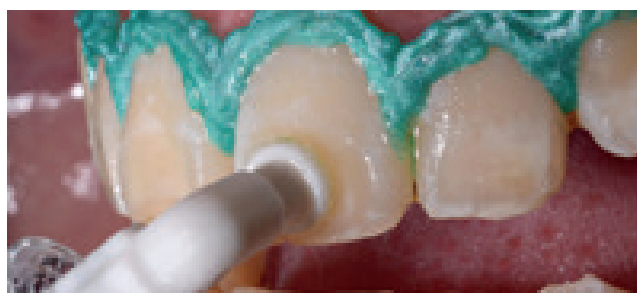

Fig. 13

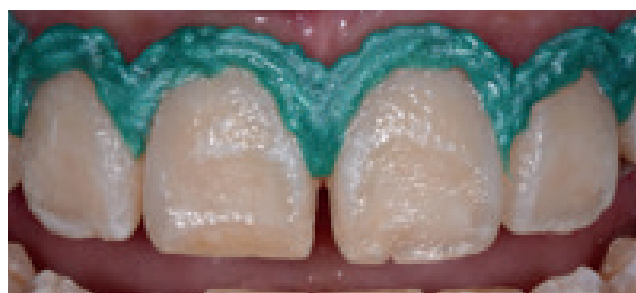


Fig. 14

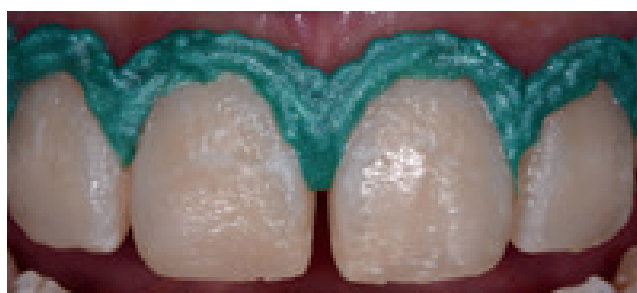

Fig. 15

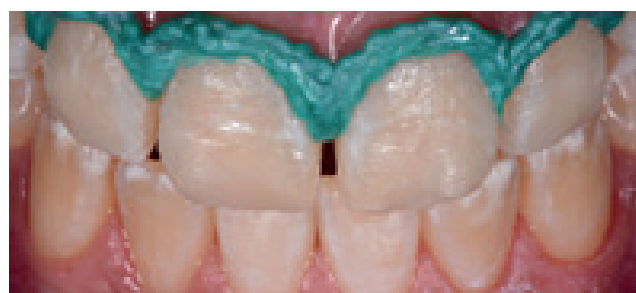

Fig. 16

Fig. 9-12: In this case we opted for diamond burs to wear the surface. Localized preparations were performed, removing the superficial part of the more affected enamel and areas of discoloration (where enamel pitting was already present) (Fig. 9). Then, Icon-Etch was applied once more for 2 mins (Fig. 10). Figure 11 shows the aspect after localized enamel wear and acid etching. It possible to see that there are still whitish areas that could be infiltrated. After etching Icon-Dry was dropped onto the surfaces (Fig. 12). Observe the more uniform aspect after alcohol application, indicating that a better access to the porous areas was achieved. Once the result was good, Icon-Dry was left for 30s and surfaces thoroughly dried.

Fig. 13-16: Icon-Infiltrant (the low-viscosity resinous infiltrant) was applied according to manufacturer's instructions (3 min, excess removal, light-curing; 1 min, excess removal, light-curing) (Fig. 13). In Figure 14 it is possible to see the aspect immediately after infiltration in which a uniform color was achieved and most of the whitish opacities were adequately masked. This uniform substrate eases composite resin stratification and improves final result since there is no need for masking white spots with opaque composites. Areas of worn enamel and previous enamel pitting were restored using only body and enamel shades (Fig. 15). It is interesting to say that after resin infiltration, if the surface was not contaminated, it is not necessary to apply an adhesive. Methacrylate-based composites effectively adhere to the infiltrant [6]. Figure 16 shows that tooth anatomy was correctly recovered. After composite resin application a careful finishing and polishing procedure was performed on the infiltrated and restored surfaces using abrasive disks, rubber cups and polishing pastes.

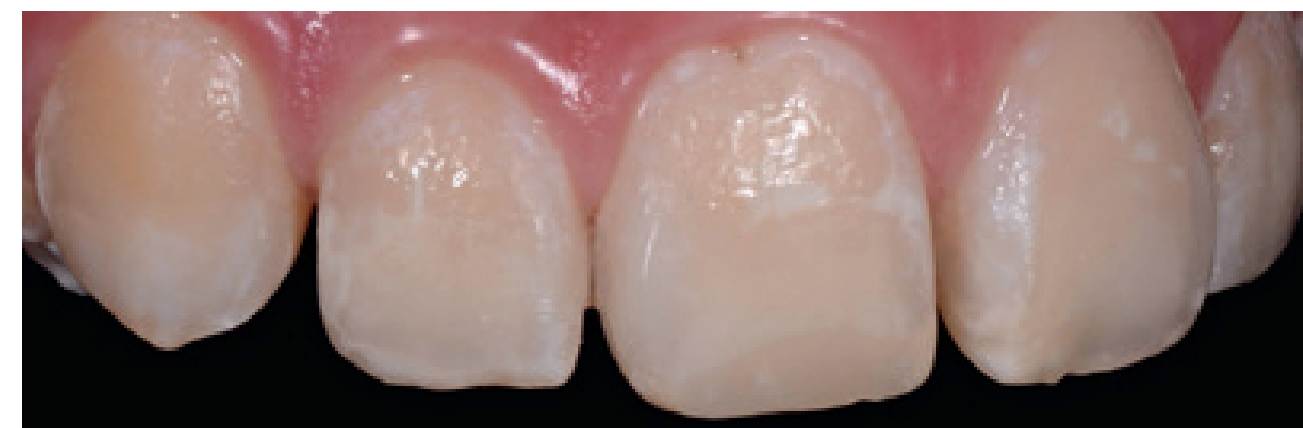

Fig. 17

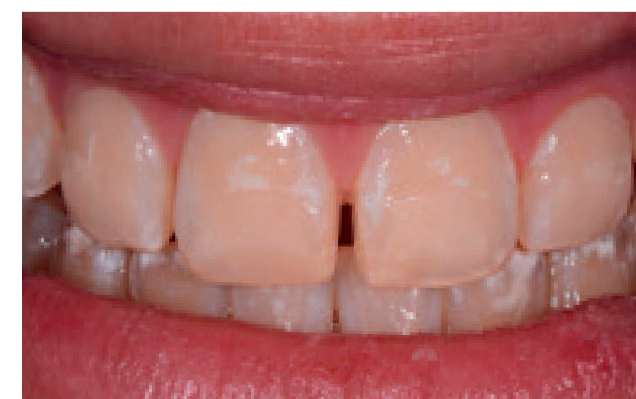

Fig. 18

Fig. 17-18: Figures 17 and 18 show the immediate results achieved after association of resin infiltration and composite resin. Esthetics were significantly improved. Patient and mother were very satisfied. Even though some enamel wear was needed, we considered this a simple, cost-effective, fast, and minimally invasive approach to deal with the clinical situation. Compare post-treatment pictures with Figures 1 to 3.

The presented treatment shows that an association of resin infiltration and composite resin may be an interesting approach to severe cases of fluorosis or other enamel defects that are nonresponsive to resin infiltration only. The localized wear performed with abrasive instruments removes the highly affected enamel and exposes the underlying porosities that are, then, able to be adequately infiltrated (technique known as »deep infiltration«). The advantage of infiltrating the (still porous) subsurface enamel before covering it with composites is that a uniform substrate is achieved, avoiding the need to use opaque dentin shades, that in thin thicknesses either do not mask the whitish underlying enamel or do not present the expected life-like esthetics and translucency of the enamel. Learning from cases like this on limitations of using resin infiltration alone, but its usefulness when associated with localized preparations and composite resin restorations allow the dentist to have new treatment possibilities that aim on a highly esthetic outcome with a minimally invasive approach.

Key Learnings

- Severe fluorosis or other very opaque (deep) enamel defects might require a previous enamel wear to allow underlying hypomineralized enamel to be adequately infiltrated;
- »Deep infiltration« promotes a uniform substrate that eases obtaining nice esthetic results with thin (and conservative) increments of body and enamel shades of composite resins;
- Bonding to composites after resin infiltration does not require an additional adhesive step. If after the infiltrant final light-curing there is no contamination of the operatory field, composite increments may be directly applied onto the infiltrated surfaces.

References

- Martínez-Mier EA, Maupomé G, Soto-Rojas AE, Ureña-Cirett JL, Katz BP, Stookey GK. Development of a questionnaire to measure perceptions of, and concerns derived from, dental fluorosis. *Community Dent Health*. 2004;21(4):299-305.
- Hilgert LA, Leal SC. Resin Infiltration: A Microinvasive Treatment for Carious and Hypomineralised Enamel Lesions. In: Eden E, editor. *Evidence-Based Caries Prevention*. Springer; 2017. p. 123-41.
- Gugnani N, Pandit IK, Gupta M, Gugnani S, Soni S, Goyal V. Comparative evaluation of esthetic changes in nonpitted fluorosis stains when treated with resin infiltration, in-office bleaching, and combination therapies. *J Esthet Restor Dent*. 2017;29(5):317-24.
- Attal JP, Atlan A, Denis M, Vennat E, Tirlot G. Taches blanches de l'émail: protocole de traitement par infiltration superficielle ou en profondeur (partie 2). *Int Orthod*. 2014;12(1):1-31.
- Aoba T, Fejerskov O. Dental fluorosis: chemistry and biology. *Crit Rev Oral Biol Med*. 2002 Mar;13(2):155-70.
- Wiegand A, Stawarczyk B, Kolakovic M, Hämmerle CHF, Attin T, Schmidlin PR. Adhesive performance of a caries infiltrant on sound and demineralised enamel. *J Dent*. 2011;39(2):133-40.

Fluorosis infiltration – Case study of a young patient.

Dr. Arzu Tuna, Dr. Umut Baysal, Dr. Rainer Valentin

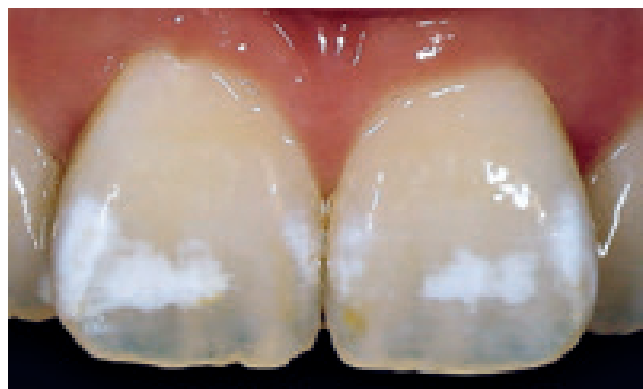


Fig. 1: Frontal view of the white spots 11, 21.

As part of a routine examination our patient reported an increasing urge to do something about the white spots on her anterior teeth (Fig. 1). After weighing various therapy options, it was jointly decided that infiltration was the treatment of choice [1]. In numerous studies there is evidence of almost optimal matching of infiltrated (orthodontic) white spot lesions to the shade of the natural tooth enamel [2, 3, 4, 5]. In terms of the localization, form, and patient's history, the white spots on the labial surfaces of teeth 11 and 21 are classified as fluorosis with severity 0.5 (community fluorosis index according to Dean). Masking of the white spots using infiltration is based solely on altering the refractive index near the whitish opacities. Healthy enamel has a refractive index (RI) of 1.62. The different refractive index at the margins causes light to scatter which gives the lesion a whitish appearance [6]. Regardless of whether the porosities are caused by incipient caries or a mild fluorosis, in the initial stage they appear as whitish staining to the human eye due to the lower refractive index. Infiltration of this area will change the refractive index and mask the opacities. Most of the data on infiltration in the labial surfaces of the anterior teeth are from patients following orthodontic multiband treatment. The resultant white spots can be very easily and permanently eliminated using infiltration [7, 8]. The success of the infiltration is highly dependent on the level of fluorosis damage. With very mild to moderate fluorosis, the infiltration technique has been successfully used in vitro as an intervention for fluorosis [9]. Nevertheless we decided to use infiltration because it is the least invasive treatment option in this case. If the infiltration was not successful, it would not prevent a

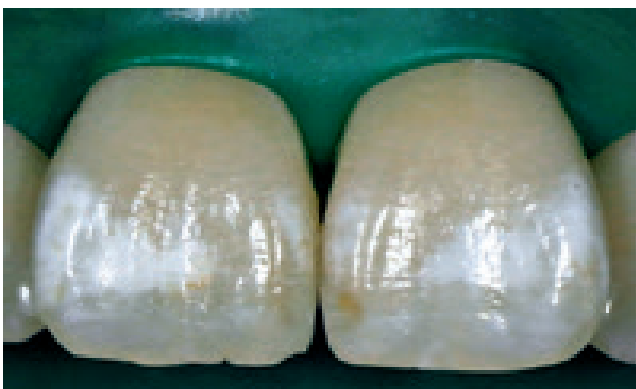

Fig. 2: Firstly, the teeth should be cleaned or (as in our case) a professional dental cleaning should be done. A protection of the mucous membranes using a dental dam is performed.

more invasive treatment method. A combination of the infiltration with composite treatment is definitely possible. This is because even with simultaneous composite treatment of enamel surfaces affected by caries no additional adhesive is required for the enamel. Only once dentin is involved, appropriate adhesives have to be used [10]. Therefore, there is nothing preventing an invasive composite treatment subsequent to successful infiltration (successful from an esthetic perspective). What is noteworthy is that the infiltrated teeth can be bleached with standard methods. The results are comparable with the effects that can be achieved with non-infiltrated teeth. This means that unwanted shade changes in the form of uneven shading of the teeth are of no concern [11, 12].

Key Learnings

- Icon-Infiltrant can penetrate into porosities in fluorosis white spots and thereby minimizes the difference of refractive index between the health enamel and fluorosis white spots.
- The number of etch times will be decided according to the assessing in Icon-Dry step. When the expected result is not achieved, the white spot need to be etched and dried again before infiltration step.
- Icon infiltration is a promising and micro invasive treatment for the patient impaired by fluorosis white spots.

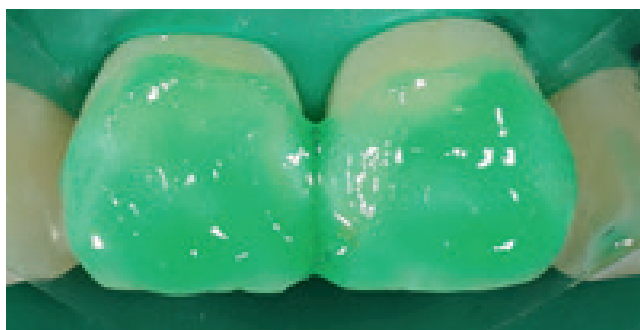


Fig. 3

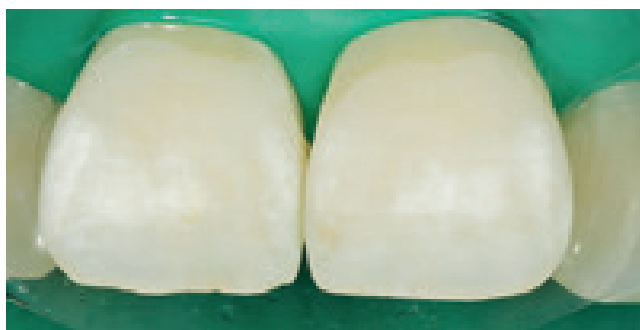

Fig.4

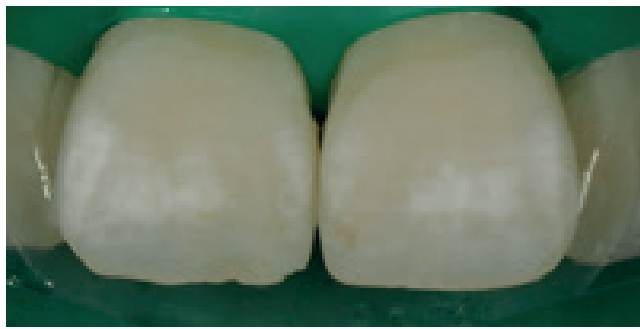


Fig. 5

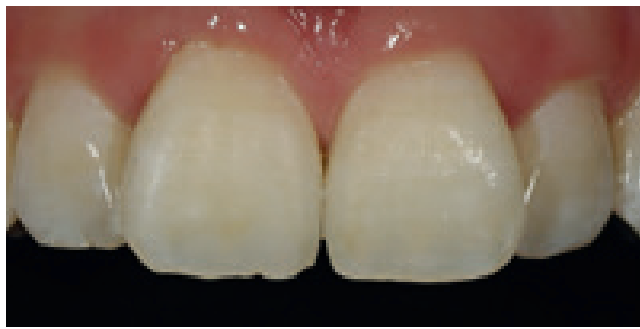


Fig. 6: Results immediately after treatment.

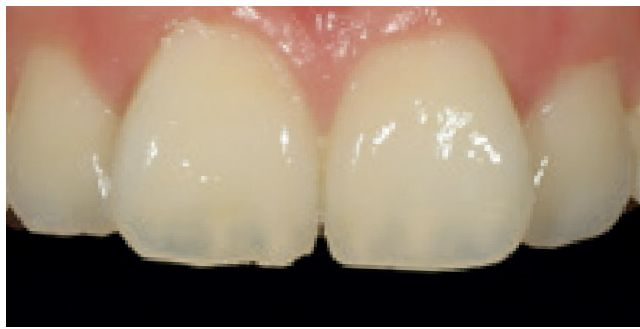


Fig. 7: The appearance after three months.

Fig. 3: After application of a dental dam, the entire labial surfaces were etched for two minutes with Icon-Etch. The procedure was repeated because the initial result was not satisfactory. During the drying with alcohol, there is a preview of the color change. The result was unsatisfactory, which in this case led to three times etching.

Fig. 4: After each etching procedure, Icon-Dry was used for drying after thoroughly spraying the acid off.

Fig. 5: The Icon-Infiltrant was then applied and left on for three minutes, the excess was removed, and this was followed by light curing. This procedure was repeated with the option of shortening the application time (one minute).

Fig. 6-7: After polishing, the treatment was complete and the patient was impressed by the final result.

References

- Paris S, Meyer-Lueckel H. Masking of labial enamel white spot lesions by resin infiltration--a clinical report. Quintessence Int. 2009 Oct;40(9):713-8.
- Gugnani N, Pandit IK, Gupta M, Josan R (2012); Caries Infiltration of Noncavitated White Spot Lesions: A novel approach for immediate esthetic improvement; Contemp Clin Dent 3:199-202
- Hammad SM, El Banna M, El Zayat I, Mohsen MA (2012); Effect of resin infiltration on white spot lesions after debonding orthodontic brackets; Am J Dent 25(1):3-8
- Kim S, Shin JH, Kim EY, Lee SY, Yoo SG (2011); The Evaluation of Resin Infiltration for Masking Labial Enamel White Spot Lesions; Int J Paediatr Dent 21(4):241-248 What constitutes dental caries? Histopathology of carious enamel and dentin related to the action of cariogenic biofilms.
- Kidd EA, Fejerskov O J Dent Res. 2004;83 Spec No C:C35-8. Caries lesions after orthodontic treatment followed by quantitative light-induced fluorescence: a 2-year follow-up.
- Mattousch TJ, van der Veen MH, Zentner A. Eur J Orthod. 2007 Jun;29(3):294-8. Epub 2007 May 5. Minimally invasive resin infiltration of arrested white-spot lesions: a randomized clinical trial.
- Senestraro SV, Crowe JJ, Wang M, Vo A, Huang G, Ferracane J, Covell DA Jr. J Am Dent Assoc. 2013 Sep;144(9):997-1005. Confocal Laser Microscopy Analysis of Resin-Infiltration Depth in Fluorotic Teeth;
- Uribe S, Perez R, Quijada V (2012); IADR Congress Abstract, #2746 Adhesive performance of a caries infiltrant on sound and demineralised enamel
- Wiegand A, Stawarczyk B, Kolakovic M, Hammerle CH, Attin T, Schmidlin PR. J Dent. 2011 Feb;39(2):117-21.
- Perry R, Nobrega D, Harsono M (2010); Bleaching of Teeth Treated with Icon by DMG America, Data on file; DMG, Hamburg, Germany
- Phark JH (2011); Bleaching through resin: Influence of resin infiltrant on bleaching; IADR Congress Abstract, #368

Resin Infiltration showing immediate esthetic improvement in non-pitted fluorosis.

Prof. Dr. Neeraj Gugnani

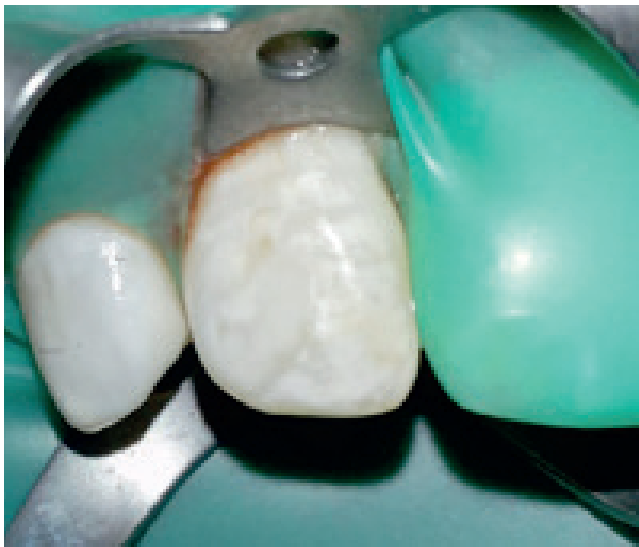

Fig. 1

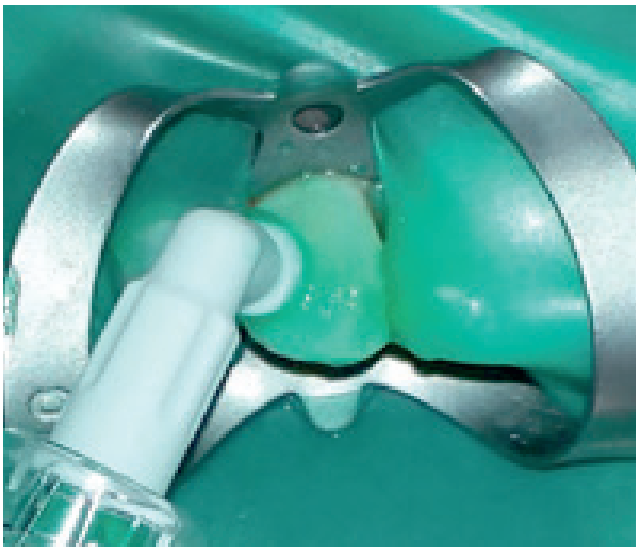

Fig. 2

Dental fluorosis is caused by ingestion of excess amounts of fluoride, mainly through water, and leads to esthetic alterations of teeth. Fluorosis is prevalent in countries which lack moderated community water supplies and people usually drink ground water having fluoride more than the stipulated limit of 1 ppm. Dental manifestation of fluorosis may vary from non-pitted white opacities/ brown stains covering partial or complete tooth surface (s) to pitted tooth surfaces. Conventionally dentists have been treating these non-pitted fluorosis lesions by bleaching, micro-abrasion, composite veneering while on the other end laminates/ crowns are frequently given for pitted fluorosis teeth. However recently a novel micro-invasive resin infiltration technique is introduced which has shown promising results for the treatment of demineralized white spot lesions, in terms of, both stopping the progress of these lesions and improving the esthetics [1]. Later the technique was tried by many dentists worldwide for other hypomineralized lesions, including fluorosis, hypomineralized developmental defects, Molar-Incisor hypomineralization cases,

trauma induced mineralization defects etc. [2, 3].

Clinical case

The present clinical case is of a patient who was having chalky white opaque areas covering the whole tooth/ teeth due to fluorosis. It was decided to treat the lesion using micro-invasive resin infiltration procedure, using vestibular Icon kit (DMG, Germany) for which the informed consent was sought from the patient. The vestibular Icon kit contain three syringes, along with applicator tips for facial surfaces, each to be used in the three step procedure for application of resin infiltration; namely 1. Etching: Icon-Etch which is composed of 15 % Hydrochloric acid, 2. Drying agent: Icon-Dry, composed of Ethanol, 3. Infiltrant: Icon-Infiltrant, composed of Infiltrant having very low viscosity resin allowing it to infiltrate in the body of lesion. The tooth represented in this clinical case is #12, which was isolated with rubber dam and the white opacity covering the whole tooth is visible in the pre-operative clinical picture (Fig. 1). This was followed by application of Icon-Etch for 2 minutes (Fig. 2).

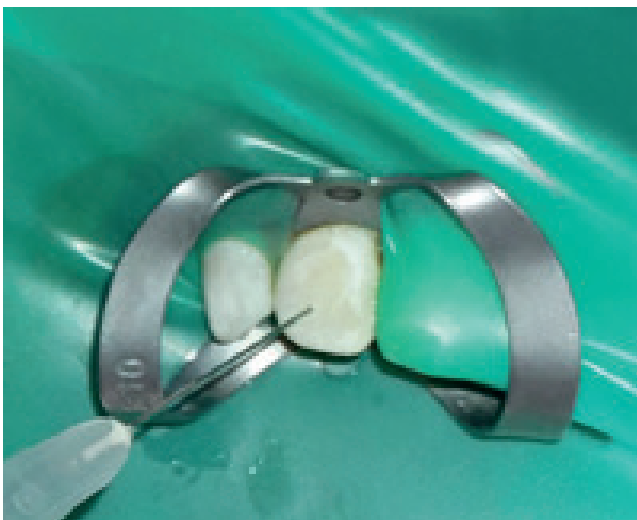

Fig. 3

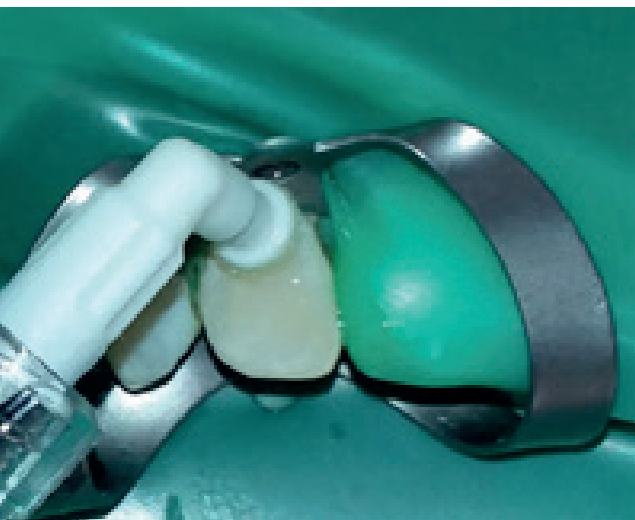

Fig. 4

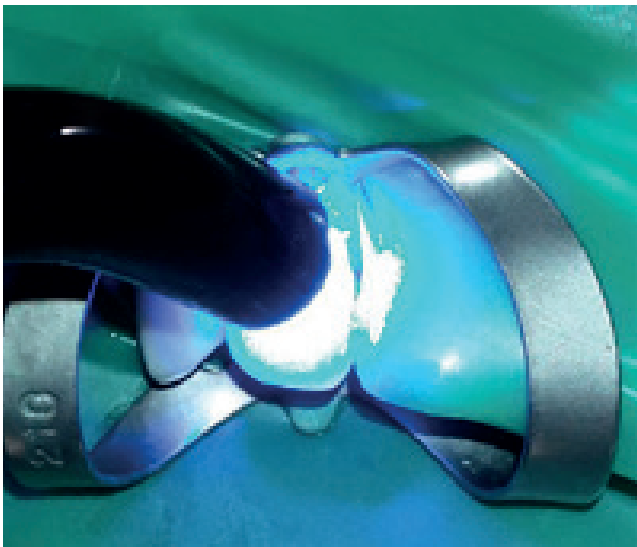


Fig. 5

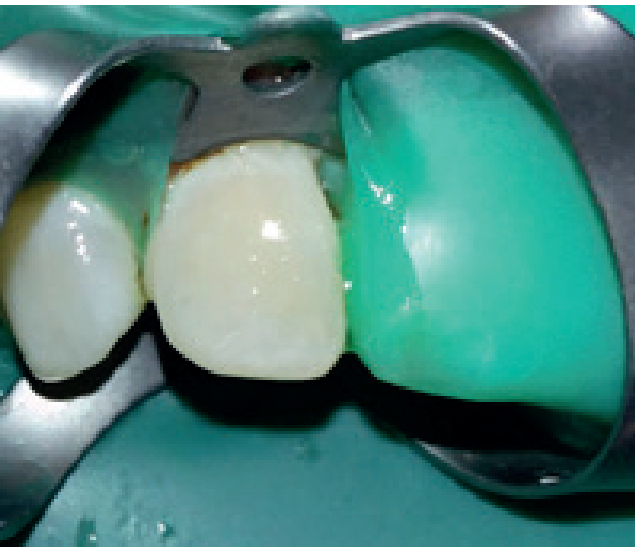

Fig. 6

Icon-Etch was washed off for 30 seconds and tooth was dried with oil free air. Etching was repeated again for 2 more minutes. Next the drying agent (Icon-Dry) was applied for 30 seconds (Fig. 3), which then evaporated leaving the accentuated pores making it easy for infiltrant to seep in. Lastly the infiltrant was applied (Fig. 4) and was left in place for 3 minutes followed by light curing the infiltrant for 40 seconds (Fig. 5) and a repetition of infiltrant application for 1 more minute. Immediate improvement in esthetics and good patient satisfaction was observed (Fig. 6).

Key Learnings

- It can be concluded that resin infiltration can be used for non-pitted white opacities which are due to fluorosis.
- In fact literature suggests that resin infiltration can be used for any kind of hypomineralization defects, however variations in the etching times and number of infiltrant applications are required, which depends on the depth of the lesion and should be judged clinically on case to case [4, 5, 6].

References

- Doméjean S, Ducamp R, Léger S, Holmgren C. Resin infiltration of non-cavitated caries lesions: a systematic review. *Med Princ Pract*. 2015;24(3):216-21.
- Gugnani N, Pandit IK, Goyal V, Gugnani S, Sharma J, Dogra S. Esthetic improvement of white spot lesions and non-pitted fluorosis using resin infiltration technique: series of four clinical cases. *J Indian Soc Pedod Prev Dent*. 2014 Apr-Jun;32(2):176-80.
- Auschill TM, Schmidt KE, Arweiler NB. Resin Infiltration for Aesthetic Improvement of Mild to Moderate Fluorosis: A Six-month Follow-up Case Report. *Oral Health Prev Dent*. 2015;13(4):317-22.
- Gugnani N, Pandit IK, Gupta M, Gugnani S, Soni S, Goyal V. Comparative evaluation of esthetic changes in nonpitted fluorosis stains when treated with resin infiltration, in-office bleaching, and combination therapies. *J Esthet Restor Dent*. 2017 Sep;29(5):317-324.
- Muñoz MA, Arana-Gordillo LA, Gomes GM, Gomes OM, Bombarda NH, Reis A, Loguercio AD. Alternative esthetic management of fluorosis and hypoplasia stains: blending effect obtained with resin infiltration techniques. *J Esthet Restor Dent*. 2013 Feb;25(1):32-9.
- Giannetti L, Murri Dello Diago A, Corciolani E, Spinaz E. Deep infiltration for the treatment of hypomineralized enamel lesions in a patient with molar incisor hypomineralization: a clinical case. *J Biol Regul Homeost Agents*. 2018 May-Jun;32(3):751-754.

Resin infiltration as a micro invasive treatment for fluorosis.

Prof. Dr. Leandro Augusto Hilgert, Marília Bizinoto Silva Duarte

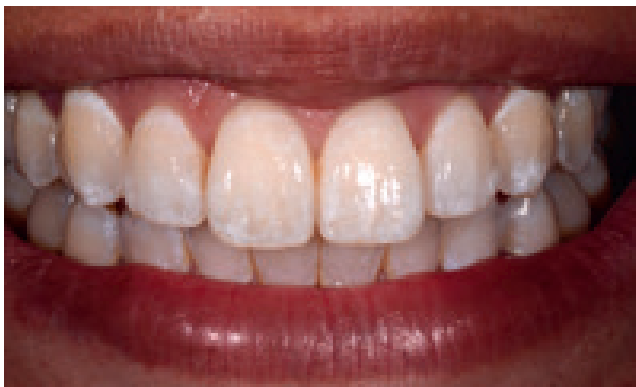

Fig. 1
A 26-year old female patient presenting mild to moderate fluorosis looked for esthetic treatment. Her main complaint regarded the whitish diffuse opacities that affected her smile.

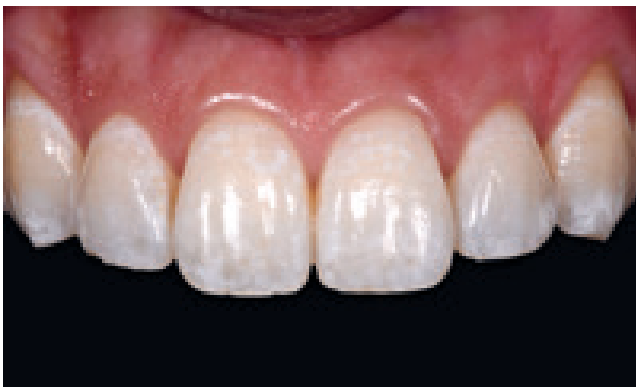


Fig. 2
A 26-year old female patient presenting mild to moderate fluorosis looked for esthetic treatment. Her main complaint regarded the whitish diffuse opacities that affected her smile.

Fluorosis is observed, clinically, from mild diffuse white opacities on the enamel to severe whitish/brownish staining and enamel surface malformation. Those conditions may compromise esthetics according to its severity. For light to moderate fluorosis, the most common cases, there are reports that resin infiltration may successfully mask the opacities improving esthetics with very low enamel wear. The aim of this case report is to present a step by step description of the resin infiltration technique as a microinvasive alternative for the esthetic treatment of fluorosis. Considerations on how to diagnose depth of the opacities and on how many times to etch the enamel to improve results predictability are presented. Main features of the resin infiltration technique and other established esthetic treatments for fluorosis are discussed.

Introduction

Fluorosis is characterized by subsurface enamel hypomineralization (porosities) caused by excessive fluoride intake during enamel development [1, 2]. In mild to moderate cases of fluorosis, the lower refractive index (RI) of the porosities contents gives the enamel a diffuse whitish opaque appearance that, for some patients (according to fluorosis severity), may be aesthetically unpleasant. Many treatment options are available for fluorosis as: (a) bleaching, that can possibly reduce the contrast between whitish opacities and sound enamel; (b) microabrasion, in which the surface and subsurface of the affected enamel are worn out by a combination of acids and abrasives, exposing the underlying sound enamel; (c) macroabrasion, where a preparation is performed on the affected fluorotic areas followed by a restoration; and, (d) resin infiltration,

a technique that involves a very mild wear of the surface enamel, exposing the porous subsurface that is subsequently infiltrated by a low-viscosity resin that has a RI more similar to sound enamel [3, 4]. Usually, bleaching alone is not capable of providing a complete optical blending of the fluorotic to the sound enamel. Micro and macroabrasion techniques are effective, but require a more invasive approach, removing the whole affected enamel. Resin infiltration appears as a suitable alternative that combines good results with a very low invasiveness.

The aim of this case report is to describe in details the resin infiltration protocol on the esthetic treatment of a mild to moderate fluorosis case.

Case Report

A 26-year old female patient presenting mild to moderate fluorosis looked for esthetic treatment. Her main complaint regarded the whitish diffuse opacities that affected of her smile (Fig. 1 and 2). The patient, a dentist, was questioned on how glad she was with the shade of her teeth and she answered that she would like a more natural, less white appearance. This is a crucial question since after treating mild/moderate fluorosis teeth will become more chromatic and presenting less value. Therefore, patients that enjoy a very white shade should be counseled to bleach before treating the fluorotic lesions. The patient was very pleased with the esthetic result that was obtained with a microinvasive approach.

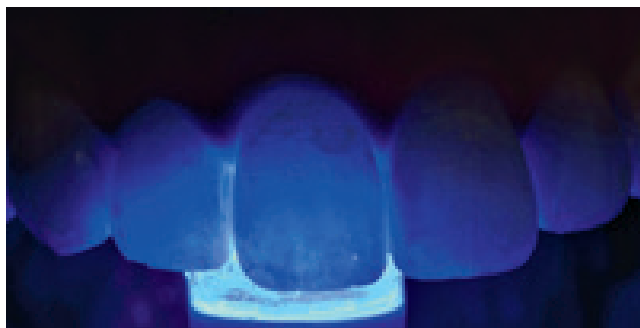


Fig. 3

Fig. 3: To evaluate the depth of the affected enamel a clinically useful tool is to perform transillumination. Specific equipment or even a simple light curing unit can be positioned on the lingual surface and commanded to emit light. When the transmitted light is not or is only slightly blocked by the opacities, the lesions (enamel porosities) are shallow and the probability of less invasive therapies to be effective is higher. In the present case, this was the situation and the fluorotic lesions were judged shallow, indicating a good prognosis for resin infiltration.

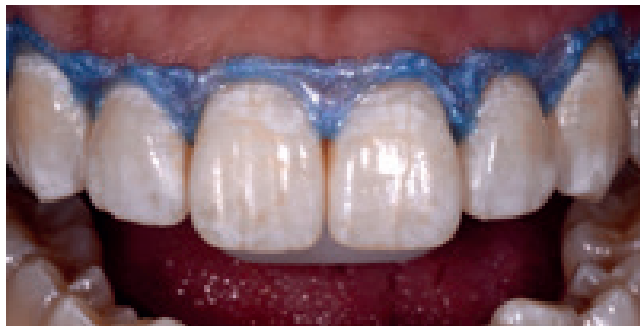

Fig. 4

Fig. 4: Next step is isolating the teeth that will be infiltrated. Field isolation and protection of the gingival tissue can be obtained using rubber dam or a liquid light-cured resin dam (Top Dam, FGM, Brazil) together with cheeks, lips and tongue retractors. While the liquid dam is usually faster and easier to apply, rubber dam may present a more intense gingival retraction, that may improve results in the cervical area. In this case, the liquid dam was selected and carefully applied to cover as little enamel as possible.

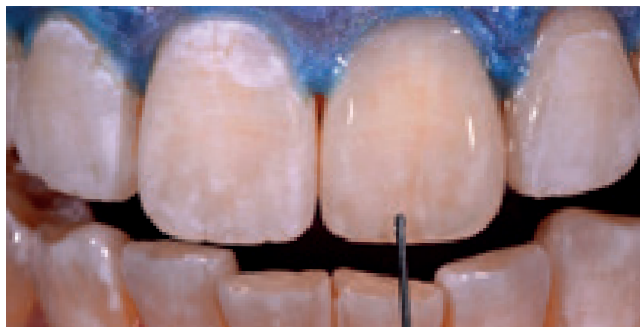


Fig. 5

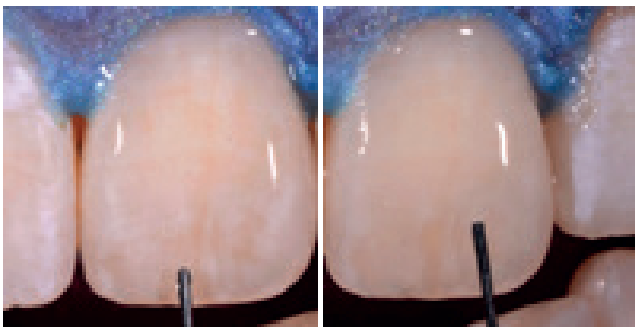


Fig. 6

Fig. 5-6: Resin infiltration protocol begins with etching of the surface enamel using a 15 % hydrochloric acid gel (Icon-Etch, DMG, Germany) that should stay in contact for 2 minutes aiming to wear the surface layer and expose the porous hypomineralized subsurface. After suctioning the acid gel, rinsing and air-drying the enamel a drop of ethanol (Icon-Dry, DMG, Germany) is applied on the etched surface and the observed optical aspect of the white opacities should be already minimized. If the opacities are still very visible when the ethanol is applied, a second (or even a third) etching steps is indicated.

In the present case, in Figure 5, it is possible to observe the aspect after a single etching procedure. Since the opacities were still very visible it was decided to repeat the etching step once more. In Figure 6, it is possible to see the difference between the aspect after one and two etching steps as a drop of Icon-Dry was applied onto the etched enamel surface. Since the result was satisfactory, the ethanol was let on the surface for 30 s to promote a thorough desiccation of the enamel, followed by air-drying.

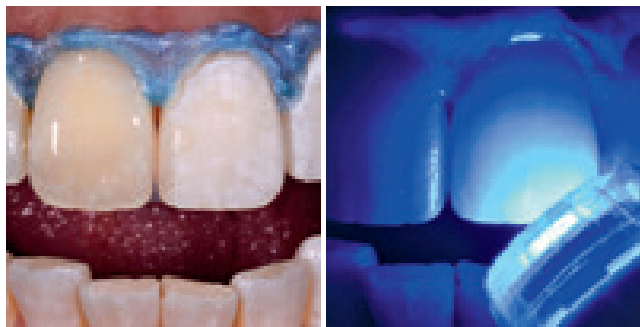


Fig. 7

Fig. 7-8: On the etched and dry enamel the low-viscosity infiltrant (Icon-Infiltrant, DMG, Germany) is applied and should remain for at least 3 minutes to achieve maximal infiltration depth into the porosities of the hypomineralized enamel. In Figure 7 it is possible to observe the aspect after infiltrant application on the right upper teeth, while the left have not received the resin yet. When all teeth received the infiltrant and the 3 minutes waiting period was respected, obvious excess can be removed using a gauze and light-curing is performed (Fig. 8). It is paramount to execute a thorough polymerization using adequate irradiance and exposure time (40 seconds per tooth). A second application of the infiltrant should be performed for 1 minute followed by excess removal and light-curing.

Fig. 8

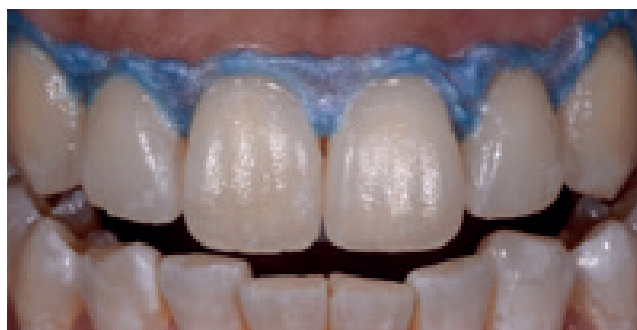


Fig. 9: It is possible to see the immediate aspect after infiltrant polymerization. It is normal to observe a shiny and irregular appearance due to excess of the infiltrant covering the surface. These material is easily removed with polishing instruments as abrasive disks, spirals or rubber cups.

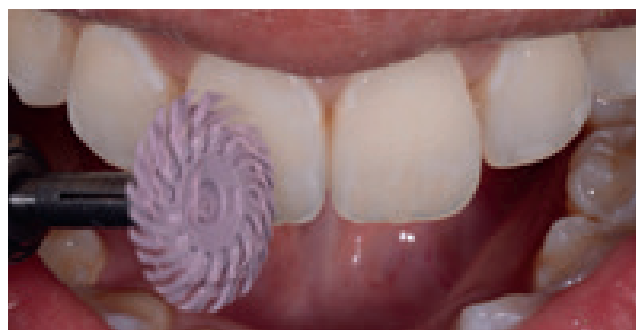


Fig. 10: In the present case polishing was performed using disks and spirals (Sof-lex, 3M, USA).

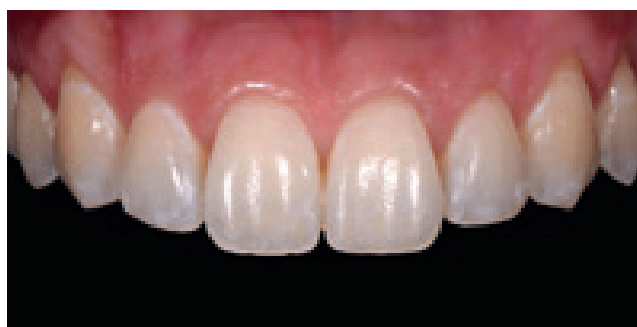


Fig. 11 After polishing, the result of the treatment is shown on Figure 11 and 12. Almost all white opacities disappeared, indicating a satisfactory infiltration of the fluorotic enamel.

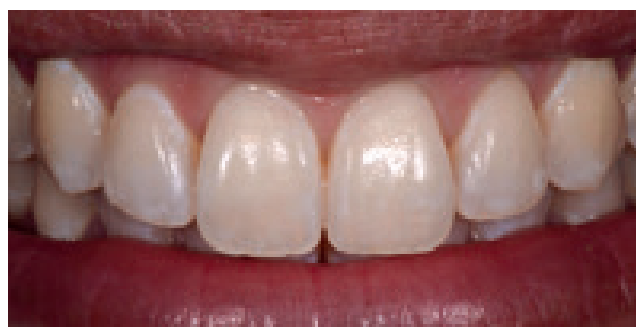


Fig. 12

Discussion

An ideal esthetic treatment is the one that can please the demands of the patient, that require very little wear of sound enamel (low biological cost), that can be simply and quickly executed and that lasts.

Patients that present fluorotic enamel may not require any kind of esthetic treatment, especially if presenting a mild severity of the lesions [5]. However, whenever a treatment is required, the dentist should be able to offer treatment options that present efficacy, low invasiveness and durability.

Resin infiltration is a technique based on the acid dissolution of the well-mineralized surface layer of the enamel (with a thickness of around 30-40 µm) [6], exposing the porous hypomineralized enamel of the subsurface. After thorough drying, a low-viscosity resin is infiltrated into the porosities of the enamel by capillary forces filling the spaces with a material that has a closer refractive index to sound enamel. Therefore, the optical appearance of the infiltrated enamel blends with the sound enamel, significantly improving the esthetic harmony of the smile [7-9].

For the infiltration process to be effective the first step is to diagnose the kind of white opacity. Deeper lesions, that are very opaque to transillumination (as in some molar-incisor hypomineralization cases) usually do not present the best results for any kind of less invasive treatment and may require some localized tooth preparation. Shallow to medium depth lesions, as those depicted in the case report, that clinically do not block the light passage during transillumination (see Fig. 3) have usually a favorable prognosis for resin infiltration.

Next, another fundamental step for a successful resin infiltration is adequate removal of the well-mineralized surface layer therefore exposing the porous subsurface. If an adequate access for the resin to infiltrate the porosities is not achieved, the technique will not present the best results. A very effective way of testing if the surface layer was removed after the acid etching step is observing what happens when a drop of ethanol is applied on the etched enamel. If the optical result already looks good, surface layer was properly removed. If the white opacities are still very visible, a new etching step should be performed (see Fig. 6, that depicts the difference between one and two etching steps). An easy and simple method to decide if re-etching is necessary before the drying and infiltration steps.

It is imperative for the dentist to realize that the main difference from resin infiltration to microabrasion is that in the first method the porous enamel is preserved and infiltrated while the later method esthetic success is based on the complete removal of the affected enamel. That is why the technique is indicated for lesions no deeper than 0.2 to 0.3 mm (200 to 300 µm) [10]. Therefore, it is clear that microabrasion is a more invasive alternative, requiring much more enamel wear to present pleasant results.

The color stability of the resin infiltrated enamel has been tested in vitro,(8) in clinical studies [11] and presented in numerous case reports [4, 12-15]. So far results are positive and very promising. This hybrid structure of enamel/infiltrant (the infiltrated enamel) can be successfully daily submitted to the »polishing« of oral hygiene and able to be polished by the dentist in routine clinical sessions.

Based on the substantial amount of available scientific evidence, clinical reports and our clinical experience of almost eight years conducting resin infiltration treatments, this approach has become our standard of care in treating light to moderate fluorosis. Important to state that for many patients that desire to treat the fluorotic opacities and to have whiter teeth, a bleaching procedure is usually performed before resin infiltration [16].

Conclusion

Resin infiltration seems to be a successful microinvasive treatment for the esthetic treatment of light to moderate fluorosis.

Key Learnings

- Resin infiltration is a microinvasive approach for the treatment of slight to moderate fluorosis;
- Additional acid etchings may be necessary to improve resin infiltration. Observing the visual aspect when applying Icon-Dry may be a good way of determining the need for repeating the etching step;
- Removal of Icon-Infiltrant excesses before light-curing and adequate finishing and polishing after light-curing are important steps to promote a nice surface texture.

References

- Fejerskov O, Manji F BV. The nature and mechanism of dental fluorosis in man. *J Dent Res*. 1990;69(Spec Iss):692–700.
- Aoba T, Fejerskov O. Dental fluorosis: chemistry and biology. *Crit Rev Oral Biol Med*. 2002 Mar;13(2):155–70.
- Duarte MBS, Hilgert LA. Infiltração resinosa: tratamento microinvasivo para melhoria estética de lesões cariosas e hipomineralizadas de esmalte. In: Monte Alto R. *Reabilitação Estética Anterior*. São Paulo:Napoleão; 2017.
- Hilgert LA, Leal SC. Resin Infiltration: A Microinvasive Treatment for Carious and Hypomineralised Enamel Lesions. In: Eden E. *Evidence-Based Caries Prevention*. Springer; 2017. p. 123–41.
- Nair R, Chuang JCP, Lee PSJ, Leo SJ, Yang NQY, Yee R, et al. Adult perceptions of dental fluorosis and select dental conditions-an Asian perspective. *Community Dent Oral Epidemiol*. 2016;44(2):135–44.
- Meyer-Lueckel H, Paris S, Kielbassa AM. Surface layer erosion of natural caries lesions with phosphoric and hydrochloric acid gels in preparation for resin infiltration. *Caries Res*. 2007;41(3):223–30.
- Paris S, Meyer-Lueckel H. Masking of labial enamel white spot lesions by resin infiltration--a clinical report. *Quintessence Int*. 2009;40(9):713–8.
- Paris S, Schwendicke F, Keltsch J, Dörfer C, Meyer-Lueckel H. Masking of white spot lesions by resin infiltration in vitro. *J Dent*. 2013;41(5):e28-e34.
- Torres CRG, Borges AB, Torres LMS, Gomes IS, De Oliveira RS. Effect of caries infiltration technique and fluoride therapy on the colour masking of white spot lesions. *J Dent*. 2011;39(3):202–7.
- Benbachir N, Ardu S, Krejci I. Indications and limits of the microabrasion technique. *Quintessence Int (Berl)*. 2007;38(10):811–5.
- Eckstein A, Helms H-J, Knösel M. Camouflage effects following resin infiltration of postorthodontic white-spot lesions in vivo: One-year follow-up. *Angle Orthod*. 2015 May;85(3):374–80.
- Muñoz MA, Arana-Gordillo LA, Gomes GM, Gomes OM, Bombarda NHC, Reis A, et al. Alternative Esthetic Management of Fluorosis and Hypoplasia Stains: Blending Effect Obtained with Resin Infiltration Techniques. *J Esthet Restor Dent*. 2013 Feb;25(1):32–9.
- Cocco A, Lund R, Torre E, Martos J. Treatment of Fluorosis Spots Using a Resin Infiltration Technique: 14-month Follow-up. *Oper Dent*. 2016;41(4):357–62.
- Torres C, Borges A. Color Masking of Developmental Enamel Defects: A Case Series. *Oper Dent*. 2015;40(1):25–33.
- Tirlet G, Chabouis HF, Attal J-P. Infiltration, a new therapy for masking enamel white spots: a 19-month follow-up case series. *Eur J Esthet Dent*. 2013;8(2):180–90.
- Gugnani N, Pandit IK, Gupta M, Gugnani S, Soni S, Goyal V. Comparative evaluation of esthetic changes in nonpitted fluorosis stains when treated with resin infiltration, in-office bleaching, and combination therapies. *J Esthet Restor Dent*. 2017;29(5):317–24.

Case Report: Masking of fluorosis by resin infiltration.

Prof. Dr. Sebastian Paris

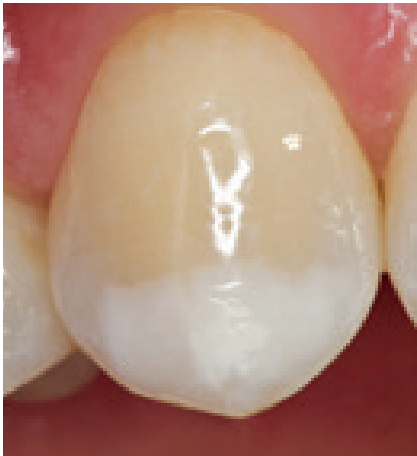

Fig. 1: Initial situation

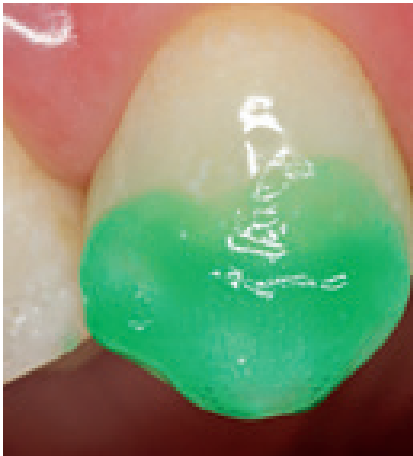


Fig. 2: After cleaning with prophylaxis paste, the affected vestibular area was initially conditioned for 2 minutes with 15% hydrochloric acid gel (Icon-Etch, DMG). At this juncture, the more heavily mineralized surface layer was removed. This shows fewer pores as a result of remineralization processes than the lesion underneath and would thus prevent the infiltrant from penetrating. After 2 minutes, the etching gel was water sprayed off and the lesion carefully dried.

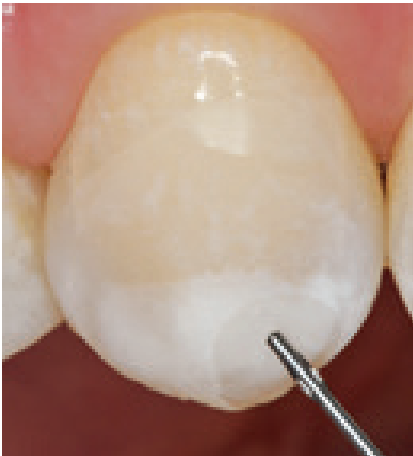

Fig. 3: To achieve further deep drying and at the same time check whether sufficient abrasion of the surface layer was achieved, ethanol (Icon-Dry) was subsequently applied to the lesion. Due to penetration of the ethanol into the lesion's porosities, similar to the later infiltration with resin, the light refraction within the caries was reduced, making the lesion appear less whitish-opaque. When this effect can be observed in the first 2-5 seconds after application of the ethanol, the surface layer is sufficiently abraded to guarantee a quick and complete infiltration.

A 19-year-old patient presented in the university outpatient clinic requesting treatment of whitish spots on her teeth, which she found esthetically disturbing. According to the patient, the spots had already been visible since her adult teeth came through. For this reason, composite fillings had already been placed on the anterior incisors. After a visual-tactile examination, the discolorations were diagnosed as dental fluorosis. Whitish opaque discolorations of the tooth enamel, which are also brownish opaque in severe forms, are characteristic of dental fluorosis cases. These discolorations are mostly located outside the traditional caries predilection sites. The whitish changes often affect several teeth, are poorly defined, are more clearly visible when the teeth are dried and are accentuated on the perikymata. Also characteristic is so-called »snow capping«, a whitish discoloration of the incisal third of the teeth (Fig. 1). Various therapy options were discussed with the patient, including bleaching, resin infiltration, microabrasion and composite restorations, while the associated necessity for tooth structure removal, the predictability of the esthetic result, the long-term prognosis and the costs were weighed against each other. The patient opted for resin infiltration due to the relatively low tooth structure removal, good predictability and manageable costs. For a better estimate of the esthetic result, the most severely affected tooth (13) was treated first. In the present case, there was no isolation with rubber dam because desiccation and protection of the soft tissue could be guaranteed by an adequate distance to the gingiva.

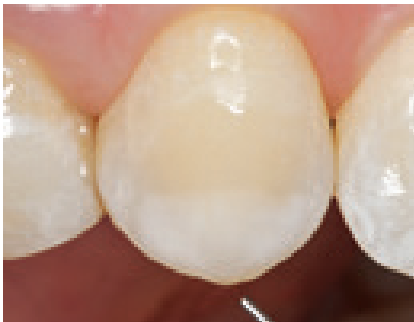

Fig. 4

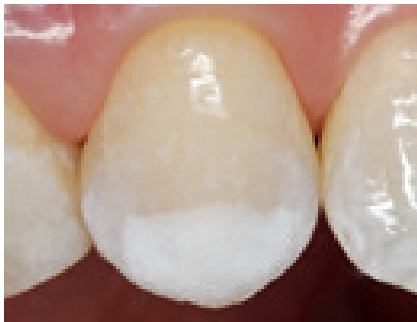

Fig. 5

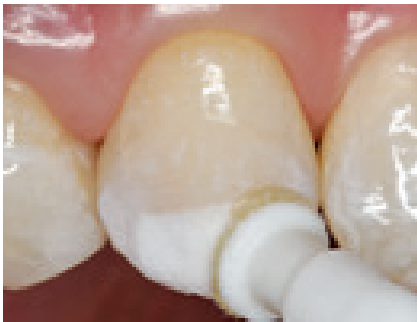

Fig. 6

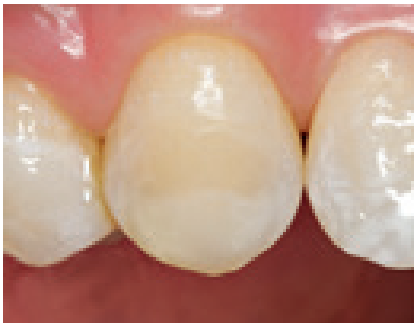

Fig. 7

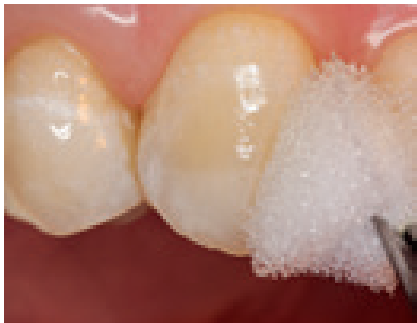

Fig. 8

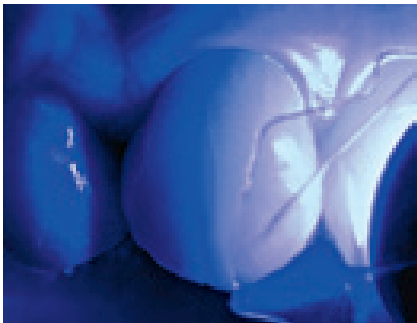


Fig. 9

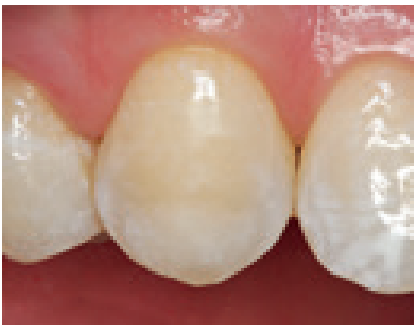

Fig. 10

Key Learnings

- When Icon-Dry was applied to the lesion, the lesion was masked and appeared less whitish opaque due to the penetration of the ethanol into the lesion's porosities. This effect should be observed in the first 2-5 seconds after application of the ethanol. If this effect comes slower, it most often indicates that the lesion should be etched again.
- Polishing after infiltration treatment is very important to remove the oxygen inhibition layer on the resin.
- When several lesions need to be treated, it will be better to treat one of the lesions first to make sure Icon infiltration treatment works well on this patient and also give the patient more confidence to perform following treatment.

Fig. 4: If the color change is slower, this most often indicates that the surface layer has not been eroded completely. In this case, the lesion should be etched again. In the present case, the lesion was etched again for 2 minutes, the etching gel subsequently sprayed off, the lesion dried with compressed air and ethanol applied once again. Fig. 5: At this juncture, an instant (< 2 seconds) disappearance of the lesion's opacity could now be observed, which indicates adequate removal of the surface layer. In preparation for the subsequent infiltration, the ethanol was vaporized with compressed air and the lesion consequently dried thoroughly. Fig. 6-7: The infiltrant (Icon-Infiltrant, DMG) was applied in the subsequent step. It could also be observed here how the resin penetrated the lesion and adapted its color to the surrounding tooth enamel. Fig. 8: Even though the lesion was fully masked after a few seconds, the excess resin was only removed from the lesion surface with a foam pellet after 3 minutes. Fig. 9: The resin then underwent light-curing for 40 seconds. To compensate for the infiltrant's polymerization shrinkage, the resin was applied again and cured again after 1 minute (no illustration). Thanks to the oxygen inhibition of the polymerization of the resin surface layers, a thin raw unpolymerized resin layer remains on the enamel surface. This should be removed by polishing. In the current case, polishing was carried out with polishing disks (Sof-Lex, 3M Espe). Fig. 10: The final result on tooth 13 was very satisfactory immediately after the treatment. The remaining teeth (12-23) were thus subsequently treated as described above and showed complete masking of the fluorosis immediately after treatment.

Minimally invasive aesthetic restoration for severe dental fluorosis – combination resin infiltrating with at-home bleaching.

Dr. Ryan Li

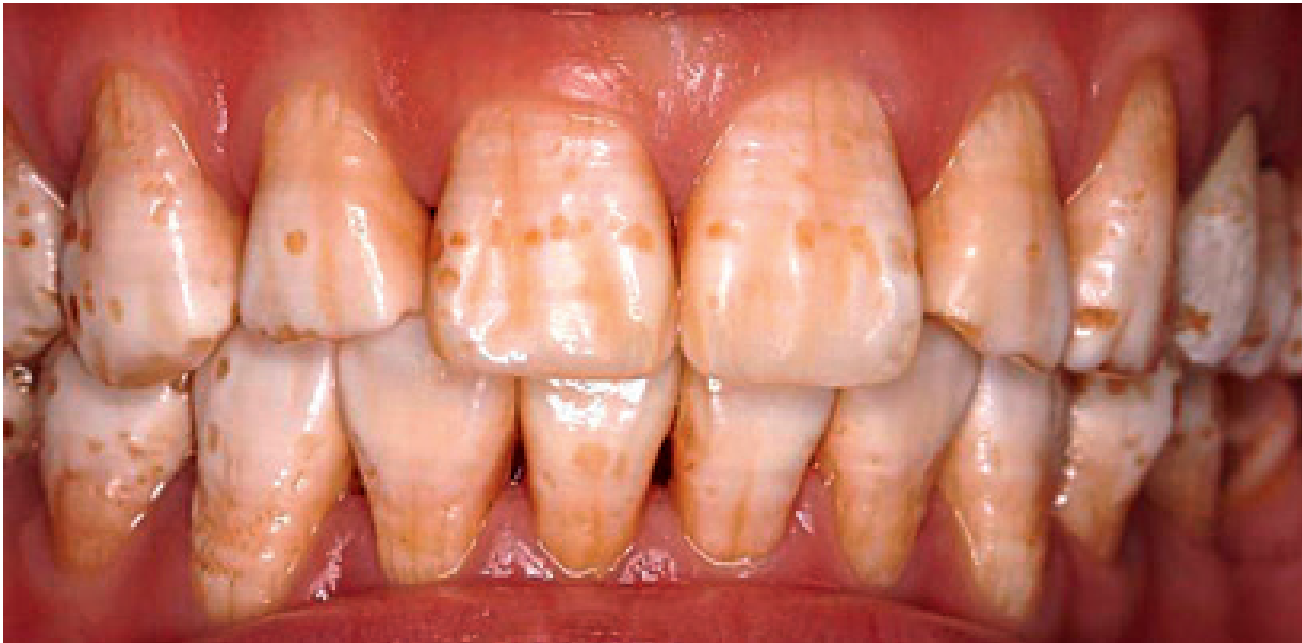

Fig. 1: Before treatment. The full dentition was mottled and defected. We chose at-home bleaching first to improve the color of the teeth.

Dental fluorosis is an extremely common disorder, characterized by hypomineralization of tooth enamel caused by ingestion of excessive fluoride during enamel formation. It appears as a range of visual changes in enamel causing degrees of intrinsic tooth discoloration, and, in some cases, physical damage to the teeth. The severity of the condition is dependent on the dose, duration, and age of the individual during the exposure. The »very mild« (and most common) form of fluorosis, is characterized by small, opaque, »paper« white areas scattered irregularly over the tooth, covering less than 25 % of the tooth surface. In the »mild« form of the disease, these mottled patches can involve up to half of the surface area of the teeth. When fluorosis is moderate, all of the surfaces of the teeth are mottled and teeth may be ground down and brown stains frequently »disfigure« the teeth. Severe fluorosis is characterized by brown discoloration and discrete or confluent pitting; brown stains are widespread and teeth often present a corroded-looking appearance. People with fluorosis are relatively resistant to dental caries (tooth

decay caused by bacteria), although they may be of cosmetic concern. In moderate to severe fluorosis, teeth are physically damaged. Traditional treatment options for dental fluorosis are porcelain laminate veneer or all-ceramic crowns, which are invasive and expensive. These treatments need normally long clinical procedure (several appointments). Combination resin infiltrating technology with at-home bleaching is a minimally invasive method for treating dental fluorosis and easy to operate. Therefore it is more acceptable for patients.

Clinical case

A 23-year-old female patient complained about severe discoloration and discrete pitting on anterior teeth and hoped to improve tooth appearance. After clinical examination, severe dental fluorosis was diagnosed. We offered a treatment protocol – minimally invasive aesthetic restoration combining resin infiltrating with at-home bleaching.

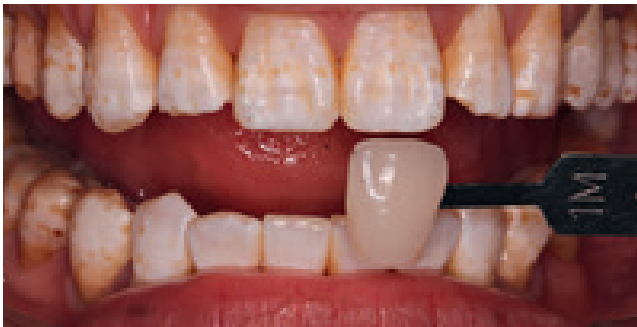

Fig. 2: After the comprehensive clinical examination the colorimetric analysis was done and the color of the teeth was recorded. We made individual bleaching tray for the patient and gave the instructions of at-home bleaching and oral health instruction. After using eight units of Opalescence PF 10 % for four weeks, the color of teeth improved dramatically. We began the Icon resin infiltration treatment.

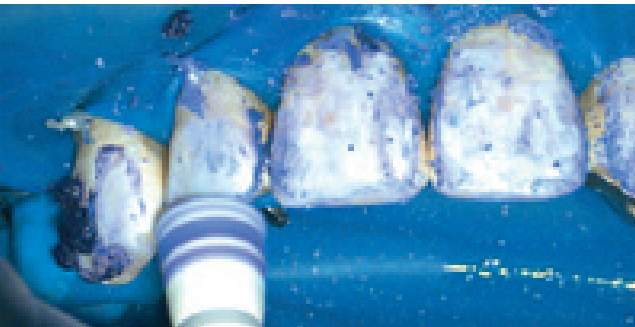


Fig. 3: The use of rubber dam is essential when Icon is applied. After cleaning the teeth, rubber dam was performed to isolate the operative site from the rest of the mouth. Tooth cervix was tied off with dental floss. Applied Opalustre grinding paste, which is 6.6 % hydrochloric acid slurry that contains silicon carbide microparticles, on the tooth surface. Polish for 60 s with low speed dental handpiece and rubber cup under the middle pressure. Rinse the grinding paste and evaluate the effect.

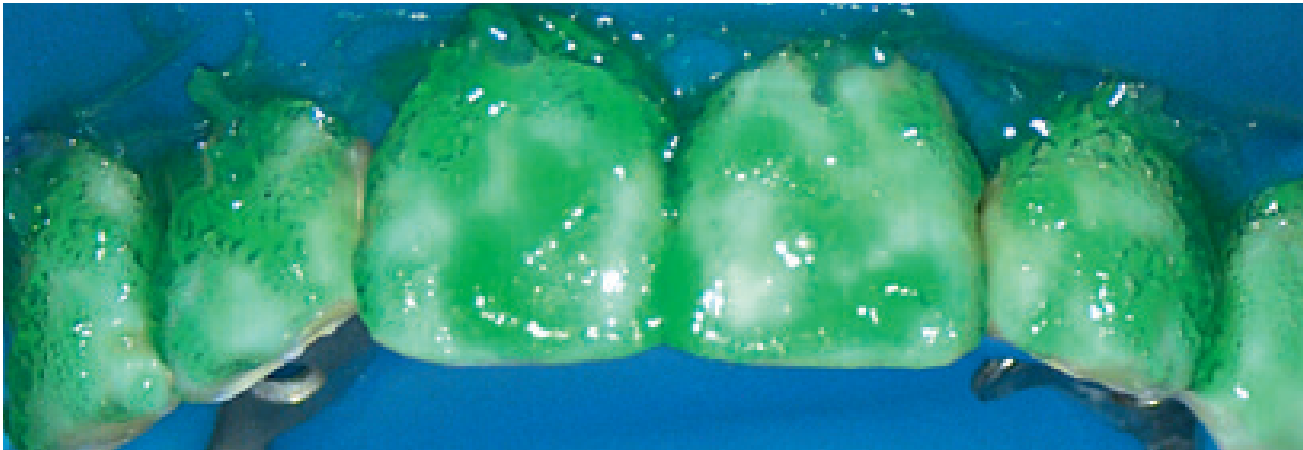


Fig. 4: Icon-Etch was applied for 2 minutes and sprayed with water and air for 30 seconds. Dry with oil-free and water-free air.

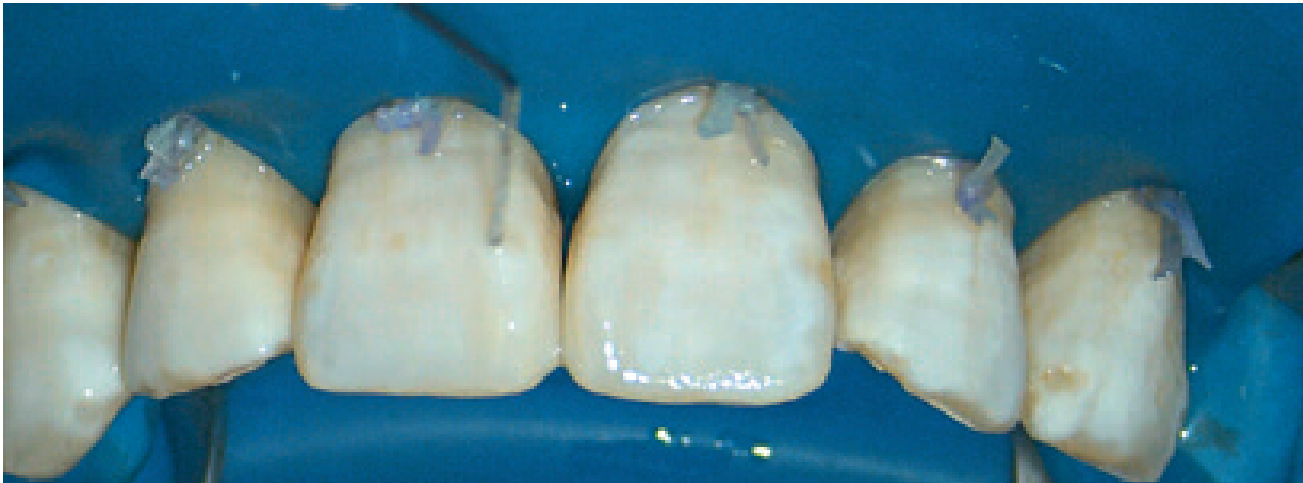

Fig. 5: Screw the application tip onto the Icon-Dry syringe, apply an ample amount of material onto the lesion, and allow to set for 30 s. In this step a preview of the final result is shown. When wetted with Icon-Dry, the whitish-opaque coloration on the etched enamel should diminish. The result of the visual check after the first etching showed that the second etching is necessary.

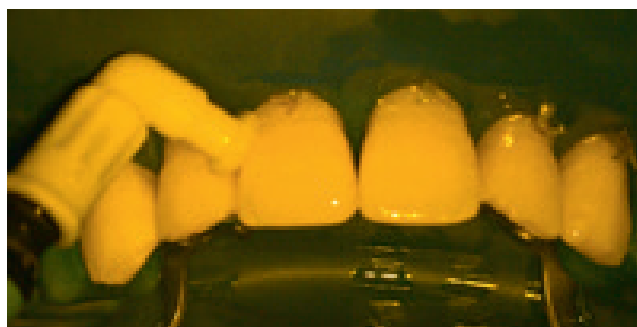

Fig. 6

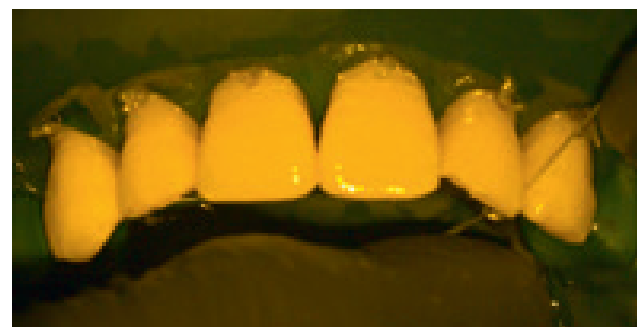


Fig. 7



Fig. 8

Fig. 6 and 7: After the second application of Icon-Etch and Icon-Dry, the result of visual check was satisfied. After drying the enamel surface, apply an ample amount of Icon-Infiltrant onto the etched surface under safe light source. Allow Icon-Infiltrant to set for 3 minutes. The Infiltrant will be activated by slightly moving the applicator. Remove excess material with dental floss. Light-cure palatal side firstly, then labial side.

Fig. 8: Use ENA HRi esthetic restorative system (UD3+UE3) to fill enamel defects.

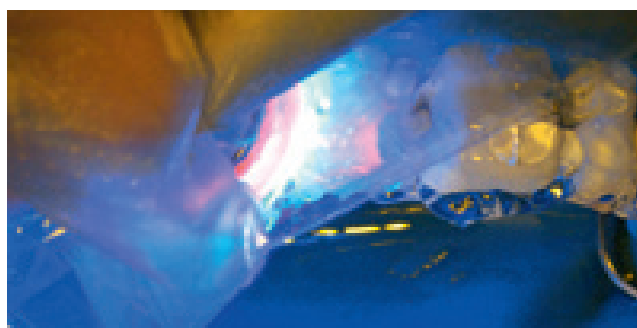


Fig. 9

Fig. 9: Screw a new Smooth Surface-Tip onto the Icon-Infiltrant syringe, repeat the application, and allow to set for 1 minute. Remove excess material with a cotton wad and dental floss. Apply Antioxidant and light-cure palatal side firstly, then labial side.

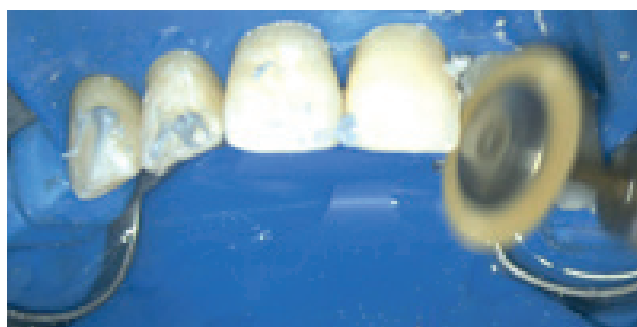

Fig. 10: Polish the teeth surface with wool polishing wheel and ENA SHINY A,B,C paste.

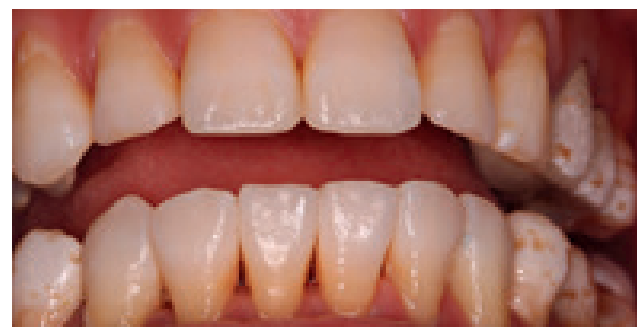


Fig. 11: Immediately after the removal of the rubber dam the esthetic of the upper anterior teeth are visible. The mandibular anterior teeth get the effective result with the same steps. Immediate postoperative esthetics.

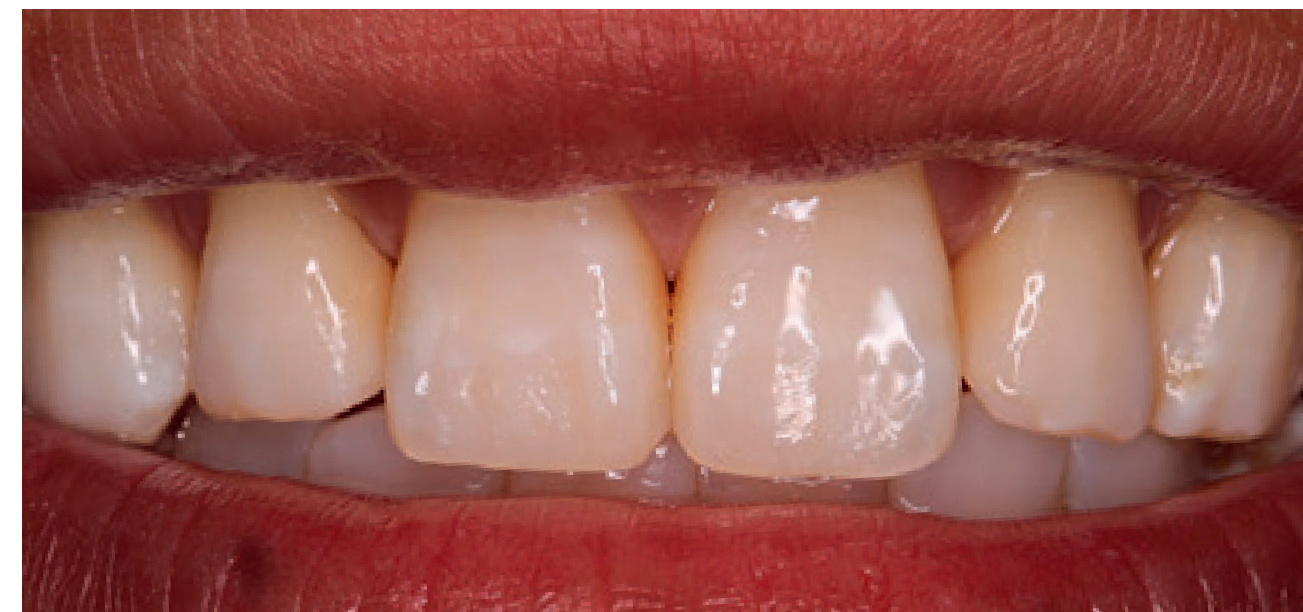

Fig. 12: Frontal view of the confident smile on her face!

Discussion

The clinical manifestation of dental fluorosis is that dental enamel developed in the same period has chalk spots or brown Spots. Severe dental fluorosis can accompany discoloration with defects. Discoloration can be treated with dental bleaching. Dental bleaching utilizes hydrogen peroxide or carbamide peroxide which can diffuse into the tooth and dissociate to produce unstable free radicals. Free radicals will attack organic pigmented molecules in the spaces between the inorganic salts in tooth enamel by attacking double bonds of chromophore molecules within tooth tissues [1, 2, 3]. The change in double-bond conjugation results in smaller, less heavily pigmented constituents, and there will be a shift in the absorption spectrum of chromophore molecules; thus, bleaching of tooth tissues occurs.

Enamel micro-abrasion works with the abrasive paste which is 6.6 % hydrochloric acid slurry that contains silicon carbide microparticles. Chemical corrosion and mechanical abrasion happen simultaneously in order to remove enamel defect and make enamel smooth and glossy. Compared with the invasive methods like porcelain laminate veneer and all-ceramic crown, enamel micro-abrasion can preserve more natural dental structure.

Resin infiltration technique is an alternative therapeutic approach, the principle of which is capillary siphoning, to prevent further progression of enamel lesions. This treatment aims to occlude the micro-porosities within the lesion body by infiltration with low-viscosity light-curing resins that have been optimized for rapid penetration into the porous enamel. Because the infiltrating resin's refractive index is closer to the natural enamel, it changes the lower refractive index of decalcified enamel, and makes the teeth bright. Therefore this treatment may be used not only to arrest enamel lesions but also to improve the esthetic appearance of anterior teeth.

Conclusion

Resin infiltrating combined with at-home bleaching and micro-abrasion can treat dental fluorosis effectively. Besides, it leads to minimal invasion on the dental hard tissue and is easy to apply. It can also save time and money for patient. In short, the infiltration technique is the first option for dental fluorosis patient.

Key Learnings

- The patient who suffers from severe fluorosis can be treated by Icon infiltration treatment effectively. It is normally combined with some of other treatments, for example: bleaching, microabrasion, composite restoration.
- Icon infiltration cannot eliminate the yellow or brown stain, therefore normally bleaching is necessary to be performed by the patient with severe fluorosis before infiltration treatment.
- Icon can provide a uniform background for the esthetic composite restoration.

References

- Dahl J.E., Pallesen U. Tooth bleaching – a critical review of the biological aspects. *Crit. Rev. Oral Biol. Med.* 2003; 14: 292–304.
- Joiner A. The bleaching of teeth: a review of the literature. *J. Dent.* 2006; 34:412-419.
- Minoux M., Serfaty R. Vital tooth bleaching: biologic adverse effects – a review. *Quintessence Int.* 2008;39: 645–659.

A noninvasive approach to treating white enamel lesions.

Dr. Alexander Aresdahl

Whether a patient has brown spots, white spots or both, I always recommend teeth whitening for 2-4 weeks before Icon smooth surface is used. In a few cases, when the brown spots are superficial, a white polishing stone can be used to remove brown staining before initiating treatment.

Transillumination: A good way to determine if a white spot is treatable or not with Icon is to use a light curing LED. Illuminate the enamel by placing the LED tip on the palatal side of the tooth structure and see if the white spot is translucent or completely opaque. If the white spot is opaque then the treatment is less likely to be successful and may need substance removal and composite treatment.

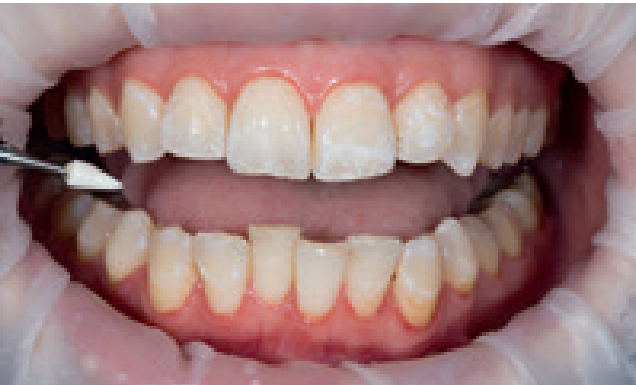

Fig. 1: Start by applying an optragate to get the patients lips out of the way. Then take a white polishing stone and gently polish the enamel surface for a few seconds to get rid of the superficial biofilm on the enamel surface.

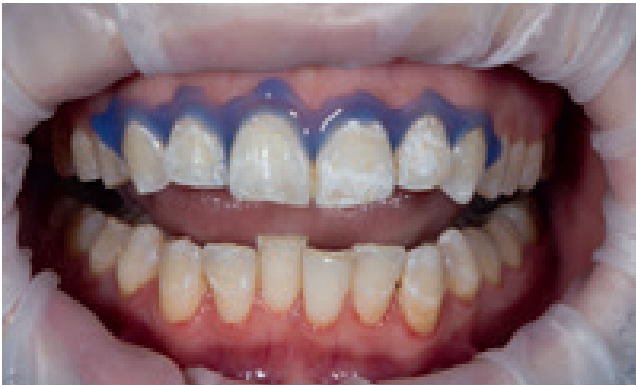

Fig. 2: Apply liquid rubber dam or classical endodontic rubber dam with ligatures to protect the gingiva.

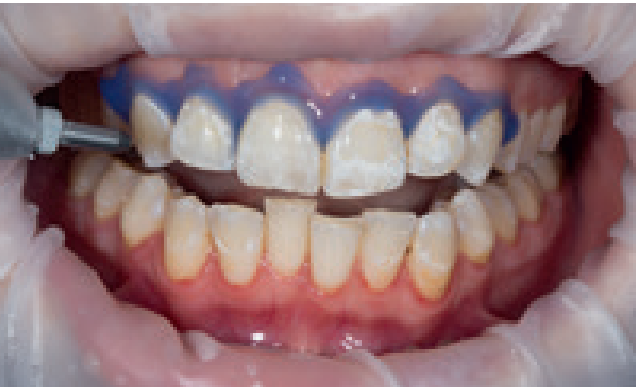

Fig. 3: Blast the white spots with white aluminiumoxide. This will enable better access to the body of the lesion. Blasting of the white lesions should only be done for 2-3 seconds and only once, with the blasting tip positioned approximately 1 cm from the enamel. After completion of this stage the white lesion should give away a matte appearance.

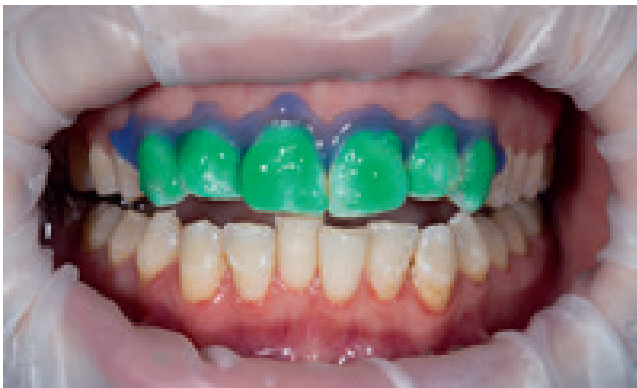

Fig. 4: Apply Icon-Etch over the white lesions and rub it gently for a few seconds with a dry tip until the etch loses its glide and gives away a foamy appearance. Let the Icon-Etch rest on the surface for 2 minutes and then rinse it off with water for at least 30 seconds.

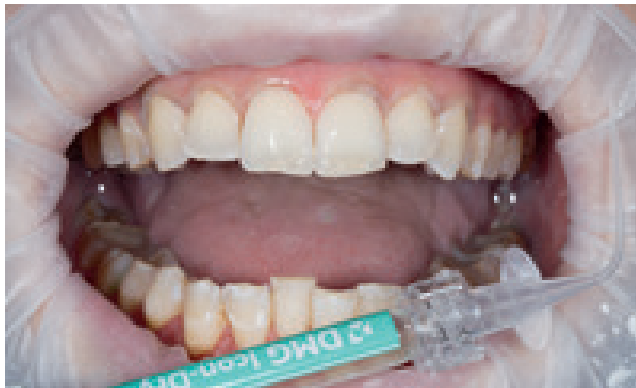

Fig. 5: After careful rinse of the tooth surface, dry with oil-free and water-free air. Then wet the white lesion with Icon-Dry. What you want to see is either a complete temporary masking/disappearance of the white lesion when wetted or a fluctuation in the white color of the lesion when wetted with Icon-Dry. This indicates that the lesion is now accessible for the Icon-Infiltrant.

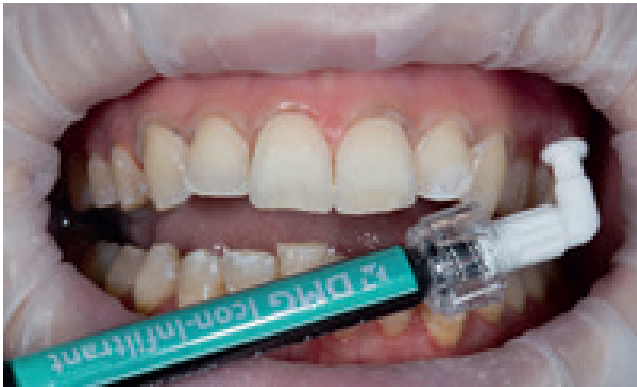

Fig. 6: When the white lesion has responded well to Icon-Dry it is time to use the Icon-Infiltrant. Take your chair attached lamp away from the patient's teeth and apply Icon-Infiltrant on a dry enamel surface. Use rich amounts. Let it then infiltrate the surface for 3 minutes. Carefully air-dry the surface followed by flossing then light cure for 40 seconds. Repeat the process a second time, but with only 1 minute infiltration time.

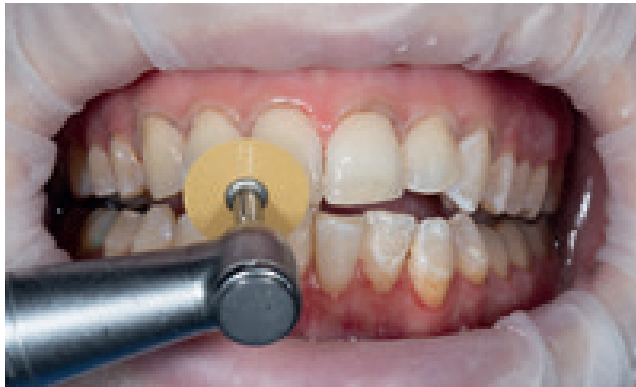

Fig. 7: After the Icon-Infiltration process the enamel surface will present a matte appearance. To get a shiny and smooth surface use 3M polishing discs. Start with a light orange disc on a dry surface and carefully polish away any unevenness. Moreover, rinse the surface with water, air blast and finish the polishing process by using a yellow disc.

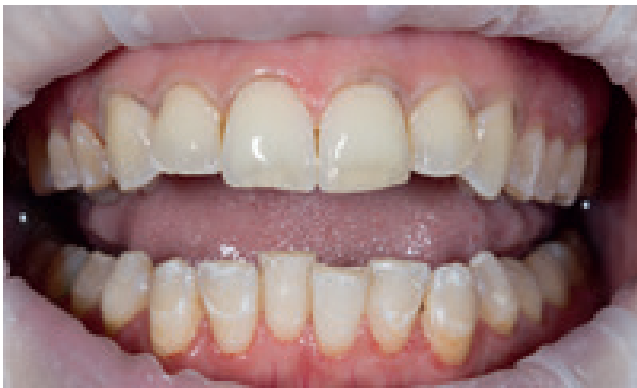

Fig. 8: Final result.

- Key Learnings**
- Make sure to rub the Icon-Etch properly onto the enamel.
 - Transillumination analysis pretreatment is a very good clinical indicator of whether you will need to remove tooth substance and use composite in addition to your treatment or if you can use Icon alone.
 - For optimal aesthetics use polishing discs to polish the matte surface after the treatment.

Masking Fluorotic Lesions with Icon.

Associate Prof. Dr. Giuseppe Allocca

Fluoride is one of the most important caries-preventive agents in dentistry [1]. Nevertheless a chronic exposure of too high fluoride intake during tooth development can lead to fluorotic spots on the tooth surface. Especially high concentrations of naturally occurring fluorides in drinking water seem to be the main cause for fluorosis [2]. Histologically, fluorotic enamel is characterized by hypomineralization, resulting in porosities of the tooth (sub-) surface [1, 3]. The appearance of these spots varies from opaque whitish to unsightly brown spots or even pitting, dependent on the duration and time point of high fluoride exposure during tooth development as well as patient related factors (e.g. patient's age or individual response) [2]. The main consequence of dental fluorosis is compromised esthetics [3]. Especially when front teeth are affected by dental fluorosis dentists often are confronted with the patient's demands of esthetic improvement as the appearance of these areas can be compromising. Treatment options include bleaching in case of mild forms, moderate forms of fluorosis can be treated with enamel microabrasion. Severe cases can require composite fillings or even veneers [2, 4]. Infiltration of these fluoride spots with Icon is an alternative treatment option to mask these compromising areas on the tooth surface. In young patients dentists might want to avoid dental bleaching as well as more invasive treatments. Icon is not only minimal- but microinvasive and can also be applied on young teeth. The low viscosity resin of Icon occludes the lesion porosities. As a result the lesions are masked [3].

Clinical case report

An eight year old male patient with whitish and chalky spots on his upper front teeth applied to our dental office with his mother. He was suffering from his classmates' mocking due to the appearance of his teeth 11 and 21. In addition to that his mother raised concerns about the chalky appearance of these spots when her child gets up in the morning. After detailed examination dental fluorosis was diagnosed and it was assumed that the reduction of saliva moistening of the patient's teeth during the night promotes the chalky effect in the

morning. In order to terminate the patient's psychological strain due to compromised esthetics we suggested an Icon treatment to mask the fluorotic lesions.

Discussion

Fluorotic spots can be a burden for patients as they often compromise esthetics. The clinical treatment goal of this kind of tooth discoloration should be achieving an acceptable esthetic result as conservatively as possible. Icon enables to mask these lesions in a microinvasive way as no mechanical enamel removal is required. The surface is just eroded with the Icon-Etch to get access to the

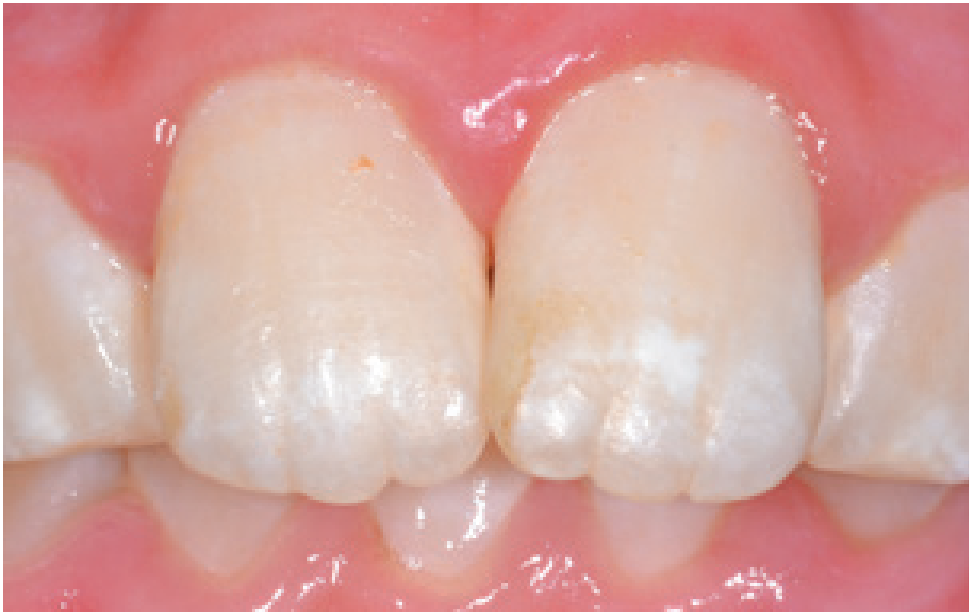

Fig. 1: Initial situation of the fluorotic spots before treatment with Icon. Especially the appearance of the teeth 21 and 11 were esthetically compromising.

lesion. Compared to microabrasion or conventional restorative treatment options Icon is less invasive. Furthermore the treatment time is shorter compared to other treatment options which can be an advantage in children with less compliance. Though in the same way as in some bleaching and enamel microabrasion techniques it has to be considered that the treatment result is dependent on the severity of the fluorotic spots. In some cases an improvement but not a completely masking of the spots can be achieved [3].

Conclusion

Treating fluorotic spots with Icon is a microinvasive, short and painless treatment option which improves esthetics and can be applied also in young patients.

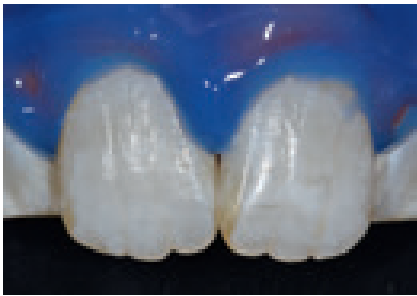


Fig. 2

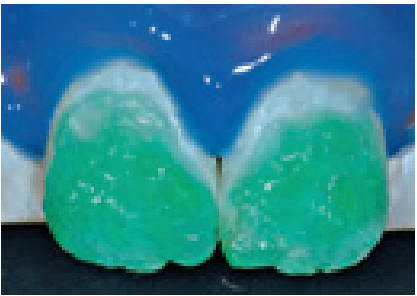


Fig. 3

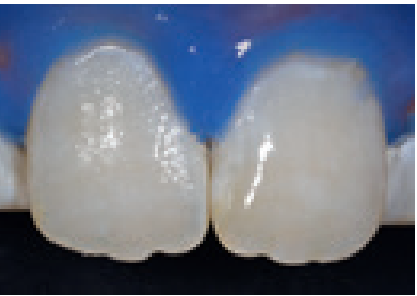


Fig. 4

Fig. 2: After polishing the teeth with pumice the resin barrier Opaldam Green (Ultradent®) was applied in order to isolate the working field and to protect the gingiva which both is mandatory when using Icon. Fig. 3: To condition the surface Icon-Etch was applied for 2 minutes. The etching gel was removed with water spray for 30 seconds and the surface was dried. The etching step was repeated 4 times. Especially with fluorosis it is often necessary to repeat the etching step several times to gain sufficient access to the lesion body. Fig. 4: In the next treatment step Icon-Dry was applied for 30 seconds. Immediately after the wetting with Icon-Dry the operator gets a preview of the masking effect. If the lesions do not diminish the etching step should be repeated. After 30 seconds the surfaces were thoroughly dried with oil free and water-free air.

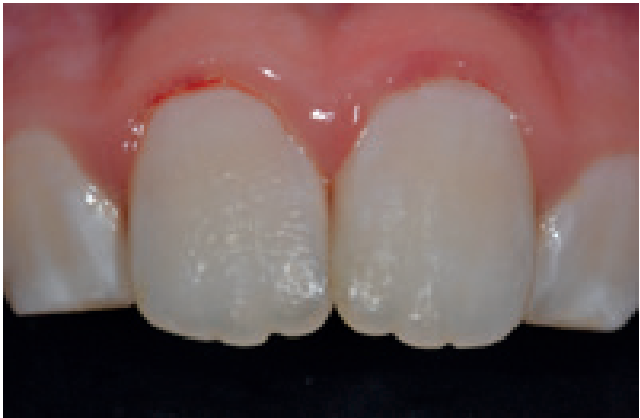

Fig. 5

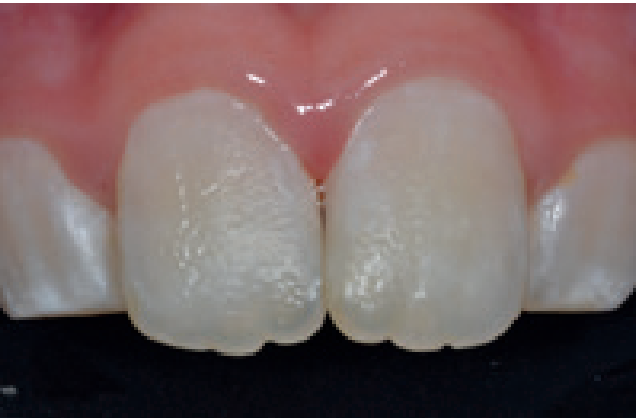

Fig. 6

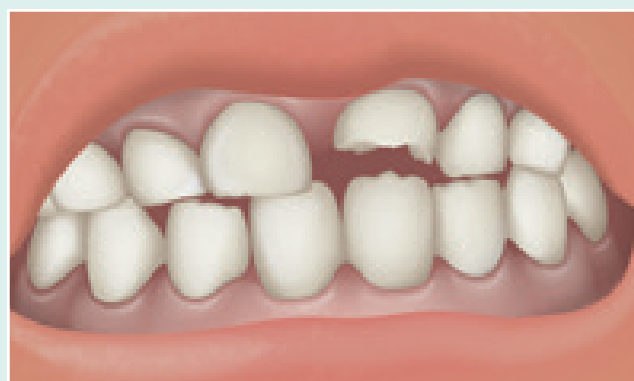

Fig. 5: Next Icon-Infiltrant was applied and it was set for 6 minutes because of severe fluorosis diagnosis. Excess material was removed with a cotton wad and dental floss before it was light cured for 40 s. This infiltrant step was repeated letting the infiltrant set again for 3 minutes before excess removal and light curing. Polishing was performed with Flairesse medium (DMG®) and Enamel Shiny Micerium polishing kit (Micerium s.r.l.). The fluorotic spots on both central front teeth are completely masked. Fig. 6: Clinical situation 3 months after Icon treatment. The situation is stable, the lesions on the teeth 21 and 11 are masked completely.

Key Learnings

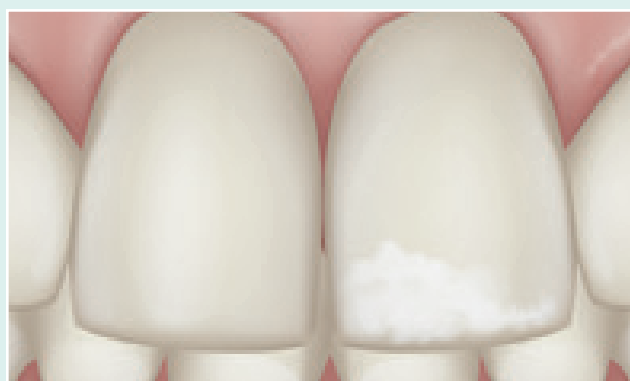
- Especially with fluorosis it is often necessary to repeat the etching step several times to gain sufficient access to the lesion body.
- Icon-Infiltrant can be set for 6 minutes because of severe fluorosis diagnosis.
- Icon Infiltration treatment can be also used for the permanent teeth for young children.

References

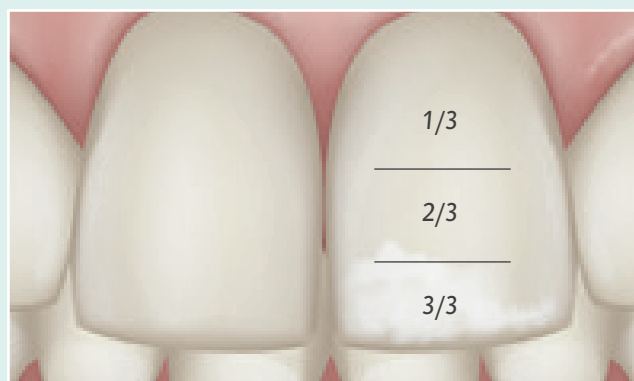
- Aoba T, Fejerskov O. Dental fluorosis: chemistry and biology. Critical reviews in oral biology and medicine : an official publication of the American Association of Oral Biologists. 2002;13(2):155-70.
- Gugnani N, Pandit IK, Goyal V, Gugnani S, Sharma J, Dogra S. Esthetic improvement of white spot lesions and non-pitted fluorosis using resin infiltration technique: series of four clinical cases. Journal of the Indian Society of Pedodontics and Preventive Dentistry. 2014;32(2):176-80.
- Munoz MA, Arana-Gordillo LA, Gomes GM, Gomes OM, Bombarda NH, Reis A, et al. Alternative esthetic management of fluorosis and hypoplasia stains: blending effect obtained with resin infiltration techniques. Journal of esthetic and restorative dentistry : official publication of the American Academy of Esthetic Dentistry [et al]. 2013;25(1):32-9.
- Cocco AR, Lund RG, Torre E, Martos J. Treatment of Fluorosis Spots Using a Resin Infiltration Technique: 14-month Follow-up. Operative dentistry. 2016;41(4):357-62.



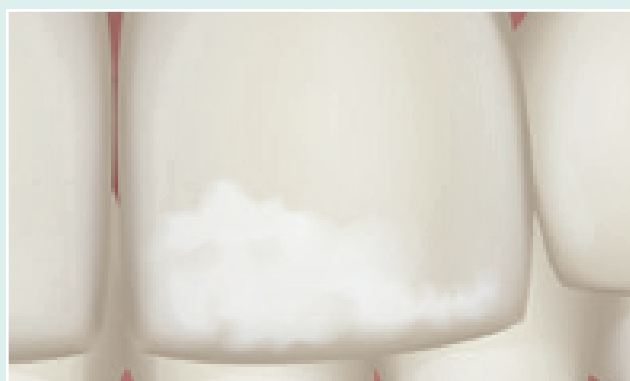
Patient history or etiology. A trauma or apical periodontitis in the primary tooth.



Affected tooth/teeth. Usually one or several teeth. Associated lesions can often be found on opposite jaw.



Localization. Mostly affects the facial surface (the side closer to the lips or cheek).



Border. Well-demarcated. It also could be a quantitative defect associated with reduced localized thickness of enamel (enamel hypoplasia).

Traumatic hypomineralisation.

Dental history and visual diagnosis.

Traumatic hypomineralization of a permanent tooth is a consequence of periodontal trauma affecting the deciduous teeth. Whatever the severity of this trauma, the appearance of sequellae is sporadic [1].

The prevalence of this hypomineralization is estimated as 5.2%. This figure is not surprising, given that one third of children suffer a traumatic episode involving their deciduous teeth before the age of 5.

The close anatomical proximity that exists between the apices of the anterior deciduous teeth and the germs of their permanent successors, which also display delayed calcification, explains this relationship.

Traumatic hypomineralization can present a wide variety of clinical expressions differing in shape, outline, localization and even color. They are generally punctiform lesions situated on the incisal half of tooth crowns. They are often limited to one

tooth, and asymmetrical with respect to the corresponding contralateral teeth. However, associated lesions can often be found on mandibular opponents.

The histopathology of traumatic hypomineralization is similar to that of WS and fluorosis. It involves also subsurface hypomineralization under a relatively well-mineralized surface layer.

Either superficial or deep erosion-infiltration works very well to treat traumatic hypomineralisation. [2].

Dr. Jean-Pierre Attal

References

1. Denis M, Atlan A, Vennat E, Tirlet G, Attal J-P. White defects on enamel: diagnosis and anatomopathology: two essential factors for proper treatment (part 1). Int Orthod Collège Eur Orthod. 2013 Jun;11(2):139–65.
2. Attal J-P, Atlan A, Denis M, Vennat E, Tirlet G. White spots on enamel: Treatment protocol by superficial or deep infiltration (part 2). Int Orthod Coll Eur Orthod. 2014 Feb 3;

Treatment of traumatic hypomineralized teeth.

Dr. Jean-Pierre Attal

Traumatic hypomineralization of a permanent tooth is a consequence of periodontal trauma affecting the deciduous teeth. Whatever the severity of this trauma, the appearance of sequelae is sporadic [1]. The prevalence of this hypomineralization is estimated as 5.2%. This figure is not surprising, given that one third of children suffer a traumatic episode involving their deciduous teeth before the age of 5. The close anatomical proximity between the apexes of the anterior deciduous teeth and the germs of their permanent successors could explain why the trauma can lead to the delayed calcification of the affected permanent tooth germs. Traumatic hypomineralization can present a wide variety of clinical expressions differing in shape, outline, localization and even color. They are generally punctiform lesions situated on the incisal half of tooth crowns. They are often limited to one tooth and asymmetrical. However, associated lesions can often be found on opposite jaw. The histopathology of traumatic hypomineralization is similar to that of white spots and fluorosis. It involves subsurface hypomineralization under a relatively well-mineralized surface layer. The erosion/infiltration treatment works very well, either superficial or deep infiltration [2].

Clinical case report

A 25 years old lady would like to mask the two lesions on the central incisors. The diagnosis is almost easy: MIH was excluded because there are no lesions on first molars; fluorosis and incipient caries are also excluded according to clinical expressions. In the end traumatic hypomineralization was diagnosed. One hour treatment is planned to treat the two lesions.

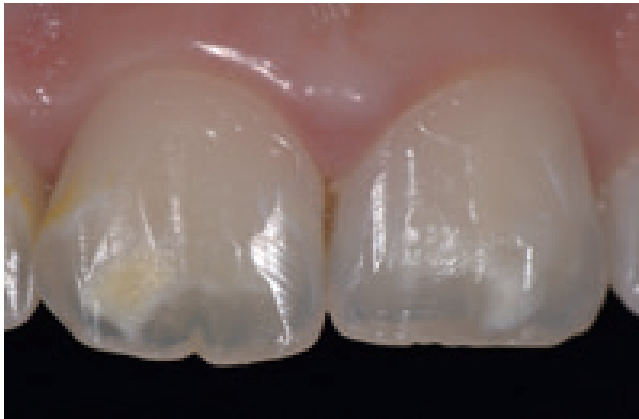


Fig. 1: Initial situation with two lesions due to trauma on teeth 11 and 21 (white lesion on 21 and slightly yellow on 11). The third incisal portion of teeth is concerned with a high translucency of the edge. As the lesion appears relatively deep, we know that we need to infiltrate in depth. So we eliminate a very thin layer of enamel with the bur.

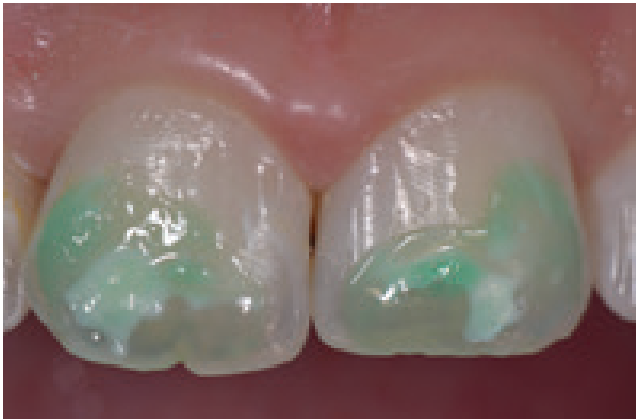

Fig. 2: First application of Icon-Etch.

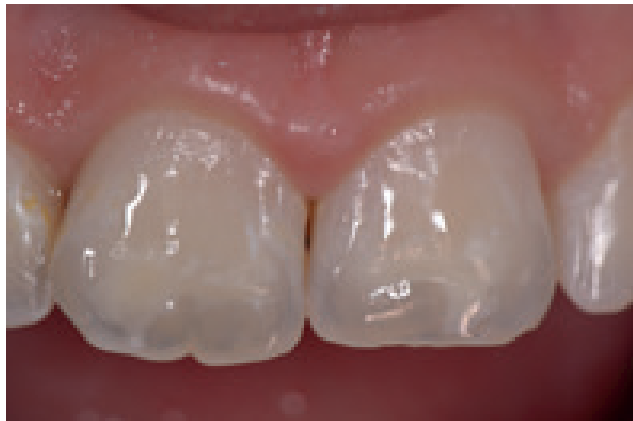

Fig. 3: After rinsing, drying and application of Icon-Dry, we note a slight masking of the lesions. But not enough to infiltrate.

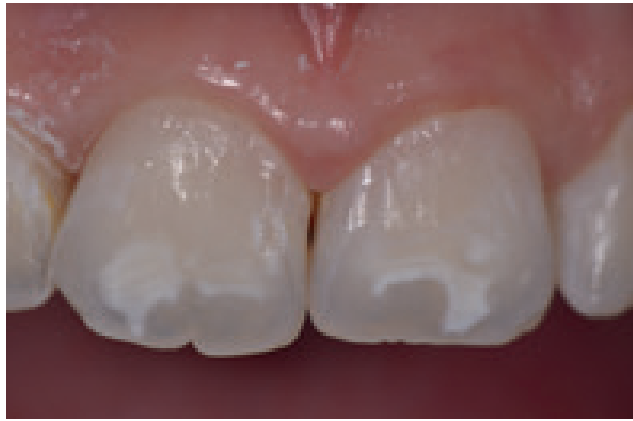

Fig. 5: After rinsing and drying.

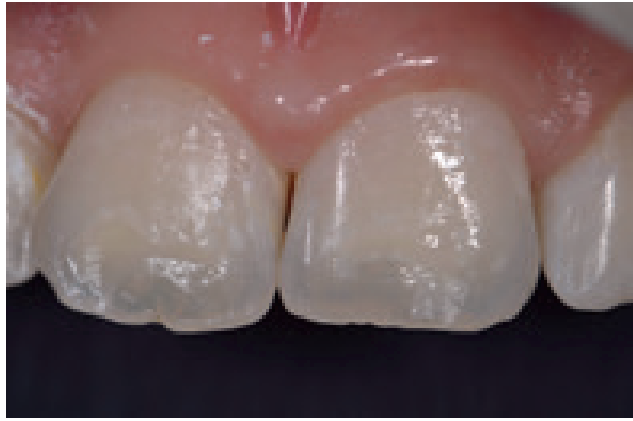

Fig. 7: After infiltration with Icon-Infiltrant and light curing. The masking is efficient.

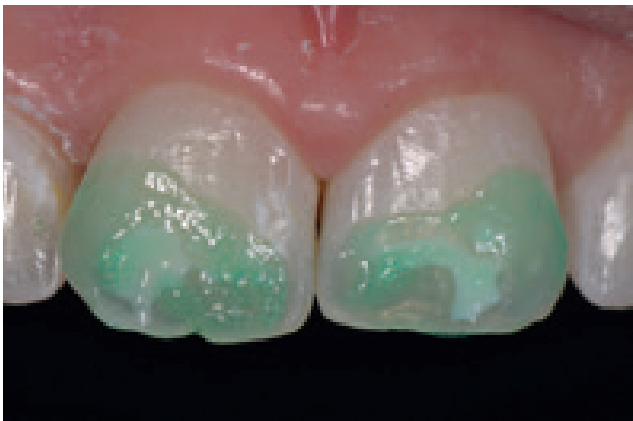

Fig. 4: Second application of Icon-Etch.

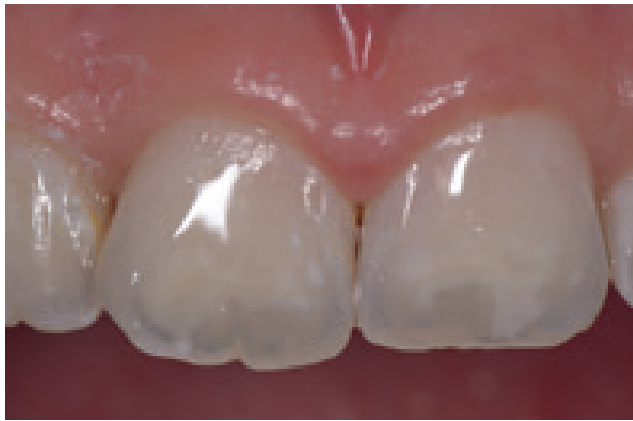

Fig. 6: Icon-Dry allows a partial masking of the lesion. That shows that ethanol can infiltrate the porous lesion. We know that Icon-Infiltrant could infiltrate too.

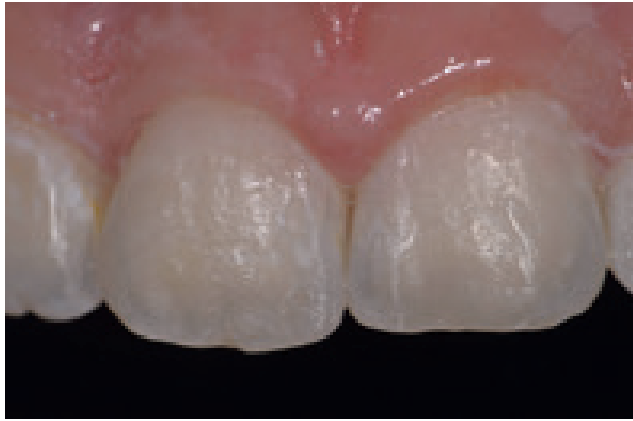

Fig. 8: A small amount of enamel composite is sufficient to compensate the very small loss of substance of enamel due to the combination of bur and acid erosion. The lesions are not visible anymore.

Key Learnings

- For deep traumatic hypomineralization, you have almost always to do a deep infiltration. So you need to sandblast or to drill.
- Never infiltrate the lesion unless you have a clear modification with Icon-Dry after the rinsing of Icon-Etch.

References

- Denis M, Atlan A, Vennat E, Tirlat G, Attal J-P. White defects on enamel: diagnosis and anatomopathology: two essential factors for proper treatment (part 1). Int Orthod Collège Eur Orthod. 2013 Jun;11(2):139-65.
- Attal J-P, Atlan A, Denis M, Vennat E, Tirlat G. White spots on enamel: Treatment protocol by superficial or deep infiltration (part 2). Int Orthod Coll Eur Orthod. 2014 Feb 3.

Non-Invasive treatment of enamel hypomineralizations with Icon.

Prof. Dr. Zafer Cehreli

In daily practice, developmental enamel defects are being more frequently seen in young patients. The management of such enamel lesions depends on the type and severity of defect, and minor lesions are often treated by bleaching, microabrasion or conservative resin-based restorations. Resin infiltration was originally developed for the non-invasive treatment of initial proximal carious lesions and post-orthodontic white spot lesions, but its esthetic masking effect by taking on the appearance of the surrounding enamel has introduced new possibilities for the non-invasive esthetic management of a variety of developmental enamel defects including enamel hypomineralizations. This is of particular importance, because hypomineralized enamel is resistant to conventional acid etching, which may lead to poor micromechanical adhesion and subsequent microleakage when such lesions need to be treated with resin-based composites. On the other hand, microabrasion may lead to some tissue loss at the surface layer, which often needs to be restored with composite resin.

Icon can mask small, white developmental defects by infiltrating into the pores with a resin that has a refractive index close to that of the surrounding sound enamel. The masking effect is immediate, and in most cases dramatic. Esthetic improvements are even observed in teeth with incomplete resin penetration. The Icon system utilizes 15 % hydrochloric acid to open the pores within the lesions, thereby facilitating penetration of the resin infiltrant. Even after repeated applications of hydrochloric acid, the enamel removed from the surface is almost negligible, resulting in a truly non-invasive, ultraconservative esthetic treatment.

The following case is a typical example of small, shallow hypomineralization lesions. The patient seeks esthetics, while the parents demand a non-restorative solution.

Fig. 1: A 9-Year-old girl with hypomineralization lesions on central and lateral incisors. The patient is more concerned with the lesions on central incisors. The parents do not prefer restorative treatment.

Fig. 2: View of the lesions under cross-polarization filter, which eliminates highlights that mask the opacities, and thus provide a better appreciation of the borders of the lesions.

Fig. 3: Isolation of affected teeth after cleaning of surfaces with fluoride free pumice and rotary rubber cup at slow speed. Before placement of the rubber dam, the gingiva should be isolated with Vaseline to ensure protection. The borders of the lesions can be better appreciated after dehydration. Tooth no 11 has well defined borders, while 21 has diffuse hypomineralizations. The lesion on 11 appears to be a deeper than its neighbor, suggesting that additional etching may be necessary. **Fig. 4:** The hydrochloric acid gel is applied on the lesions and allowed to sit for 2 minutes. **Fig. 5:** All tooth surfaces should be thoroughly washed with air-water spray for at least 30s and the teeth should be dried meticulously with oil-free compressed air. **Fig. 6:** Icon-Dry is absolute ethanol, and is applied to dry the pores within the lesions. Icon-Dry has a second important function of providing a preview image of the final appearance after infiltration. To achieve best results, the ethanol should stay on tooth surfaces for at least 30 seconds. Here the lesion on tooth 21 appears to be masked satisfactorily, while the lesion on 11 suggests that an additional etching step will be necessary.

Fig. 7: This time, the Icon-Etch is applied only on tooth 11 for 2 minutes.

Fig. 8: Again, the tooth is rinsed for at least 30 seconds with air-water spray.

Fig. 9: Dry with oil-free and water-free air. There is no visible change. However, a decision can only be made after the application of Icon-Dry.

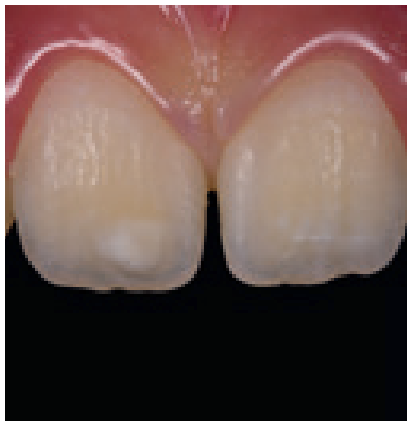

Fig. 1

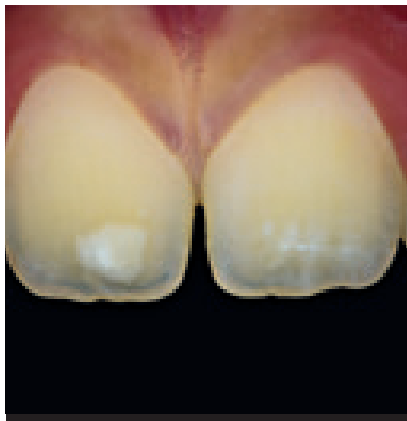


Fig. 2

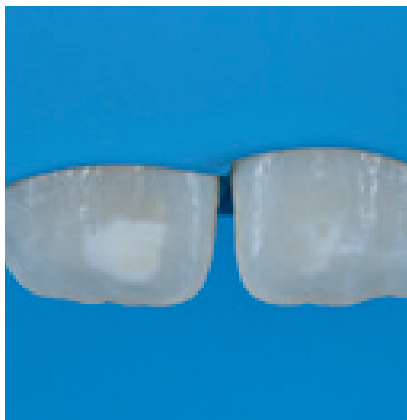

Fig. 3




Fig. 4

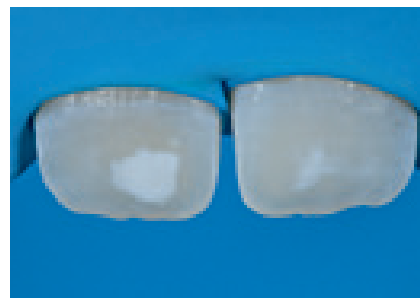

Fig. 5

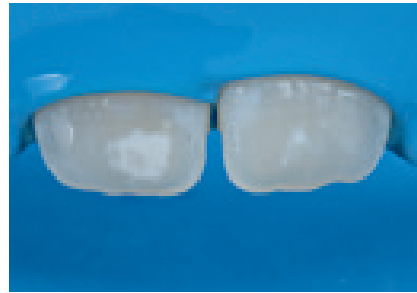


Fig. 6



Fig. 7

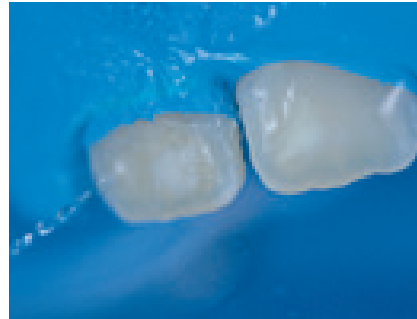

Fig. 8

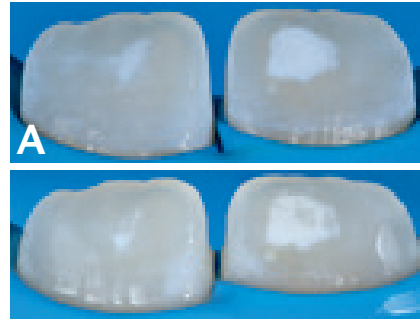

Fig. 9

Following a 30-second application of absolute ethanol, the lesion on tooth 11 appears to be masked well. A comparison of the first (A) and second (B) rounds of Icon-Dry applications. For each step, the upper photo shows the dried lesion and the lower one shows the dramatic masking effect created by absolute ethanol. After two rounds of etching and drying, it is evident that an additional etching step will not be required.

Fig. 10: Application of the Icon-Infiltrant. An ample amount of Icon-Infiltrant should be introduced onto the lesion site and should sit for 3 minutes with the operatory light turned off.

Excess resin should be removed from the surface with gauze and the teeth should be exposed to curing light for 40 seconds each. Then the Icon-Infiltrant should be applied



Fig. 10

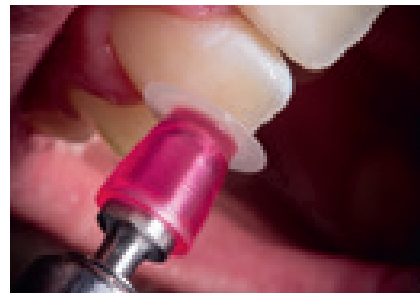


Fig. 11

as a second layer for at least 1 minute and subsequently light-cured as with the first layer. It is always beneficial to perform a final round of light curing with the tooth surfaces covered with glycerine gel to prevent oxygen inhibited surface layer.

Fig. 11: Excess resin should be gently removed using slow speed disks or rubber cups, leaving a polished enamel surface.

Fig. 12: Immediate post-operative view showing the total masking effect.

Under cross polarization, the borders of the lesions are invisible and there is excellent color match. In this patient, the esthetics was reestablished without the need to treat the laterals. A comparison of preoperative (A) and post-operative images (B) showing the masking effect achieved with a non-invasive treatment approach. For each image set, the upper photo shows the actual result, and the lower one shows the lesion under cross-polarization filter.

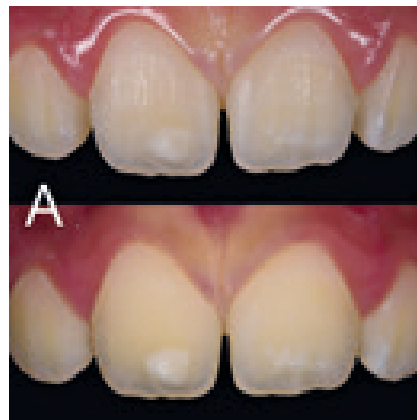
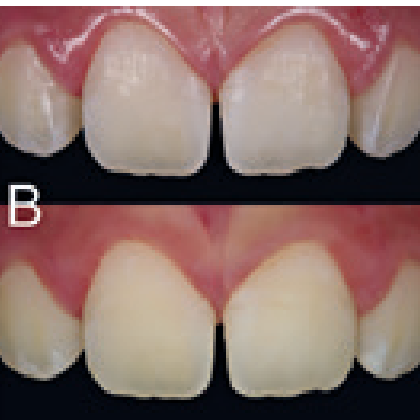


Fig. 12



Resin-infiltration procedure of white spots.

Dr. Erik-Jan Muts

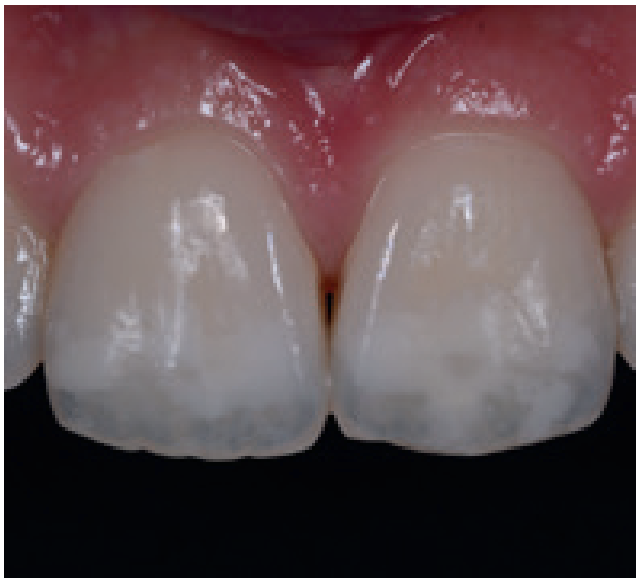

Fig. 1: Initial situation. With a black background the contrast gets better, but the white spots is still not clear. Britt is dissatisfied with the white spots on teeth 12, 11 and 21.

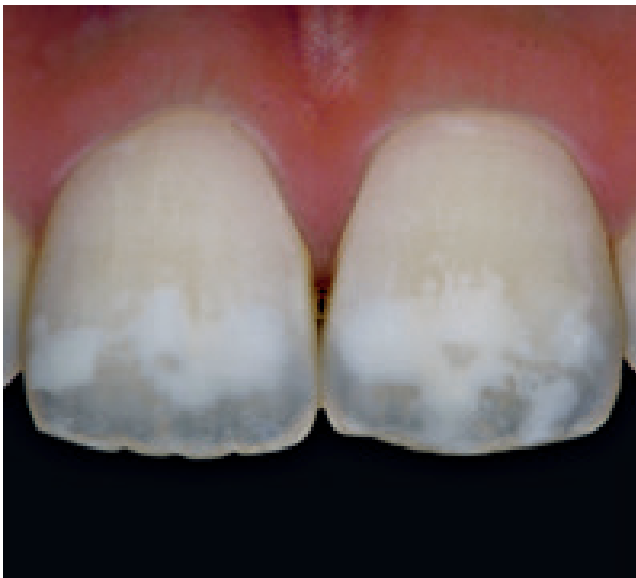

Fig. 2: A cross-polarised photo with high colour intensity of the initial situation. In a sudden the white spots are clearly visible.

White spots present on the front teeth can esthetically be very unpleasant for the patient. To prevent the start of a restorative cycle, invasive treatment with composite or porcelain veneers is not advised. The removal of »healthy« enamel may weaken the tooth and may cause problems later on in life.

Using a resin-infiltration technique the porosities inside the enamel, causing the white spots, can be infiltrated and filled with resin. This way we are nowadays able to treat white spots non-invasively with very good and long lasting results.

Initial status

Britt (22 years old) was looking for minimal invasive treatment to remove the white spots on her front teeth (12, 11 and 21). I decided to make some pictures.

A cross-polarized picture with high color intensity gives a lot of information because all the scattering from the flashlights is filtered away and differences between colours are more intense. Explaining the situation and the possibilities with resin-infiltration techniques, Britt was convinced and went for the treatment.

There was no need for bleaching prior to the treatment.

Micro-abrasion

First of all rubberdam (Optradam, Ivoclar Vivadent) is placed to get a clear and dry work field. Rubberdam is obligatory in these kinds of cases. Next we perform micro-abrasion using a micro-abrasive paste (Opalustre, Ultradent) to clean the surface and to start opening the porosities. It is applied three times for 60 seconds each, in between excessive rinsing is important. Instead of using a special micro-abrasive paste, the 15% hydrochloride acid (Icon-Etch, DMG) can also be mixed with some pumice and rubbed with a special rubber cup using gentle forces.

Etching

Then neighbouring teeth are isolated with Teflon tape and the etching procedure with hydrochloric acid (Icon-Etch, DMG) starts. The etching is done with a rubbing motion using the special smooth surface (sponge) tip for two minutes.

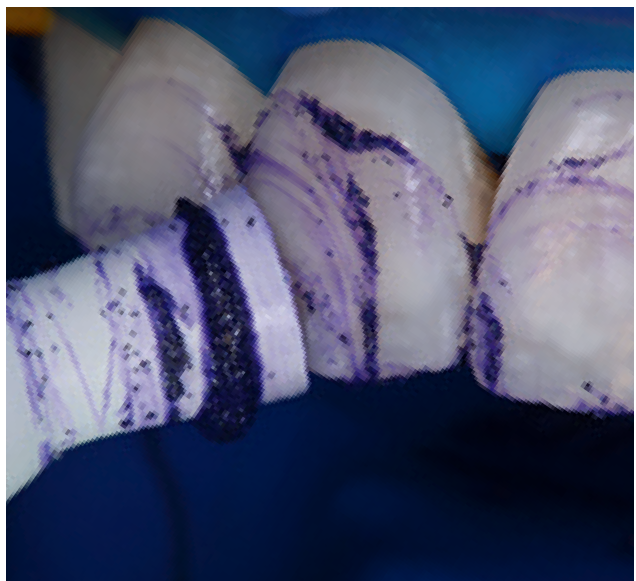

Fig. 3: Application of a micro-abrasive paste with a special rubber cup (Opalustre, Ultradent).

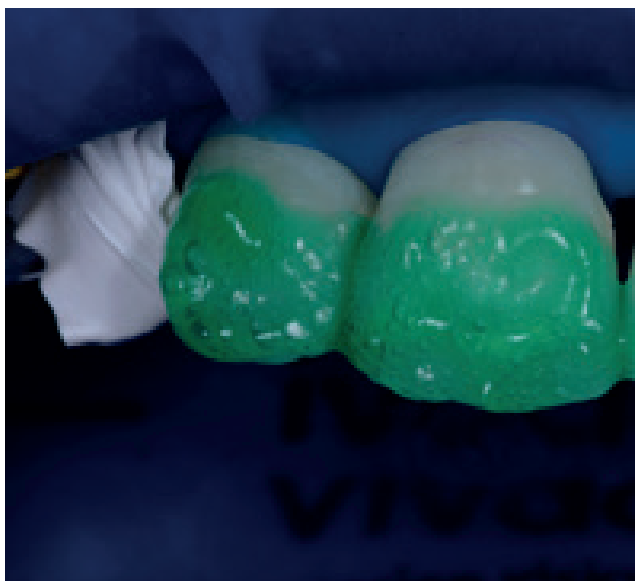

Fig. 4: Application of hydrochloric acid (Icon-Etch, DMG) and the isolation of neighbouring teeth with Teflon.

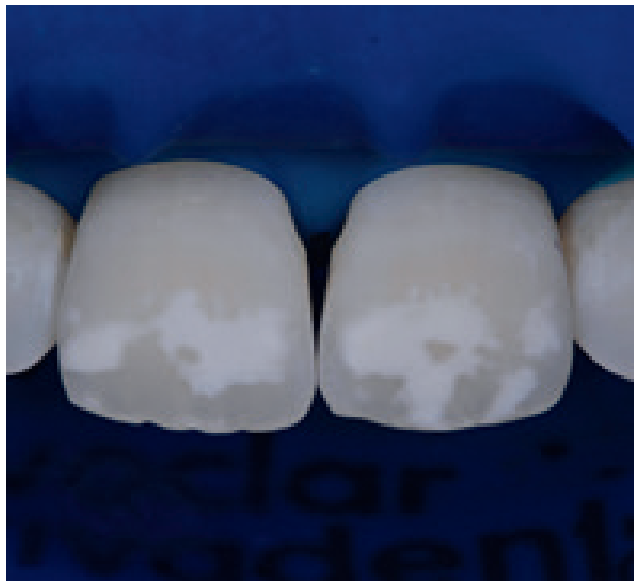

Fig. 5: Result after etching three times for two minutes.

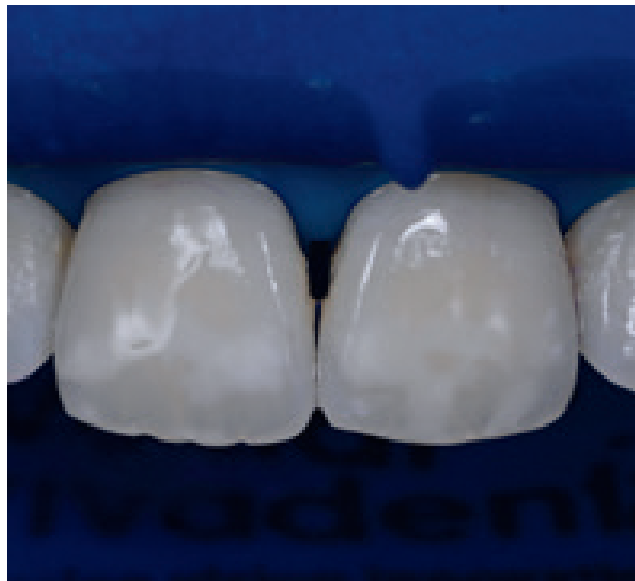

Fig. 6: Application of 99 % ethanol (Icon-Dry, DMG) shows the patency to the porosities. One more etching procedure was performed after this result.

After a lot of rinsing the white spots become even more visible. This means the porosities are getting better accessible. A check can be performed with the absorption of ethanol (Icon-Dry, DMG). Once the white spots disappear after application of ethanol, the enamel is ready to be infiltrated. If not, the etching procedure is repeated, with a maximum of five repetitions total.

Infiltration

After the white spots disappear with the application of ethanol (Icon-Dry, DMG), it is time to infiltrated with the methacrylate (Icon-Infiltrant, DMG). Infiltration is also done with the special smooth surface tip.

Notice that there is no direct light on the working surface, since this may polarize the methacrylate particles preventing them to

infiltrate further. Capillary forces suck the methacrylate (Icon-Infiltrant, DMG) into the enamel, filling up the porosities. This may take a while and it is advised (DMG) to wait at least 3 minutes. In my experience it might even infiltrate further while waiting longer and I would advise to wait at least 6 minutes. Polymerisation can be performed for 40 seconds after removing the excess with air.

This infiltration procedure should be repeated for 1 to 2 minutes and light cured as well. After light curing glycerine gel is applied and polymerised again for 40 seconds to remove the oxygen inhibition layer.

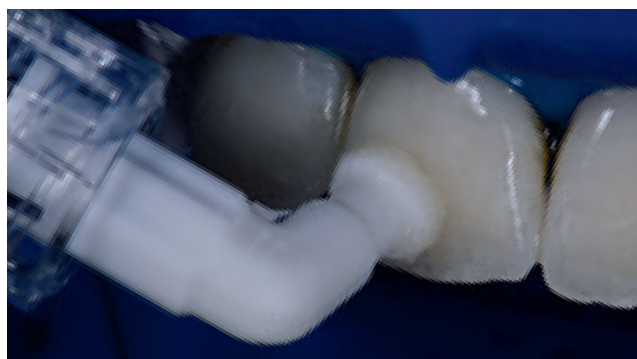


Fig. 7: Applying the methacrylate infiltrant (Icon-Infiltrant, DMG) with the special smooth surface (sponge) tip from DMG. Infiltrating the porosities with the infiltrant (Icon-Infiltrant, DMG). Polymerisation with glycerine gel is performed to remove the surface oxygen inhibition layer.

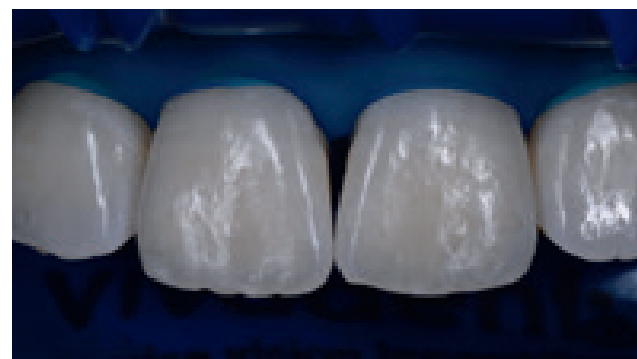

Fig. 8: Situation after polishing with rubbers (Brownie and Greenie, Shofu) and felt disc with aluminium oxide (Flexibuff with Enamelize, Cosmedent).

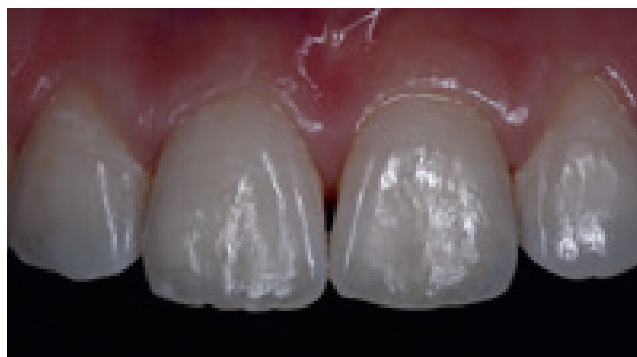

Fig. 9: Result immediately after treatment. The flashlight is scattering over the enamel surface, making it difficult to evaluate the result after treatment.

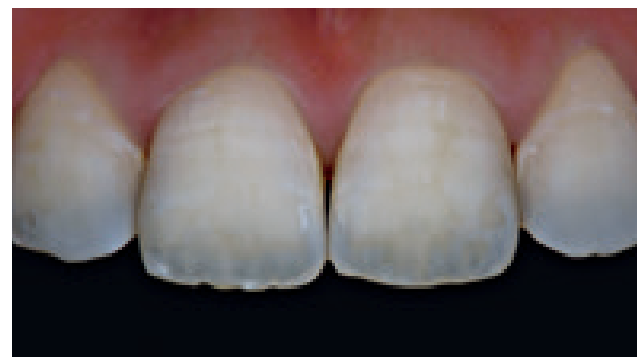

Fig. 10: Cross-polarized photo of the initial result. There is clearly a lot of improvement compared with the initial situation. The white spots are gone!

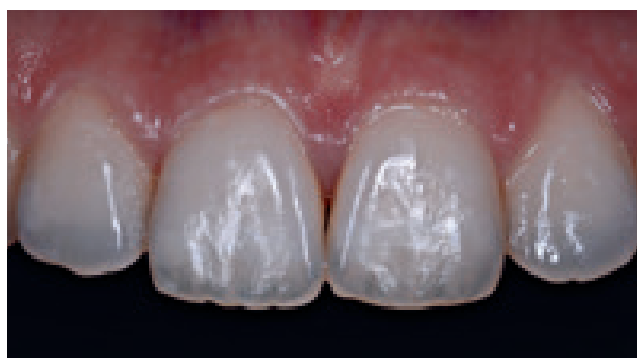


Fig. 11: Result after 1 year seems to be very stable.

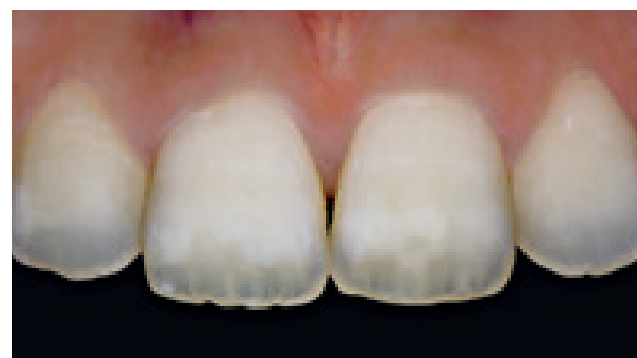

Fig. 12: Cross-polarized record shows a very stable and satisfying result after 1 year of treatment.

Polishing

After removal of the excess with scalers and dental floss the surface is polished with rubbers. First using a brownie (Brownie, Shofu), followed by a greenie (Greenie, Shofu) and a felt disc (Flexibuff, Cosmedent) with aluminium oxide paste (Enamelize, Cosmedent).

Evaluation

Immediately after treatment the initial result is evaluated. The white spots on the 12, 11 and 21 are completely removed and Britt is enormously happy. During and after treatment there was no sensitivity or adverse reaction of any kind. One year later I evaluated the treatment again and the result seems to be very stable. The resin-infiltration technique is a very useful and successful technique in esthetically compromised white spot cases.

Key Learnings

- With the help of Teflon it is easy to get the isolation of neighbouring teeth.
- In infiltration step, please make sure that there is no direct light on the working surface, since this may polarize the methacrylate particles preventing them to infiltrate further.
- Capillary forces suck the nano-methacrylate (Icon-Infiltrant, DMG) into the enamel, filling up the porosities. Please wait at least 3 min. or even longer to make the infiltration process complete.

Minimally invasive approach in the treatment of enamel white spot lesions due to traumatic injuries of primary tooth: a clinical case.

Dr. Ali Salehi

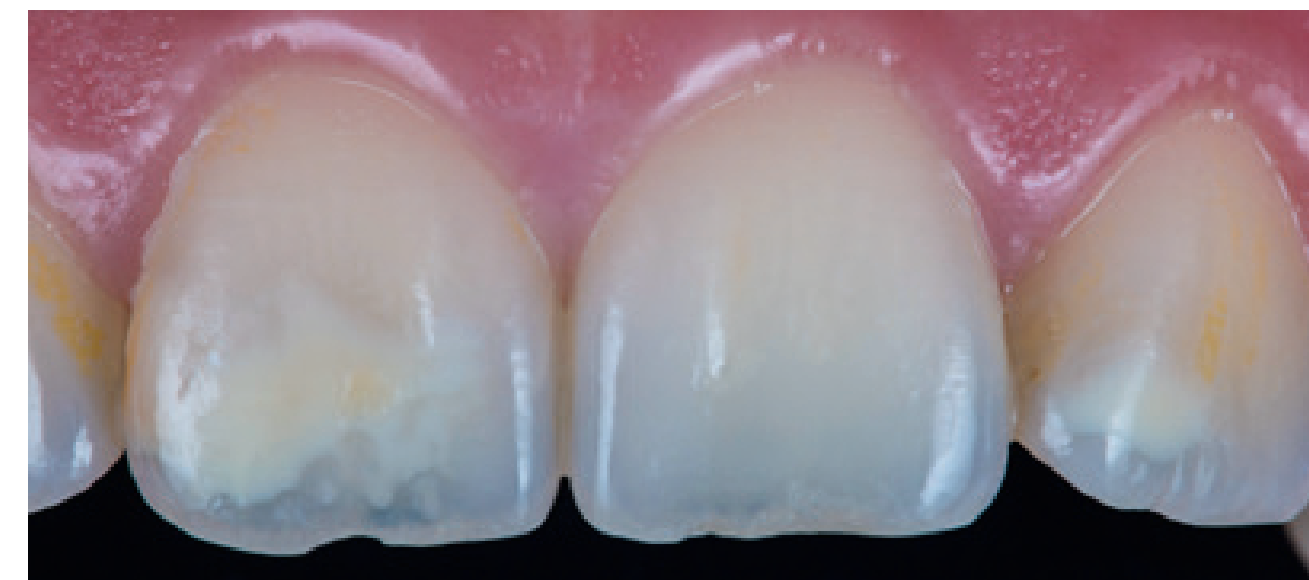

Fig. 1: Initial situation with large white spots on the incisal half of 11 and 22. Patient experienced trauma on primary incisors at the age of 4. The history, shape, location, asymmetry and absence of similar lesions on the other teeth indicate the diagnosis of post traumatic white spots. The opaquer areas of the white spots indicate deeper parts of the lesion that will require a deeper treatment.

Abstract

Hypomineralization in the permanent dentition could be a consequence of traumatic injuries of primary teeth happening at children's early years of life during learning to walk and exploring the environment. This sequela is the consequence of periodontal trauma affecting the deciduous teeth [1, 2]. The proximity of these two dentitions explains why not only a severe infection but also a slight inflammation around the periapical of a primary tooth could disturb the maturation of the ameloblasts, which leads to the appearance of traumatic hypomineralization.

Diagnosis is not easy as the lesion can present a wide variety of clinical expressions differing in shape, outline, localization and color. They are generally punctiforms, which are on the incisal third of tooth crowns, limited to one tooth and asymmetrical. Associated lesions can often be found on opposite jaw which is a pathognomonic sign for post traumatic hypomineralization.

Diagnosis is important because it will give an indication on how deep we need to go to reach the body of lesion before we infiltrate. In this case the histology is similar to white spots and fluorosis as the

lesion is usually close to a well mineralized enamel surface layer [3], which is the result of post-eruptive ionic precipitation. In some cases, the lesion can be deeper. The severity of the opacity of the lesion can indicate whether we are facing a really deep lesion or a relative superficial one.

On a microscopic scale, like any white spot lesions we are facing the enlargements of the interprismatic sheath creating the impression of gaps which are not present in healthy enamel. The presences of numerous gaps deviate the trajectory of the lightrays, which is responsible for the white appearance of the lesion. Erosion step before infiltration will attack the thin layer of well mineralized enamel that acts like a barrier and make the lesion accessible for the infiltration [4]. Infiltration will then be possible in the whole lesion to fill the gaps. The infiltrant's reflexion index is close to the one of healthy enamel, therefore the light rays will keep the same trajectory as in normal enamel, thus the white spots disappear.

However, for post-traumatic hypomineralization, the edges of the lesion can have acute or obtuse angle [3, 5].

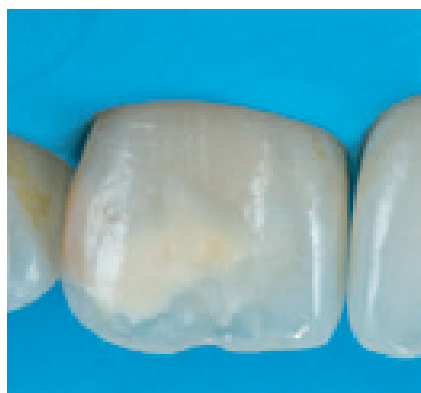

Fig. 2

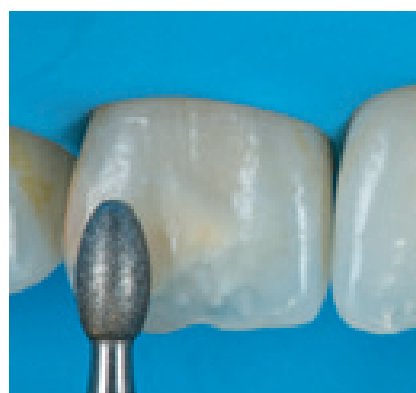

Fig. 3

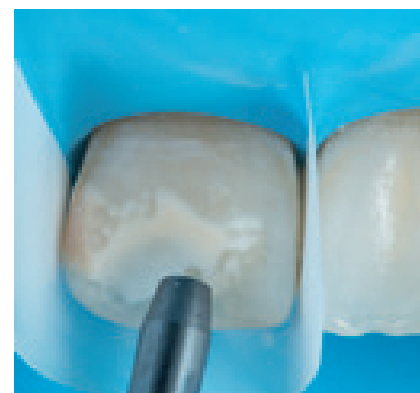

Fig. 4

Fig. 2: Rubber dam placement after having chosen the color of the composite that will be needed after the erosion-infiltration steps.

Fig. 3: The depth of the lesions indicates a thicker well-mineralized surface layer that needs more than just acid erosion in order to access the body of the lesion for infiltration. To accelerate the process and reach good final result, a red ring bur is delicately used on the surface layer prior to the acid. **Fig. 4:** Prior to each etching step, the surface layer is sandblasted as well as the healthy enamel surrounding the white spots to optimize the result and limit the »edge effect« due to an insufficient infiltration of the margin of the lesion.

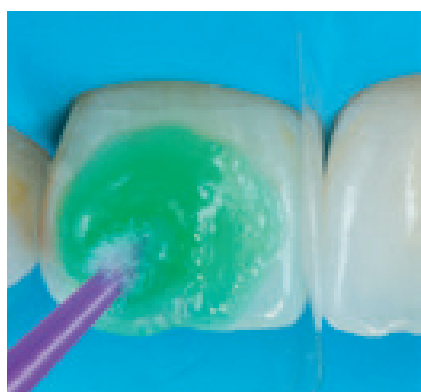

Fig. 5

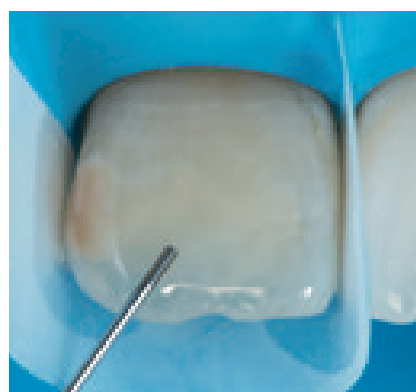

Fig. 6

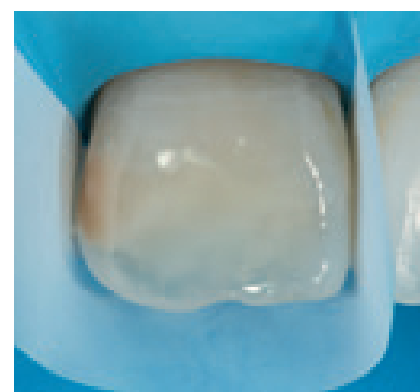

Fig. 7

Fig. 5: Icon-Etch is applied for 2 min and repeated 4 times because Icon-Dry did not give satisfied masking results of the white spots.

Fig. 6 and 7: After several steps alternating mechanical and chemical erosion, the use of Icon-Dry finally shows a satisfied result with a dramatical masking of the white lesions.

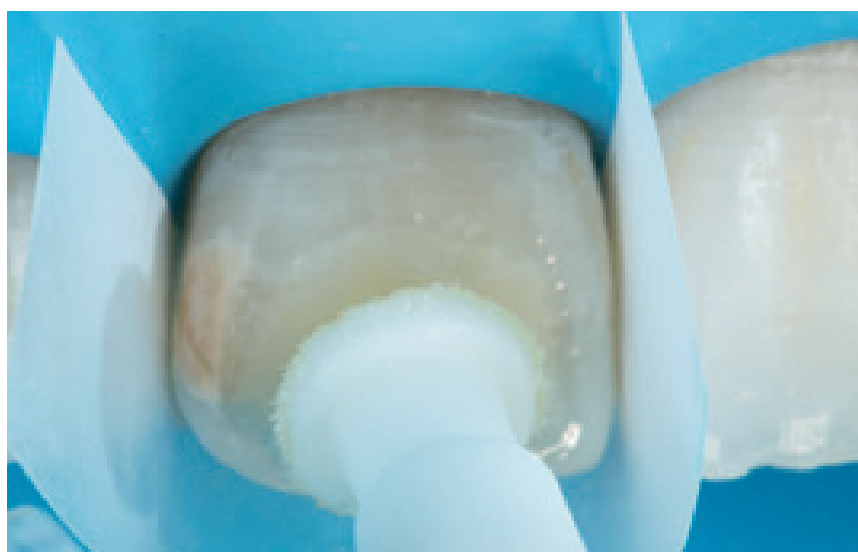

Fig. 8

In case of obtuse angles like in white spots and fluorosis the erosion stage is effective to get a complete infiltration in the entire hypomineralized area and make the spot totally disappear.

In case of acute angles, the infiltration could be incomplete on the margins where the contours of the lesion could be still visible after treatment. We are able to eliminate the thin relatively well-mineralized surface layer by erosion, but only the central part of the lesion will be accessible to the infiltrant, while on the edges of the lesion, erosion alone cannot remove the peripheral healthy enamel, which will make resin infiltration not effective on the edges of the lesion. As a result, the center of the spot disappears while a more or less homogeneous white outline remains. This result is sometimes unsightly than the spot itself.




Fig. 9

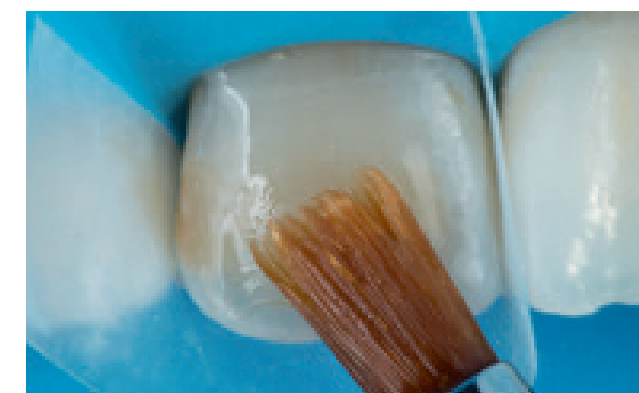

Fig. 10

Fig. 8, 9 and 10: Apply the Icon-Infiltrant for 3 min and then light curing; followed by the application of Icon-Infiltrant for another 1 min and light curing again. To restore the morphology of the vestibular surface after the deep infiltration, a thin layer of enamel composite (Dark Enamel Essentia®, GC) is applied, light cured and polished.

In order to improve the effectiveness of erosion-infiltration treatment in all situations of traumatic hypomineralization, light sandblasting can be done to increase the peripheral erosion.

Conclusion

In order to perform a treatment that can balance the effectiveness and minimal invasive approach, a proper diagnosis of the lesion prior to any kinds of treatment is important. Depending on the etiology of the lesion we can have an idea of its shape and depth.

It will help us to know if the good final outcome needs a superficial or deeper erosion-infiltration treatment. The latter will always need some composite to restore its initial morphology at the end of the treatment.

Key Learnings

For post-traumatic hypomineralization, the edges of the lesion can have acute or obtuse angle. In case of acute angles, the infiltration could be incomplete on the margins where the contours of the lesion could be still visible after treatment.

A proper diagnosis of the lesion prior to any kinds of treatment is important. Depending on the etiology of the lesion we can have an idea of its shape and depth, accordingly we can decide superficial or deeper erosion-infiltration treatment should be performed.

The combination of sandblasting, Icon infiltration and enamel composite restoration can achieve good esthetic result for traumatic white spot lesions.

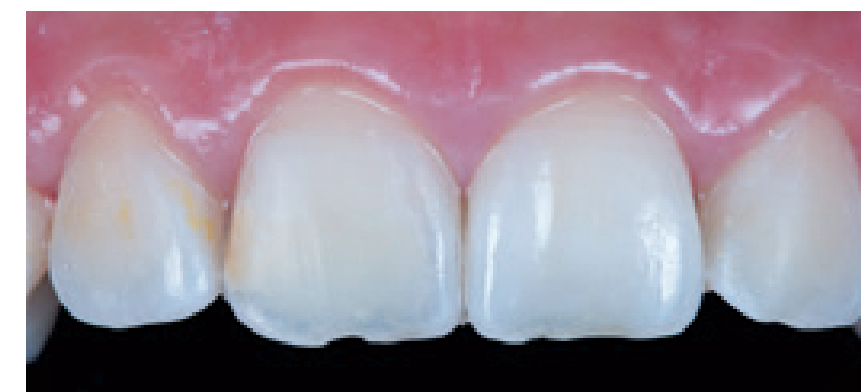

Fig. 11: Final situation one year after the treatment show an amazing stability of the infiltration result.

References

- Bardellini E, Amadori F, Pasini S, Majorana A. Dental Anomalies in Permanent Teeth after Trauma in Primary Dentition. *The Journal of clinical pediatric dentistry*. 2017;41(1):5-9.
- Caprioglio A, Salone GS, Mangano C, Caprioglio C, Caprioglio D. Intrusive luxation of primary upper incisors and sequelae on permanent successors: a clinical follow-up study. *European journal of paediatric dentistry: official journal of European Academy of Paediatric Dentistry*. 2014;15(2):101-6.
- Thylstrup A, Andreasen JO. The influence of traumatic intrusion of primary teeth on their permanent successors in monkeys. A macroscopic, polarized light and scanning electron microscopic study. *Journal of oral pathology*. 1977;6(5):296-306.
- Paris S, Meyer-Lueckel H. Masking of labial enamel white spot lesions by resin infiltration-a clinical report. *Quintessence international*. 2009;40(9):713-8.
- Andreasen JO, Sundstrom B, Ravn JJ. The effect of traumatic injuries to primary teeth on their permanent successors. I. A clinical and histologic study of 117 injured permanent teeth. *Scandinavian journal of dental research*. 1971;79(4):219-83.

Deep Infiltration for traumatic hypomineralization: an esthetic and conservative treatment.

Dr. Marie Clement

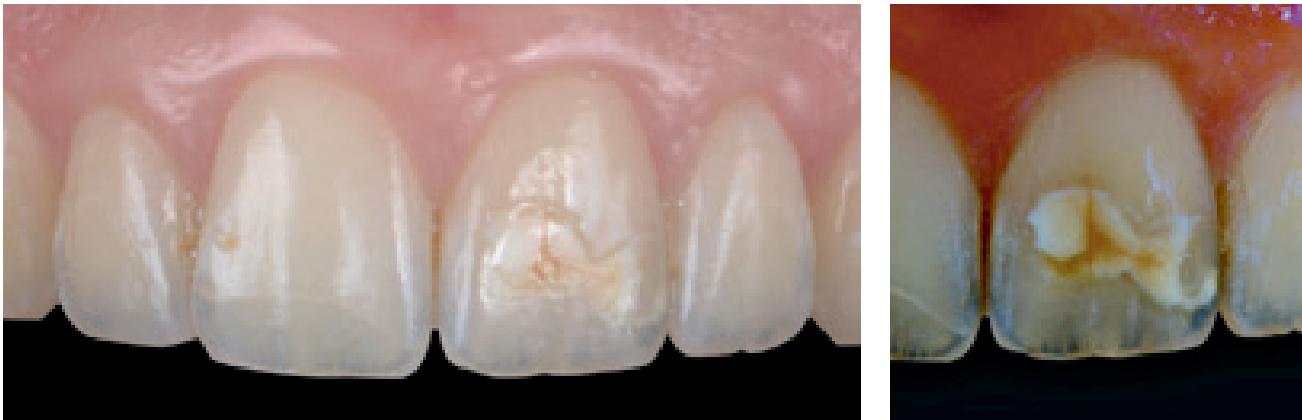

Fig. 1-2: Initial intra oral picture and initial polarized picture.

In everyday practice, dental surgeon, under increasing pressure from patients with esthetic concerns, is more and more often called on to treat abnormalities in tooth color.

The presence of a visible white area on the tooth surface is due solely to a defect in the enamel. This patient present a deep traumatic hypomineralization of a permanent tooth (Fig. 1-2). This is a consequence of periodontal trauma affecting the deciduous teeth. This may involve displacements of all kinds (concussion, subluxation, luxation, intrusion, extrusion, extraction). Traumatic hypomineralizations can present a wide variety of clinical expressions differing in color, shape, and outline. They are often limited to one tooth and sometimes associated lesions can often be found on mandibular opponents. Medical history is not one of the leading criteria on account of its uncertain utility (it is difficult to remember a shock that occurred several years previously). It is the elective nature of traumatic hypomineralizations rather than their clinical presentation that provides the most useful diagnostic information [1]. So the diagnosis of traumatic hypomineralization remains essentially diagnosis by exclusion (with Fluorosis, White spots and MIH).

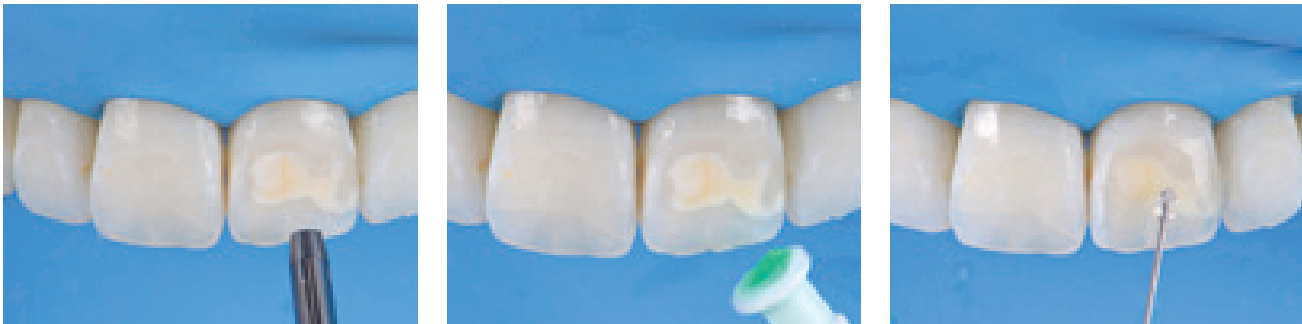

Fig. 3 Fig. 4 Fig. 5

Fig. 3-5: First step after Isolation with rubber dam placement is a prophylactic polishing. The deep cycle protocol is then : sandblasting with alumine oxyde 27 microns (Fig. 3). Erosion with Icon-Etch (15% HCl) 2 minutes (Fig. 4) Deshydration with Icon-Dry (application of alcohol) (Fig. 5). At this step we have to control if the spot is always present. If yes, a second same cycle is necessary [3].

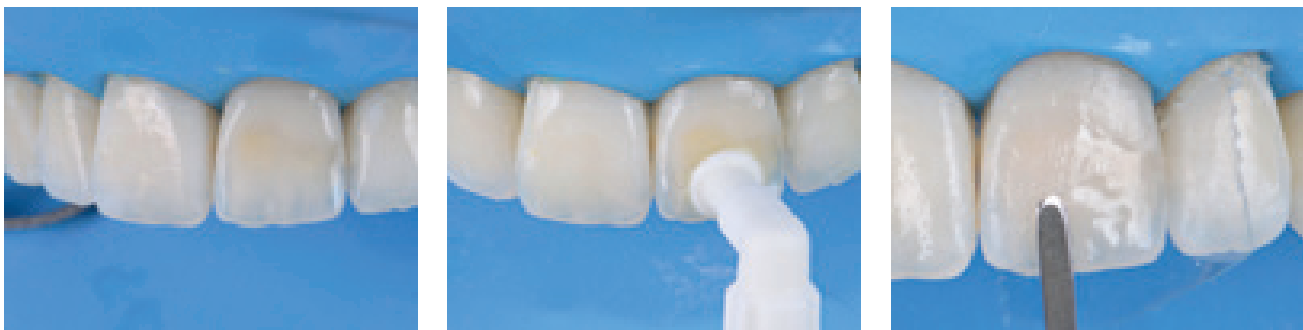

Fig. 6 Fig. 7 Fig. 8

Fig. 6: The third times Icon-Dry application (after 3 cycles). For our patient 3 deep cycles have been necessary: the optical change now concerns all lesions in totality and infiltration is possible. Fig. 7: Infiltration is performed with Icon-Infiltrant during 3minutes [4]. Use of dental floss before light curing is recommended. A second infiltration is necessary for 1 minute and light curing too. Fig. 8: All the lesions are translucent. If the hollow left by milling or sandblasting is significant, the slight loss of hard tissue can be made up with composite. After light-curing of the infiltrate, the resin will be used as an adhesive support. For this reason, glycerin should not be used before composite application. Several studies have shown that bonding between the resin infiltrate and composite is of very good quality [5]. So the application of a thin composite build-up to this tooth is performed with one single shade of enamel composite resin. No stratification is required : only a work of surface texture with different brushes. A last light curing is necessary under glycerin to avoid the inhibited layer because of oxygen.

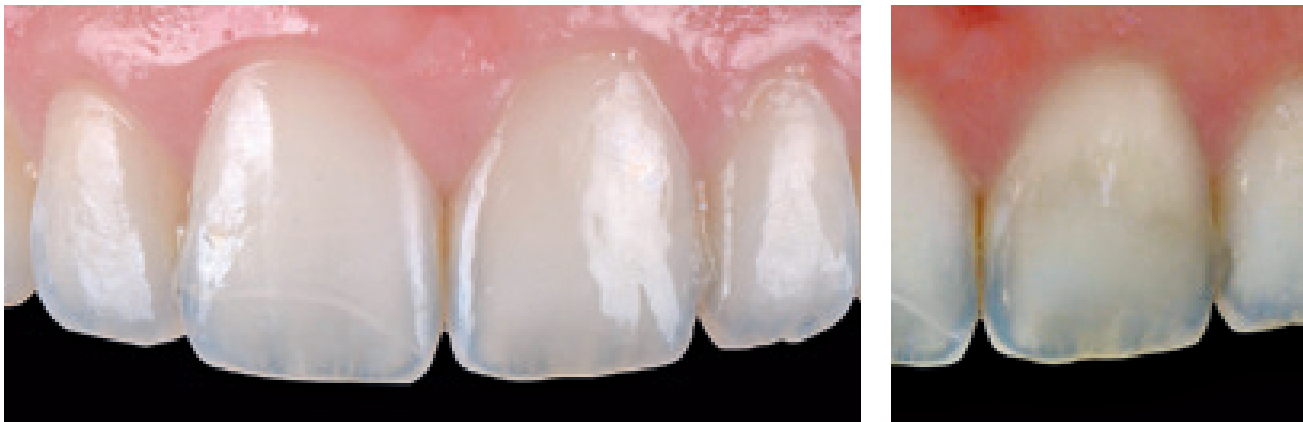

Fig. 9: Final intra oral picture. After two months the result is satisfactory. The beauty of this internal dentin stratification has been conserved! Fig. 10: Final polarized picture

The histopathology of traumatic hypomineralization involves subsurface hypomineralization under a relatively wellmineralized surface layer. The surface layer is the result of post-eruptive ionic reprecipitation. It is due to inconsistent angles that the results of treatment of traumatic hypomineralization by erosion-infiltration are difficult to predict.

In the case of white spots involving deep lesions of the enamel superficial infiltration is not sufficient and a new technique has been developed : the deep infiltration [2].

A deep infiltration treatment is proposed to our patient. Before the treatment the patient is informed a composite resin will be probably use on the teeth to mask concavity and alteration of enamel. Even if it remains a very conservative treatment.

The concept of deep infiltration involves paying a price in the form of mild mutilation of the enamel through preparation by sandblasting or milling so as to ensure that the infiltration can spread through almost the whole of the lesion if the latter is deep.

Key Learnings

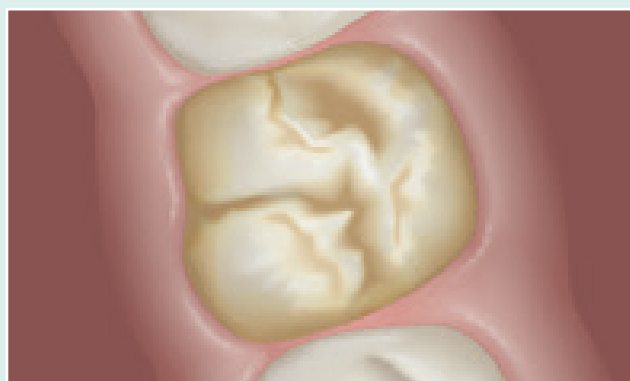
- 1 Traumatic hypomineralization of a permanent tooth is a consequence of periodontal trauma affecting the deciduous teeth
- 2 The diagnosis of traumatic hypomineralization remains essentially diagnosis by exclusion (with Fluorosis, White spots and MIH).
- 3 A last light curing is performed under glycerin to avoid the inhibited layer because of oxygen.

References

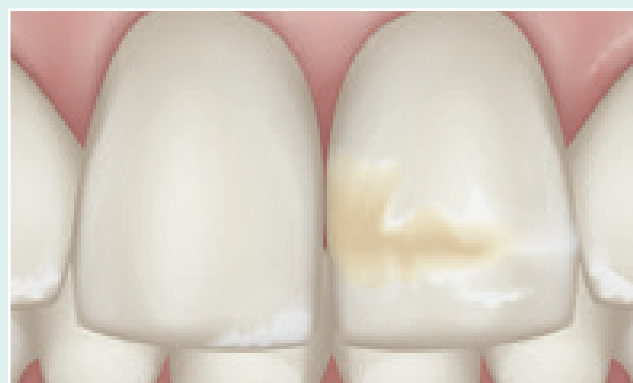1. White spots on enamel: treatment protocol by superficial or deep infiltration (part 1). Attal JP, Atlan A, Denis M, Vennat E, Tirlet G. Int Orthod. 2014 Mar;12(1):1-31 j.ortho.2013.12.011. Epub 2014 Feb 3. English, French.
2. White spots on enamel: treatment protocol by superficial or deep infiltration (part 2). Attal JP, Atlan A, Denis M, Vennat E, Tirlet G. Int Orthod. 2014 Mar;12(1):1-31 j.ortho.2013.12.011. Epub 2014 Feb 3. English, French.
3. Infiltration, a new therapy for masking enamel white spots: a 19-month follow-up case series. Tirlet G, Chabouis HF, Attal JP.
4. Paris S, Meyer-Lueckel H. Masking of labial enamel white spot lesions by resin infiltration- a clinical report. Quintessence Int. 2009 Oct;40(9):713-8.
5. Wiegand A1, Stawarczyk B, Kolakovic M, Hämmerle CH, Attin T, Schmidlin PR. Adhesive performance of a caries infiltrant on sound and demineralised enamel. J Dent. 2011 Feb;39(2):117-21. Oct 17.



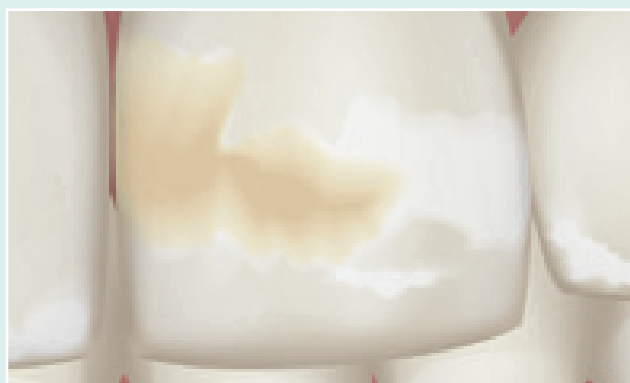
Patient history or etiology. Unknown, non specific.



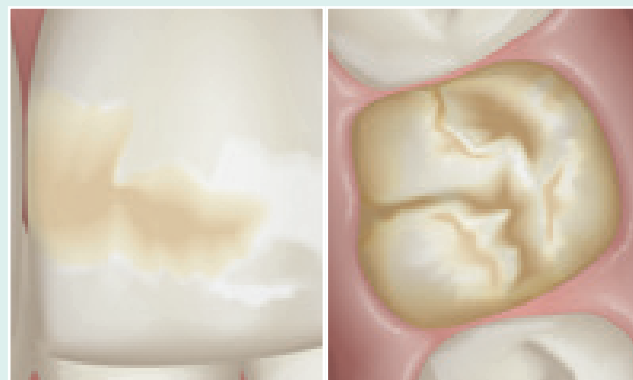
Affected tooth/teeth. One to four affected permanent molars and the associated incisors.




Localization. Affected first permanent incisors with MIH are asymmetrical. Usually limited to the incisal or cuspal third of the crown, rarely involving the cervical third.



Border. Well-demarcated, a qualitative defect affecting enamel translucency. No changes to the enamel thickness.



Color. Whitish-cream or yellow-brown. The intact enamel surface is hard, smooth and often hypermineralised following posteruptive maturation, the subsurface enamel is soft and porous [3,4].



Molar Incisor Hypomineralisation (MIH).

Dental history and visual diagnosis.

MIH is a condition related to demarcated hypomineralised lesions affecting at least one permanent first molar and often the permanent incisors. Other teeth can be affected by demarcated hypomineralised lesions (such as the second primary molar), however, these are not included in the MIH definition, but should be able to be treated in a similar manner.

MIH affects approximately 14% of the population [1], with approximately one third being severely affected. Diagnosis is from detection of a demarcated opaque lesion of the enamel located in the occlusal 2/3 of the crown (the gingival third is not affected) [2]. The colour varies from opaque white to yellow/brown, and severity of mineral loss normally increases with darker colour.

With more severe lesions, there may be post-eruptive breakdown (PEB) or loss of enamel, and this may be associated with a carious lesion.

MIH-type demarcated lesions differ from other developmental defects such as hypoplasia and fluorosis. Hypoplasia is a quantitative defect – that is, there is developmentally thin enamel, often in a horizontal linear pattern or pitting.

Fluorosis is a diffuse hypomineralised lesion, corresponding to the developmental lines of the tooth development, with indistinct definition between sound and fluorosed enamel.

Until now, MIH is not indicated for the infiltration treatment with Icon. Nevertheless, infiltration of MIH lesions often leads to significant improvements of aesthetics and has a positive impact of patient's quality of life. In this chapter various MIH cases with different approaches and successes are shown.

Prof. Dr. David J. Manton

References:

1. Dongdong Zhao, Bao Dong, Dandan Yu, Qiongqiong Ren & Yehuan Sun, The prevalence of molar incisor hypomineralization: evidence from 70 Studies, International Journal of Paediatric Dentistry (July 2017)
2. Felicity A. Crombie, David J. Manton, Joseph E.A. Palamara, Ilya Zalozniak, Nathan J. Cochrane, Eric C. Reynolds, Characterisation of developmentally hypomineralised human enamel, Journal of Dentistry 41 (2013) 611 – 618
3. Weerheijm KL, (Department of Cariology, Endodontology and Pedodontiology, Academic Centre for Dentistry (ACTA) Amsterdam, The Netherlands) Molar-incisor-hypomineralisation (MIH). Eur J Paediatr Dent. 2003 Sep;4(3):114–120.
4. Jalevik B, (Department of Pedodontics, Faculty of Odontology, Göteborg University, Sweden). Enamel hypomineralisation in permanent first molars. A clinical, histomorphological and biochemical study. Swed Dent J Suppl. 2001;149:1–86.

A new concept for treating enamel opacities.

Prof. Dr. Nabih Douki Zbidi, Dr. Omar Marouane, Dr. Fadwa Chtioui

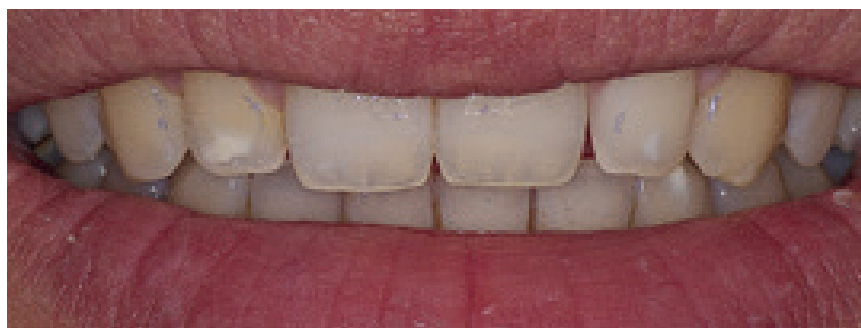


Fig. 1: Initial view of a lesion on the upper right lateral incisor.

Introducing resin infiltration technique has completely redefined the way we treat enamel hypo mineralization. However, this procedure remains a depth-dependent technique [1]. Regarding the fact that the success of the infiltration technique totally depends on the lesion's topography, a new classification of enamel hypomineralization, based entirely on the lesion's depth was set forth. The optical properties of the enamel served as the basis for this classification. The latter includes a precise, but simple, description of the lesion in daylight conditions as well as under transillumination, to eventually match the clinical data collected to the corresponding lesion topography. This classification regroups three major types of enamel opacities: Superficial, mixed and deep lesions. Each category has specific clinical features in relation with the topography of the lesion and the proper treatment approach will be then adopted accordingly. While keeping in mind that superficial lesions represent the easiest category to achieve a favorable treatment outcome, the idea behind the treatment concept proposed implies the transformation of mixed and deep lesions into superficial ones using abrasive procedures before proceeding with their infiltration [2]. This clinical case report describes a suggested treatment of a deep lesion affecting a lateral maxillary incisor related to MIH based on transillumination, focalization and lesion transformation to achieve a good aesthetic result.

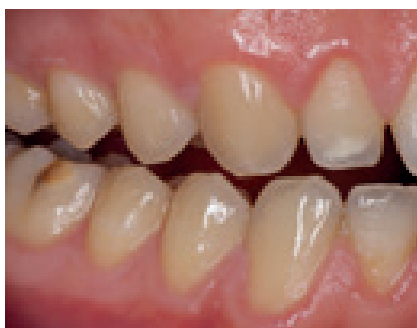

Fig. 2

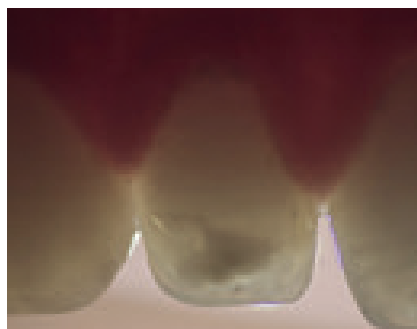


Fig. 3

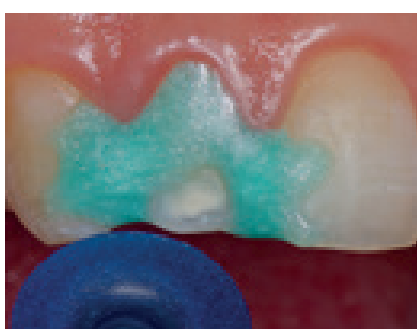

Fig. 4

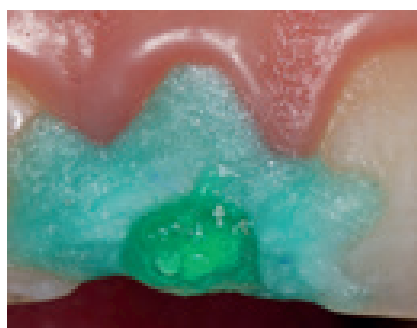

Fig. 5

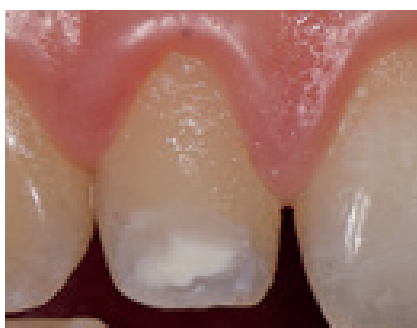


Fig. 6

Fig. 2: Lateral incisor showing an ivory-white opacity melded in sound enamel tissue located in the incisal third. We may note the presence of the stained opacity affecting the first right lower molar confirming the MIH diagnosis. Fig. 3: Under transillumination, the lesion appears opaque with blurry edges showing an indistinct interface between the enamel opacity and sound enamel. Fig. 4: Lesion focalization using a light-cured resin protective barrier. The aim of this procedure is to be more conservative during abrasive and erosive steps. A mild mutilation of the enamel layer covering the lesion using an abrasive disc. This step was assessed under visual examination and transillumination until the lesion is exposed almost entirely to and superficial features are perceived. Fig. 5: The exposed hypomineralized enamel was etched during 120 s using Icon-Etch (15 % HCl) Fig. 6: Aspect of the lesion within the reflection of incident light following abrasive and erosive steps. Note the transformation of the opacity from an ivory-white to an intensely white lesion.

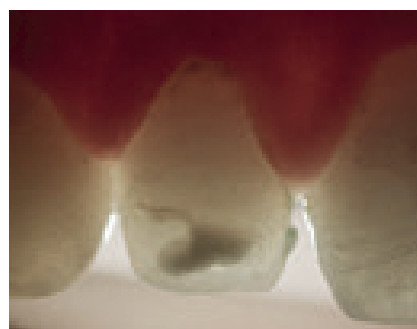


Fig. 7

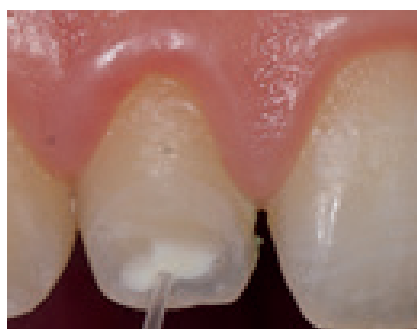


Fig. 8

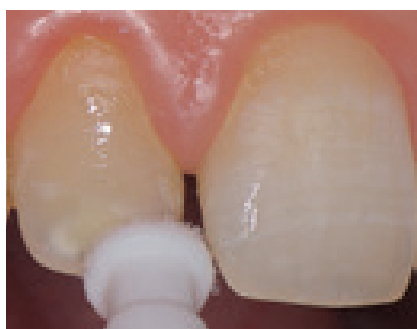

Fig. 9

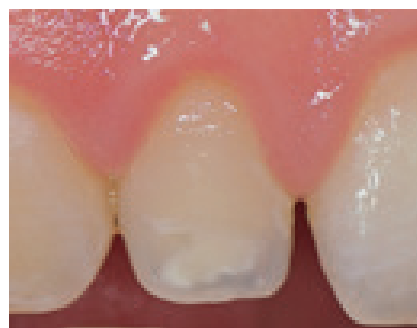

Fig. 10

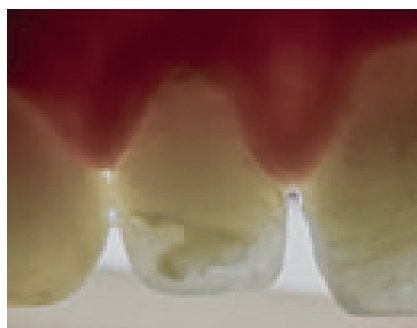


Fig. 11

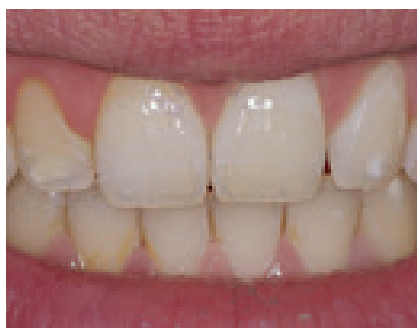

Fig. 12

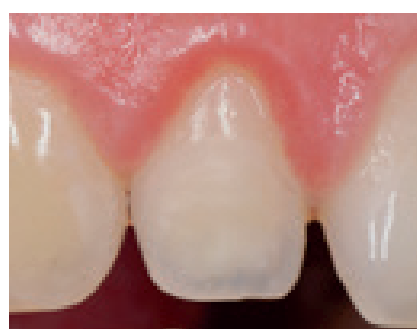

Fig. 13

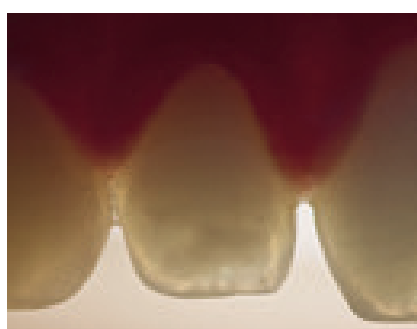


Fig. 14

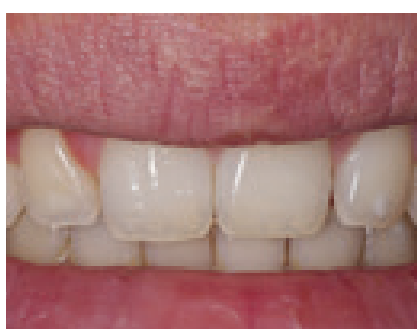


Fig. 15

Fig. 7: Aspect of the lesion under transillumination after abrasive and erosive steps. The lesion edges are now well demarcated suggesting the transformation into a rather superficial lesion. Fig. 8: Dehydration using Icon-Dry. Fig. 9: Infiltration is performed using Icon-Infiltrant. The lesion should be infiltrated for at least 3 minutes until complete saturation and the infiltration does not appear to be further possible. A quick control (to avoid light curing) under transillumination is recommended during this step to assess the degree of infiltration. Fig. 10 and 11: The features of the lesion within light reflection and transillumination following the infiltration procedure show a partial infiltration with an almost complete disappearance of the opacity, which remains only at the margins. In case where the lesion is not completely infiltrated, it is highly recommended to wait for the enamel rehydration in the aim of properly assessing the final aesthetic outcome of the infiltration [3]. Fig. 12: Two weeks later, at the next appointment the appearance of the lesion shows no improvements. Accordingly, the etching, drying and lesion infiltration were all repeated exactly as performed in the first session. Fig. 13 and 14: Aspect of the lesion under incident light and transillumination after a second session of resin infiltration procedure showing the complete disappearance of the opacity as well as of the halo effect. Fig. 15: Final result.

Key Learnings

- In transillumination and within reflection of incident light, the aspect of the opacity gives topographic information regarding the lesion's depth. This actually allows to set the treatment steps accordingly.
- The newly suggested concept provides a direct visual assistance to the practitioner during the lesion transformation and after infiltration and helps assessing the treatment progress by providing a more controllable and reproducible outcome.
- In case of partial infiltration, the re-intervention can be possible to infiltrate the remaining un-infiltrated area.

References

- Denis, M., Atlan, A., Vennat, E., Tirlet, G., & Attal, J. P. (2013). White defects on enamel: diagnosis and anatomopathology: two essential factors for proper treatment (part 1). *International orthodontics*, 11(2), 139-165.
- Marouane, O., & Douki, N. (2016). Traitement focal de l'hypominéralisation traumatique de l'émail. *L'information Dentaire*, 27(7), 2-7.
- Attal, J. P., Atlan, A., Denis, M., Vennat, E., & Tirlet, G. (2014). White spots on enamel: treatment protocol by superficial or deep infiltration (part 2). *International orthodontics*, 12(1), 1-31.

Deep infiltration of MIH lesions: the use of transillumination as a diagnostic tool.

Associate Prof. Carlos Rocha Gomes Torres, Associate Prof. Alessandra Bühler Borges

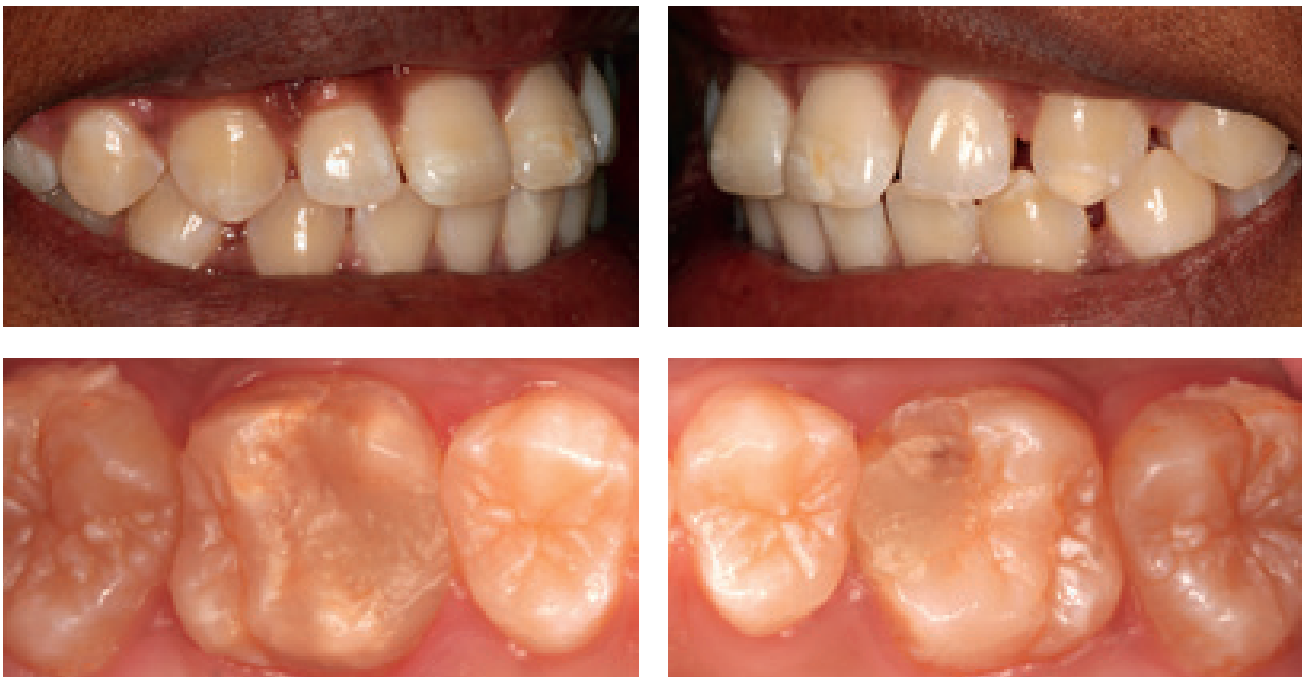

Fig. 1: Patient with main lesions in upper incisors, left canine and first upper molars, characterizing MIH. The lesions on mesial surface of molars were already restored with composite

The esthetic treatment of white lesions in anterior teeth is a frequent challenge for the dentists in the clinical practice. Different etiologies may change the enamel mineral structure and interfere with its interaction with the environmental incident light. Due to pathological changes that affect the enamel refractive index, the light suffer deviation and reflection inside the lesion, creating an optical maze which is over-luminous and responsible for the whitish aspect on the affected areas [1]. The enamel caries lesion is one of the most common problems, as a result of the hydroxyapatite demineralization by acids from bacterial biofilm, associated with the high consumption of fermentable carbohydrate. Even with the reduction of the caries disease activity, the arrested deep lesions can remain visible, impairing the esthetics of the smile. Since the 1970s, attempts to infiltrate initial enamel caries have been reported [2, 3], but only in the late 2000s the technique was improved and a commercial product (Icon, DMG) was developed. At this time, the resinous infiltration technique was mainly directed to arrest the approximal lesions progression on posterior teeth, filling the lesion body with resinous monomers [4, 5, 6]. The

treatment is based on erosion of the external surface zone of the lesion with hydrochloric acid gel, followed by washing, dehydration with absolute ethanol, infiltration with resinous monomers and light curing. However, since the infiltrant formulation has a refractive index close to the sound enamel, a color masking effect was observed, stimulating its use as an esthetic treatment on anterior teeth [7, 8]. Due to the histological structural similarities between carious white spot lesions and hypomineralized fluorotic white lesions, the resinous infiltration procedure also produced excellent clinical results on those cases [9]. The success of the infiltration protocol on the treatment of caries and fluorotic lesions stimulated the researchers to test this procedure in other kinds of developmental white lesions, such as traumatic lesions and Molar Incisor Hypomineralization (MIH). The MIH lesions are enamel defects that occur due to depressed activity of the enamel-forming ameloblasts. This condition has a multifactorial etiology, such as preterm born, low birth weight, respiratory diseases, poor general health or systemic conditions in the first 3 years of life [10, 11]. The clinical expression of the disease implies the presence of

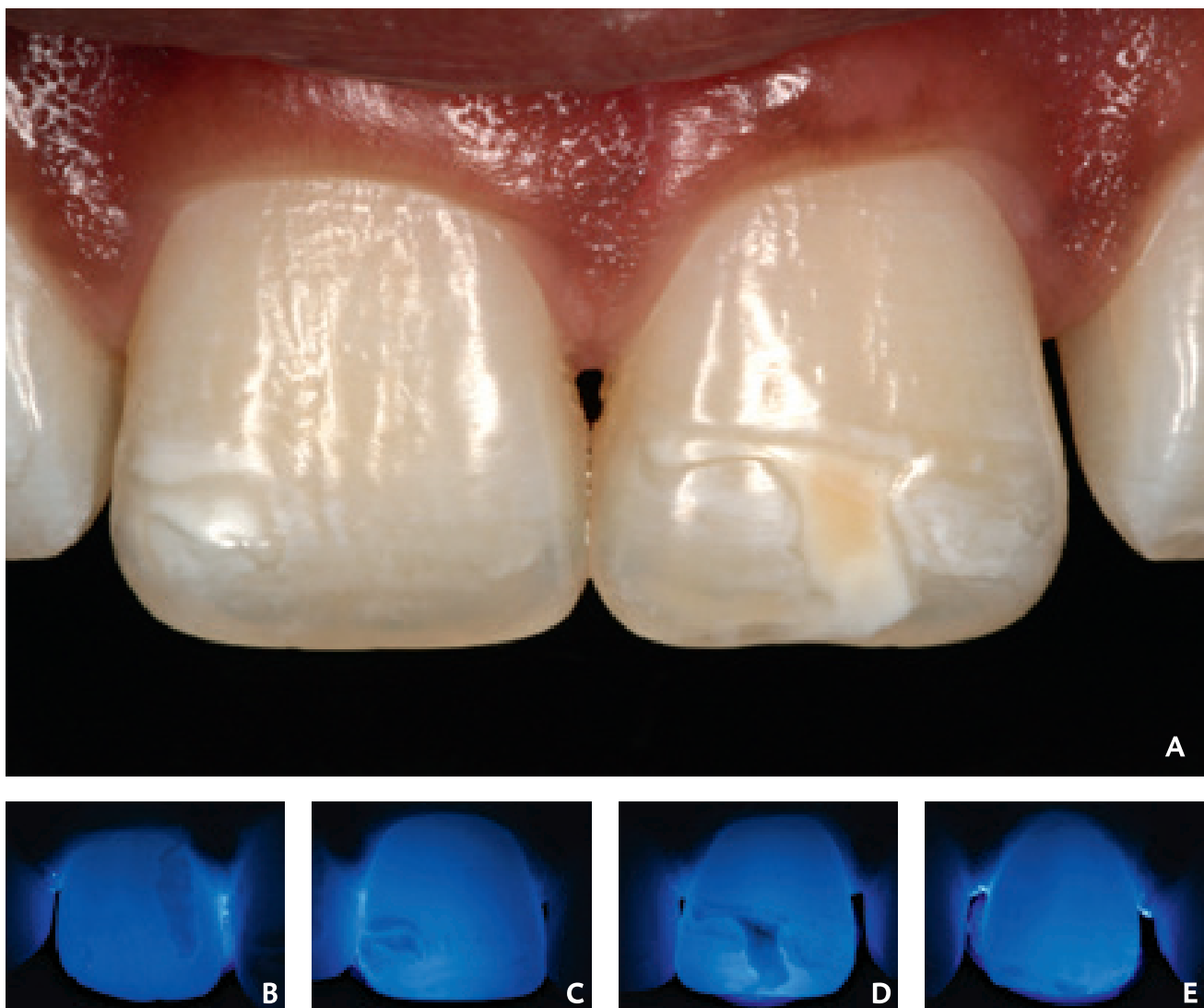


Fig. 2 A-E: Transillumination of the main lesions in the upper. It can be observed that the main lesion in the left central incisor (Fig. 2 D) presented a black central area when transilluminated, indicating to be deeper than the lesions in the other incisors (Fig. 2 B, C and E). Based on that, the deep infiltration technique was applied only on the left central incisor. Besides the main lesions, small whitish areas were spread over the whole surfaces of the anterior teeth.

qualitative enamel defects in at least one of the four first permanent molars, associated or not with lesions on the permanent incisors. Sometimes, the cusps of the canines and the second molars are also involved [1]. However, the attempt to infiltrate the MIH lesions with the same technique applied for caries and fluorosis did not produce acceptable esthetic results. A white halo or edge effect was observed around the lesion after the infiltration, indicating an improper penetration of the resinous monomers at the borders [12]. This occurs due to the fact that the internal lesion margins form a different angle with the external tooth surface in relation to the caries and fluorotic ones. In MIH, the lesions margins form an acute angle with the external surface, impairing the monomer penetration at this area, while for the caries and fluorosis lesions the borders form an obtuse angle with the surface, allowing an uniform resinous infiltration [1]. In addition, in deep MIH lesions, sometimes the defective enamel is covered by a layer of intact enamel, which cannot be removed by the erosive effect of the hydrochloric acid alone, completely preventing the interaction of the infiltrant with the lesion body [1].

In attempt to overcome this problem, Attal et al [12]. Proposed the deep infiltration protocol; in which the external lesion surface should be previously removed using mechanical abrasion with aluminum oxide sandblast or a rotary diamond bur. This procedure grants access to the lesion body, allowing penetration of the resinous monomers. In addition, the border area can be gently removed, preventing the halo effect after the infiltration. The area is then covered with a composite restoration. Even after a small superficial enamel tissue removal, the infiltration of the lesion body can increase the translucency of the subjacent affected enamel, providing a better background for the composite restoration. Without a previous infiltration, the opaque background hinders the proper masking of the whitish area by the composite layer applied, being necessary a deeper removal of the affected tissue in order to provide adequate results. Therefore, although the deep infiltration procedure demands some tissue removal, it could be considered a more conservative approach, since it eliminates the necessity of a deep cavity preparation in order to obtain acceptable esthetic outcome.

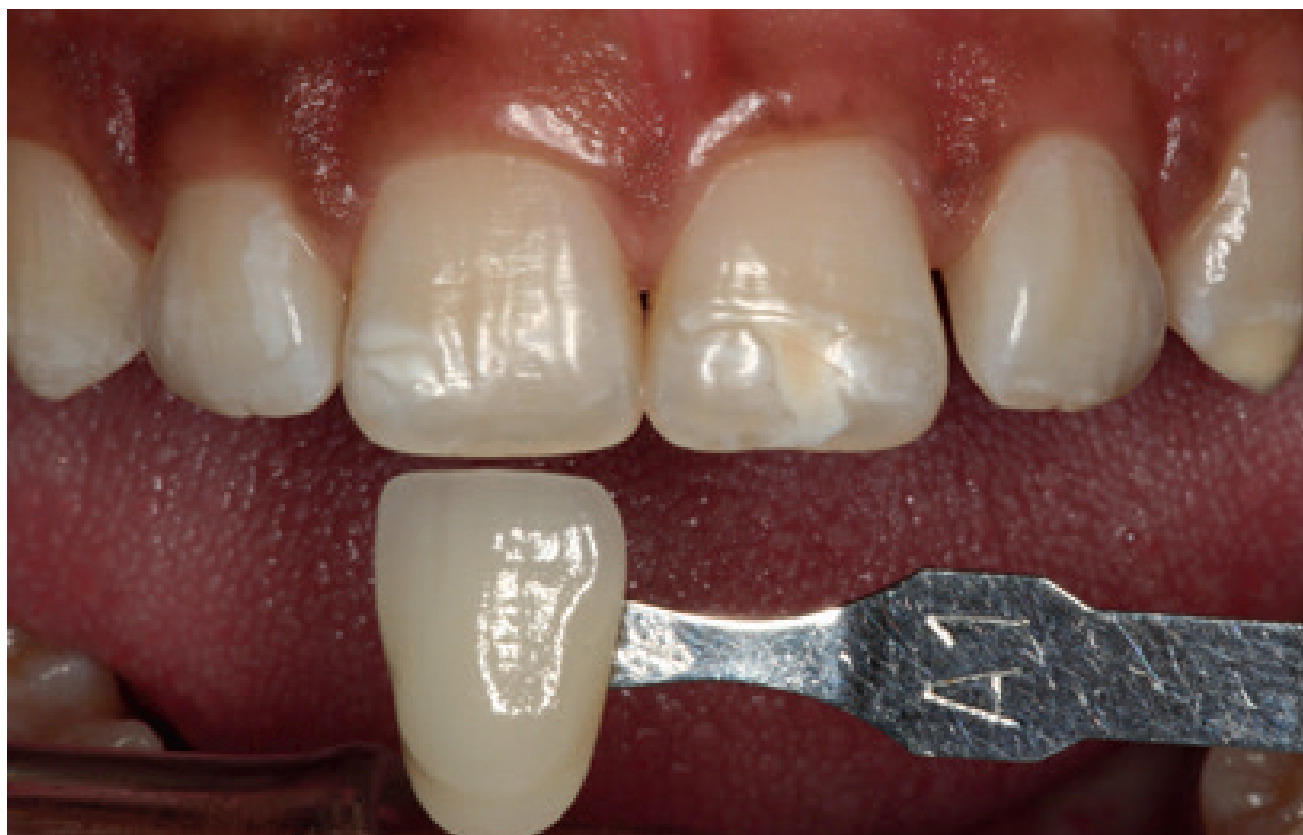

Fig. 3: As a composite would be necessary to cover the deep infiltrated area, the shade selection was performed as the first step.

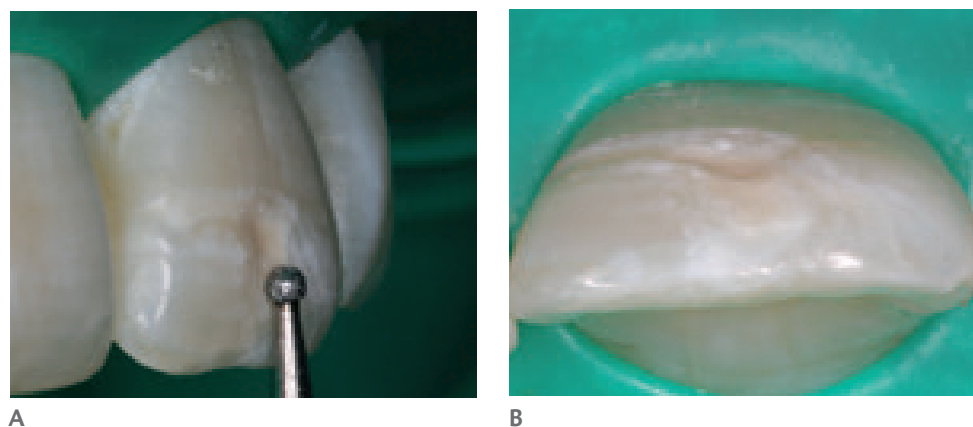


Fig. 4 A-B: A small preparation performed in the deep lesion in order to provide access to the lesion body and remove the external enamel on the borders. A round diamond bur was used to remove only a minimal amount of tissue.

However, the correct diagnosis and clinical decision about when to indicate the regular superficial infiltration and when to use the deep infiltration technique remains a clinical challenge. In order to help the clinician to take this decision, the transillumination technique can be very useful. This procedure was originally developed for diagnosis of caries lesions mainly in the proximal surface of posterior and anterior teeth. It is performed placing a high output light source, such as a blue light-curing unit, on the lingual surface of the suspected tooth, allowing the light to pass through its structure and reach the labial surface, which can be evaluated by the dentist. On a sound tooth, due to the relatively homogeneous structure of enamel and dentin, the light is normally transmitted and a light blue aspect is noticed in the whole crown. However, in the presence of caries or a hypomineralized lesion, the area can appear dark blue or completely black, indicating the reduction or complete blockage of the light transmission through the tooth, depending on the lesion

dimensions. Our personal experience on using the transillumination technique on MIH lesions has shown that, when a light blue aspect is noticed in the baseline analysis of the clinical case, the lesion is supposed to be shallow, and the regular superficial infiltration can be attempted first. However, when dark blue or black areas are observed in the center of the lesion, it is considered deep, and the deep infiltration technique should be performed since the beginning of the treatment.

Next, a clinical case of color masking of MIH lesions is presented, in which some lesions were infiltrated with the superficial technique, while others received the deep infiltration procedure associated with the composite restoration.

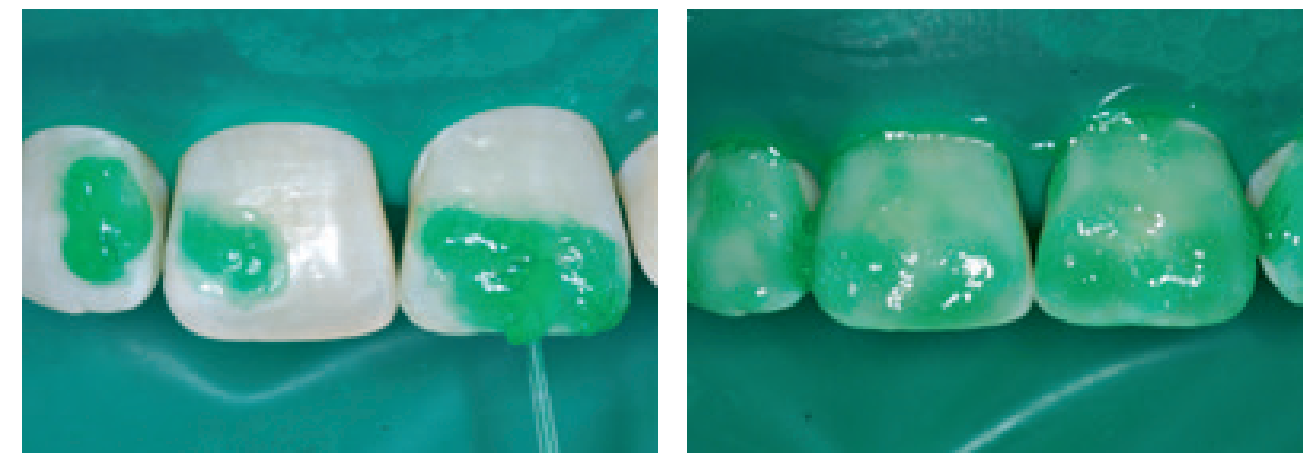

Fig. 5 A-B: After that, etching with hydrochloric acid gel was performed only over the main lesions, in order to remove the external surface of the shallow ones, and increase the permeability of the bur opened deep ones. The acid (Icon-Etch, DMG) was applied for 6 minutes over the main lesions, since shorter times are usually insufficient on those cases. Then, the whole surface was additionally etched for 2 minutes, in order to etch the small lesions spread over the teeth surfaces.

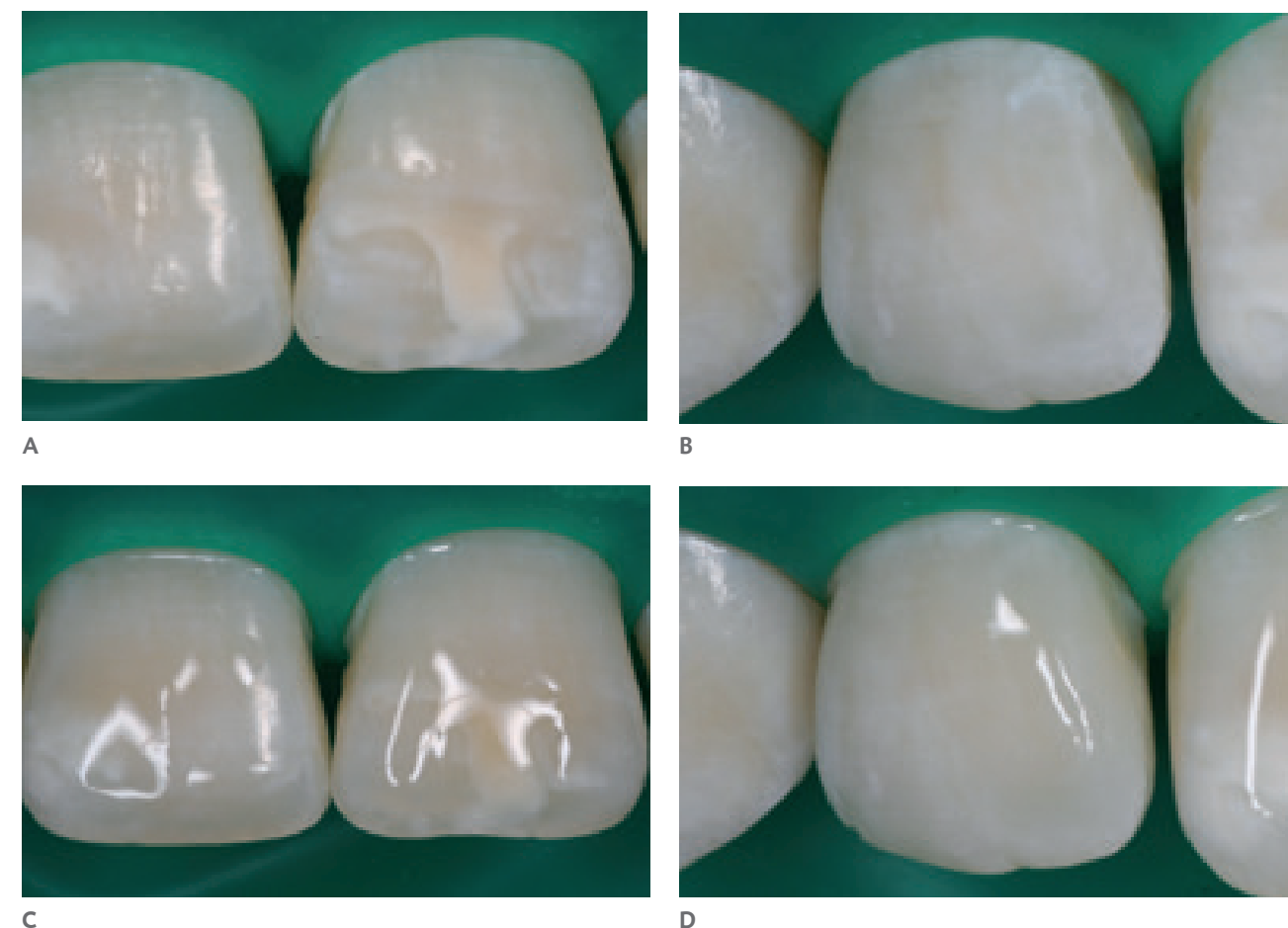


Fig. 6 A-D: The gel was washed and the surfaces dried with an air stream, followed by the ethanol application (Icon-Dry, DMG). Besides to dehydrate the enamel, the ethanol penetration can also provide a preview of the infiltrant masking effect [13]. Although the refractive index of ethanol is lower than that of the infiltrant, if some masking effect is observed after its application, a more favorable masking will be provided by the resinous infiltrant. However, if the aspect is not changed after the ethanol application, no change is supposed to be observed after using the infiltrant, indicating that an additional etching or wear with the bur must be performed. Comparison among after etching and drying (A,B) and after the ethanol application (C,D).

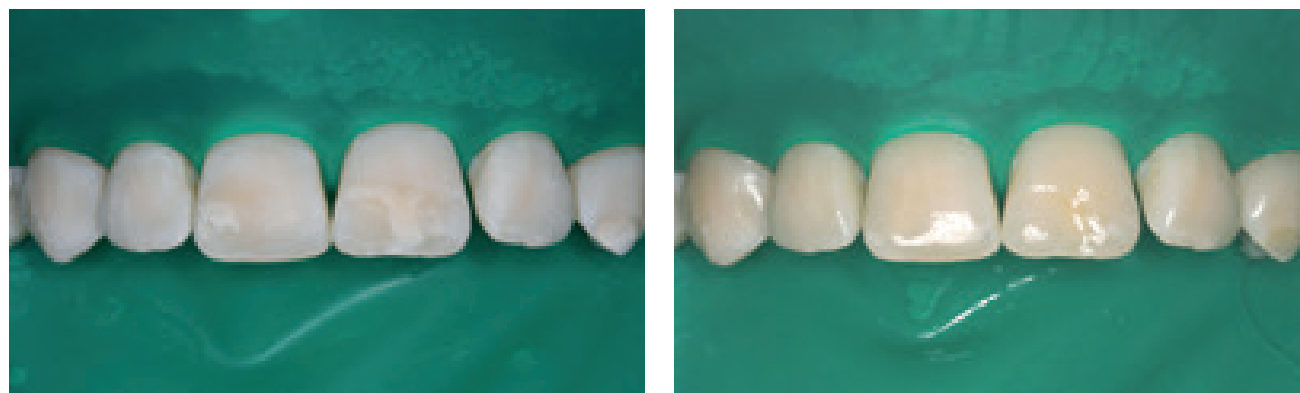


Fig. 7 A-B: After that, the surface was dried with air and the resinous infiltrant (Icon-Infiltrant, DMG) was applied over the labial surface of all teeth, remaining undisturbed for 3 min. The excess was removed with an air stream and the light-curing was performed during 40 s on each teeth. Then the infiltrant was applied again and let over the surface for 1 minute. The excess was removed and the light-curing was performed.

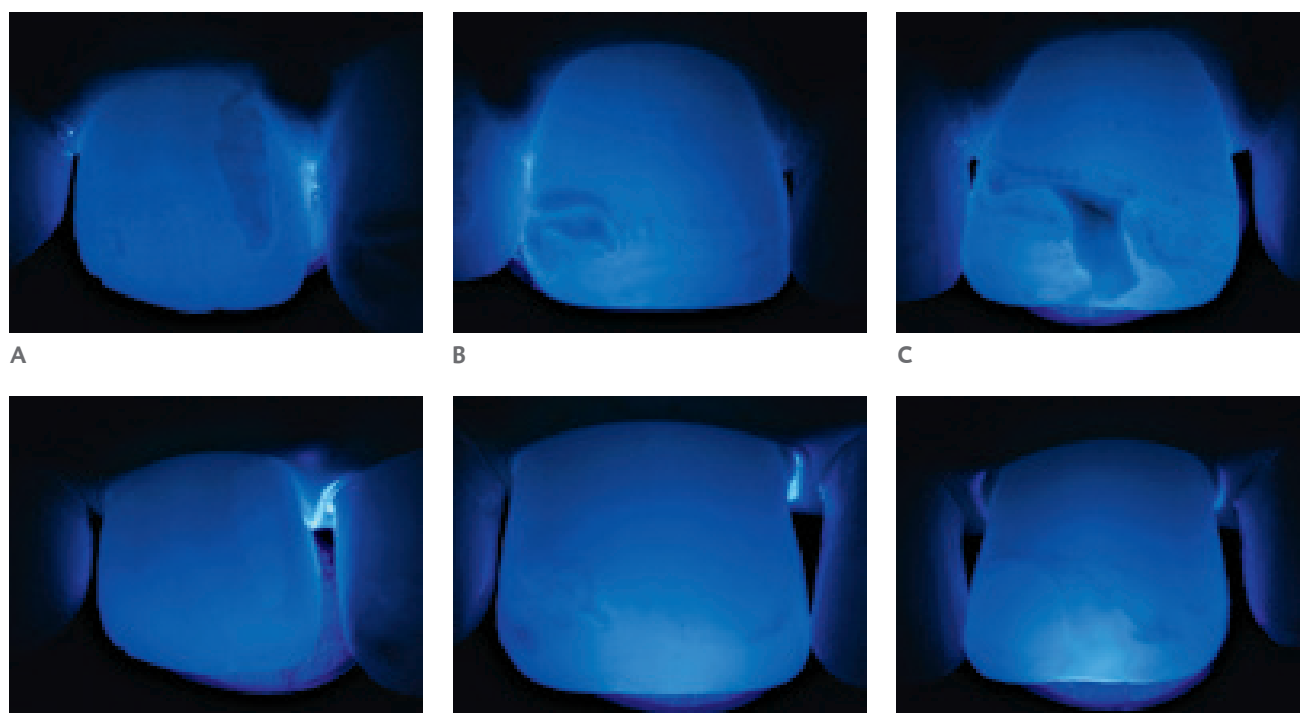


Fig. 8 A-F: The transillumination procedure was repeated after the infiltration, showing a significant increase in the light transmission. The dark areas of the deep lesion in the left central incisor became lighter (Fig. 8 C and 8 F), while the lesion in the right lateral incisor became even more translucent than at the baseline (Fig. 8 A and 8 D).

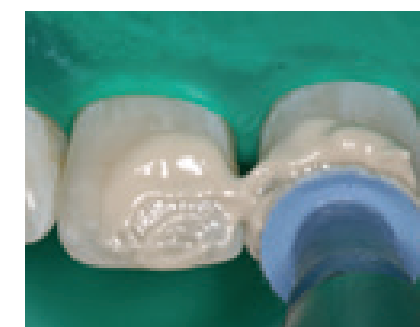
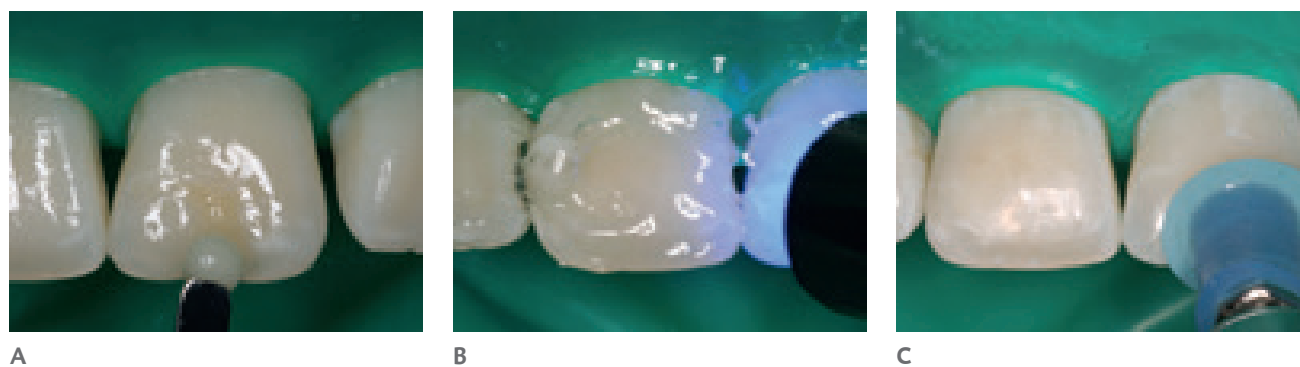
Fig. 9 A-D: Next, the deep infiltrated lesions were restored with composite (Fig. 9 A). A layer of glycerin gel was applied over the whole infiltrated teeth surface in order to eliminate the environmental oxygen, which can inhibit cure of the external infiltrated layer, providing a better conversion degree of the monomers in polymers (Fig. 9 B). After that, the surface was first polished with abrasive disks and then with felt disks and polishing paste.

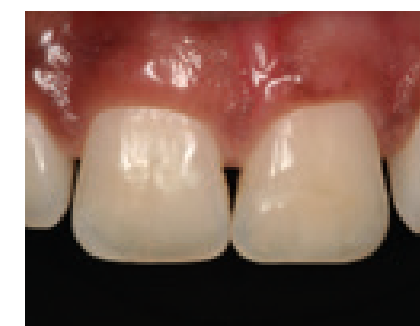

Fig. 10 A-B: Post-treatment results.

Key Learnings

- In the deep infiltration protocol the external lesion surface should be previously removed using mechanical abrasion with aluminum oxide sandblast or a rotary diamond bur.
- Transillumination technique can be very useful to identify the depth of the lesion. When a light uniform blue aspect is noticed in the baseline analysis of the clinical case, the lesion is supposed to be shallow, and the regular superficial infiltration can be attempted first. However, when dark blue or black areas are observed in the center of the lesion, it is considered deep, and the deep infiltration technique should be performed.
- The esthetic treatments of MIH may be combined with the superficial infiltration technique and the deep infiltration procedure followed with the composite restoration.

References

1. Denis M, Atlan A, Vennat E, Tirlet G, Attal JP. White defects on enamel: diagnosis and anatomopathology: two essential factors for proper treatment (part 1). *Int Orthod* 2013;11(2):139-65.
2. Robinson C, Hallsworth AS, Weatherell JA, Kunzel W. Arrest and control of carious lesions: a study based on preliminary experiments with resorcinol-formaldehyde resin. *J Dent Res* 1976;55(5):812-8.
3. Croll TP. Bonded resin sealant for smooth surface enamel defects: new concepts in «microrestorative» dentistry. *Quintessence Int* 1987;18(1):5-10.
4. Paris S, Meyer-Lueckel H, Kielbassa AM. Resin infiltration of natural caries lesions. *J Dent Res* 2007;86(7):662-6.
5. Torres CR, Rosa PC, Ferreira NS, Borges AB. Effect of caries infiltration technique and fluoride therapy on microhardness of enamel carious lesions. *Oper Dent* 2012;37(4):363-9.
6. Paris S, Meyer-Lueckel H, Colfen H, Kielbassa AM. Resin infiltration of artificial enamel caries lesions with experimental light curing resins. *Dent Mater J* 2007;26(4):582-8.
7. Paris S, Meyer-Lueckel H. Masking of labial enamel white spot lesions by resin infiltration--a clinical report. *Quintessence Int* 2009;40(9):713-8.
8. Rocha Gomes Torres C, Borges AB, Torres LM, Gomes IS, de Oliveira RS. Effect of caries infiltration technique and fluoride therapy on the colour masking of white spot lesions. *J Dent* 2011;39(3):202-7.
9. Torres CR, Borges AB. Color masking of developmental enamel defects: a case series. *Oper Dent* 2015;40(1):25-33.
10. Jalevik B, Noren JG. Enamel hypomineralization of permanent first molars: a morphological study and survey of possible aetiological factors. *Int J Paediatr Dent* 2000;10(4):278-89.
11. Johnsen D, Krejci C, Hack M, Fanaroff A. Distribution of enamel defects and the association with respiratory distress in very low birthweight infants. *J Dent Res* 1984;63(1):59-64.
12. Attal JP, Atlan A, Denis M, Vennat E, Tirlet G. White spots on enamel: treatment protocol by superficial or deep infiltration (part 2). *Int Orthod* 2014;12(1):1-31.
13. Abts C, Konietzke J, Ehrlich E, Fritz U, Meyer-Lueckel H. Case Series on the Value of Re-Wetting Prior to Resin-Infiltration of Caries Lesions. *Caries Res* 2014;48:1.

Micro-invasive esthetic treatment for MIH lesions.

Associate Prof. Carlos Rocha Gomes Torres, Daniele Mara da Silva Ávila, DDS, Ms, PhD Student

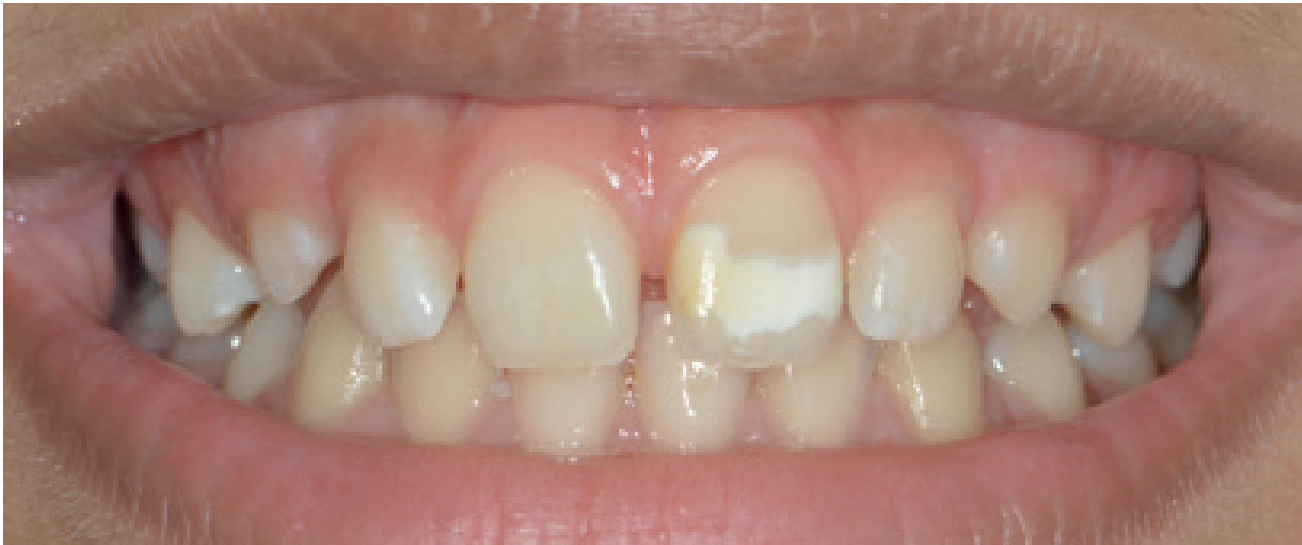

Fig. 1: Initial aspect of the lesion.

Molar incisor hypomineralization (MIH) lesions represent a challenge for Pediatric Dentistry with increasing prevalence [1]. The lesions are characterized by enamel with deficiency in minerals, rich in albumin and with normal content of amelogenin [2, 3]. Its etiology is still unknown but it is believed that it is caused by disturbances during the enamel mineralization stage [4].

The clinical aspects of the lesion are changes in the enamel color and translucency, resulting in brown-yellow or white asymmetrical spots mainly in incisors and first molars [4]. Histologically, these lesions are characterized by disorganized crystals and larger interprismatic spaces, with lower mineral density [5-7].

Attempt to mineralize the molars and incisor spots with fluoride varnishes, similarly to what is indicated for treatment of white spot lesions (WSL) has been made without the success [8-10]. Recently, the infiltration of low viscosity resin (Icon, DMG, Hamburg, Germany) became a minimally invasive

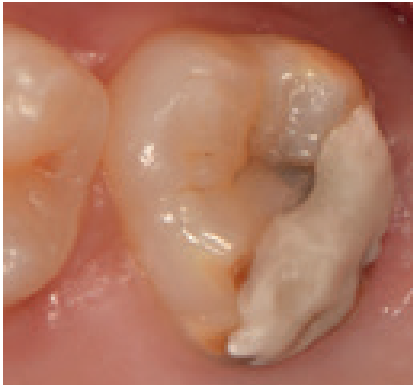

Fig. 2: Hypomineralization in the maxillary molar associated with MIH.

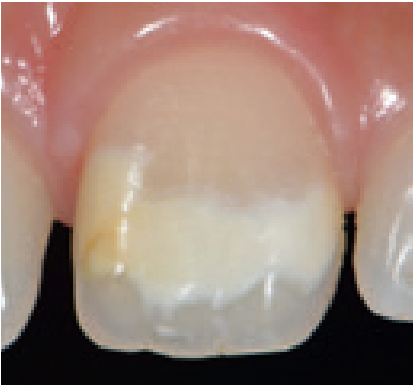

Fig. 3: Closer view of the white-yellow lesion in the enamel.

option for treatment of WSL [11-14]. This treatment aims to fill the porous interprismatic spaces inside the lesion [11, 13, 15] with the resin infiltration[14]. The infiltrant presents similar light refraction index as sound enamel [16], and therefore creates a masking effect [14, 17]. The efficacy of resin infiltration for superficial WSL has been shown previously [12, 13, 18-20]. Since favorable esthetic outcomes were

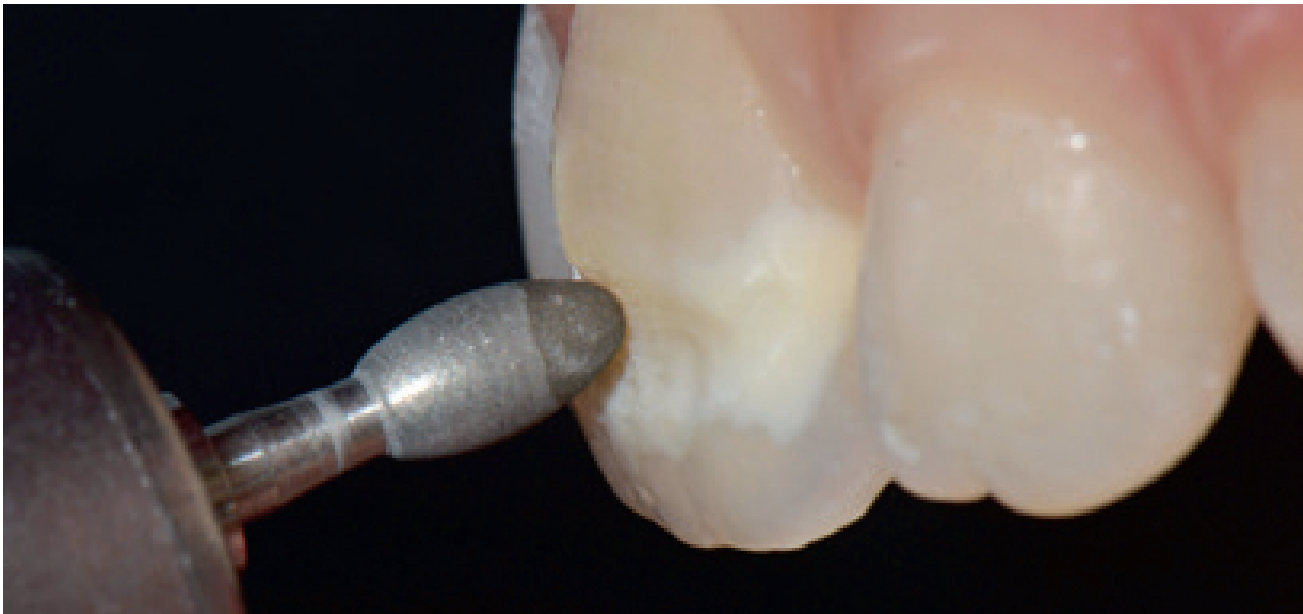

Fig. 4: In the first step, prophylaxis was performed and the labial surface of the affected enamel was slightly prepared with a diamond bur to expose the top surface of the lesion and allow the access of the resin infiltrant inside the affected region.

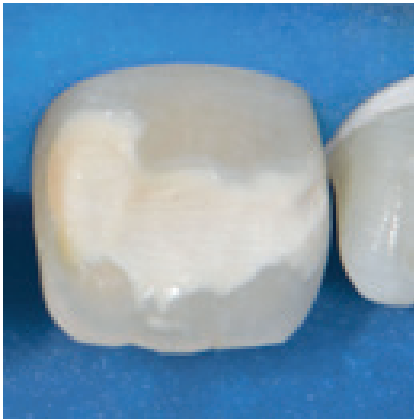

Fig. 5: After partial removal of affected enamel, (note that the discolored inner enamel remains), resin infiltration technique was performed using Icon-Infiltrant for smooth surfaces kit (DMG, Hamburg, Germany). The rubber dam isolation was applied.

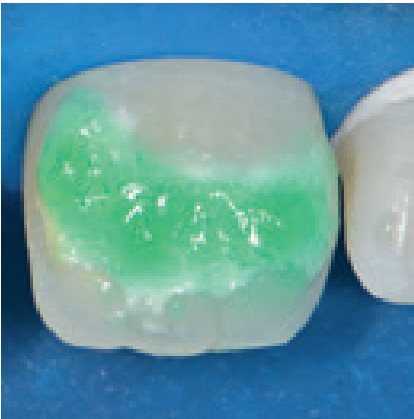

Fig. 6: The surface was eroded with 15 % HCl gel (Icon-Etch) for 2 minutes. After that, the acid was fully washed with air/water spray and dried.

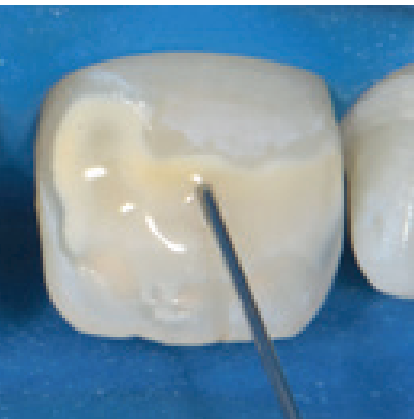

Fig. 7: In order to completely remove water from microporosities, the lesion surface received the application of 99 % ethanol (Icon-Dry) for 30 s, and again air-dried. After Icon-Dry application, when the lesion becomes invisible or is reduced in intensity, that means the etched lesion is ready to be proper infiltrated. When no change happens, the preparation can be extended in depth, and/or a new etching step is performed, until some masking with Icon-Dry is observed. The total depth of enamel removal in this clinical case was about 0.5 mm, and the acid was applied for 6 minutes (3 applications of 2 minutes). This progressive preparation is made to allow the minimal invasive intervention as possible.

obtained, the technique was also used in enamel developmental defects lesions, such as fluorosis, traumatic hypomineralization, and MIH [21, 22]. Different from caries and fluorosis lesions, which presents an external surface larger than the internal one, the MIH lesions have origin at the dentin-enamel junction and extend into the enamel, therefore, the erosive effect by HCl application on surface before infiltration does not allow reaching the «ceiling» of the lesion [21]. As the infiltration takes places on superficial healthy enamel and the anatomy of the MIH lesion presents an internal surface larger than the external one, it does not produce a favorable optical effect, explaining why treatments of MIH lesions by erosion/infiltration are not successful. Thus, in MIH lesions, the requirements for deep infiltration are preferable [21]. In deep infiltration, the superficial portion of enamel must be slightly removed, in order to reach the subsurface enamel portion where the MIH lesion is present.

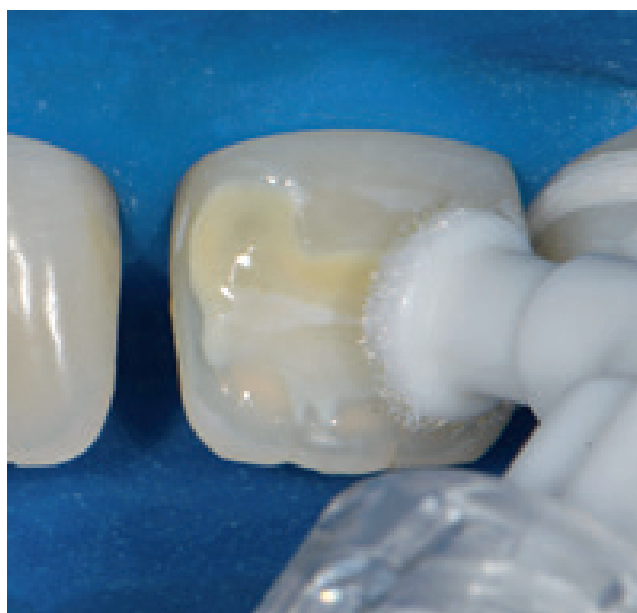

Fig. 8: Finally, the Icon-Infiltrant was applied in two steps. The first application was performed for 5 minutes, with surface protected from ambient light with an opaque screen.

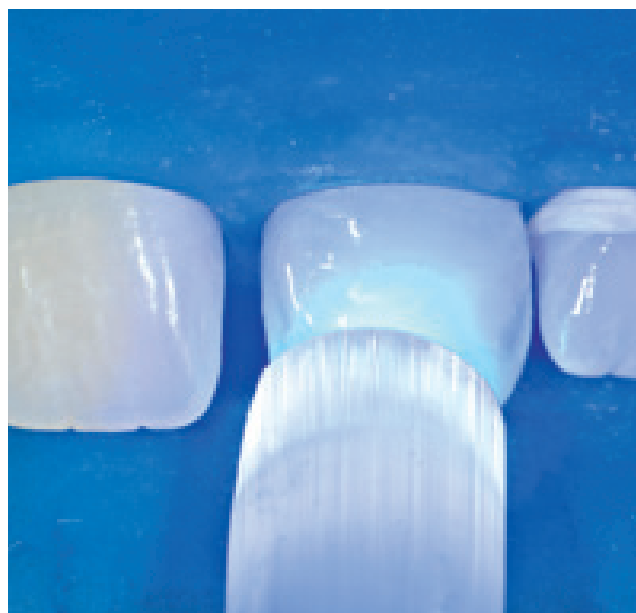

Fig. 9: Then excess was removed from the surface with a blow of air, and light curing was performed for 40 s. The infiltrant was applied a second time, for 1 minute, and again light cured for 40 s.

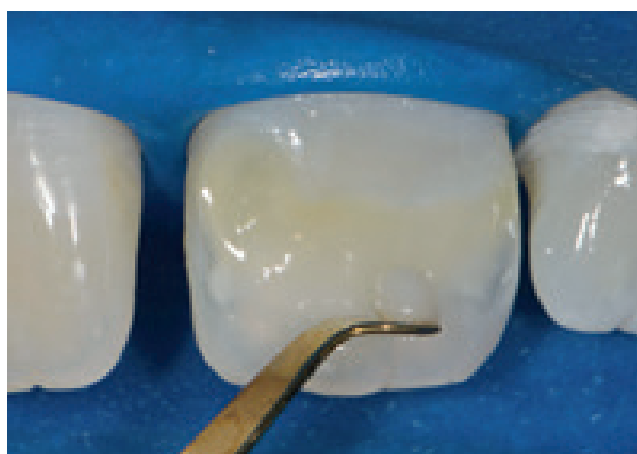

Fig. 10: Then, composite resin was applied (Filtek XTE Supreme, 3M ESPE, St Paul, MN, USA) in increments. No separated bonding agent was applied, since the Icon-Infiltrant per se is able to promoted adhesion to the tooth structure [23]. Each increment was light cured for 40 s. Finishing and polishing procedures were performed (Soflex discs, 3M ESPE).

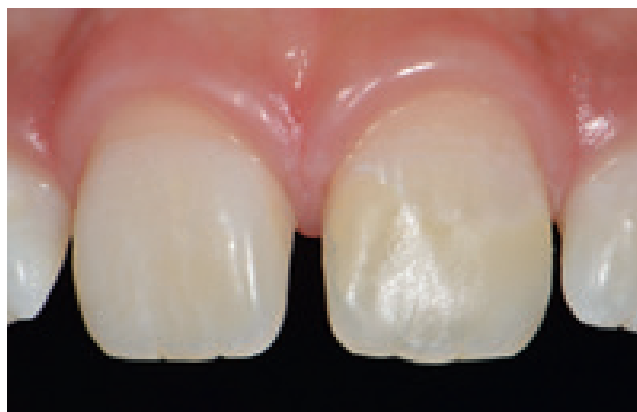

Fig. 11: Immediate outcome of the teeth in closer look.

Case Report

A 11-year old female patient presented a yellow-white lesion in the left maxillary central incisor (Fig 1), and also affected maxillary first molars, presenting enamel breakdown and cavities (Fig 2). The pronounced discolored lesion at the front incisor seriously compromised patient's smile aesthetic (Fig 3).

The patient reported that the tooth erupted with the spot, and that she had never undergone any kind of dental trauma. Also, the diagnosis of fluorosis was discarded due to the asymmetrical distribution of discolorations. Since the defects affected both molars and incisors, MIH was diagnosed.

The proposed treatment option was deep resin infiltration associated with composite restoration.

Summary

Molar incisor hypomineralization is a growing concern in Pediatric Dentistry. The unsatisfactory aesthetic promoted by the white spots lesion in anterior teeth is usually the main reason patients look for treatment. Minimal intervention is required for these cases, and deep resin infiltration might be a viable option.

Key Learnings

- The MIH lesions have origin at the dentin-enamel junction and extend into the enamel, therefore, the anatomy of the MIH lesion presents an internal surface larger than the external one.
- As the infiltration takes places on superficial enamel and the anatomy of the MIH lesion, it does not produce a favorable optical effect, explaining why treatments of MIH lesions by erosion/infiltration are not successful. Thus, in MIH lesions, deep infiltration is necessary to be performed.
- In deep infiltration, the superficial portion of enamel must be slightly removed, in order to reach the subsurface enamel portion where the MIH lesion is present.

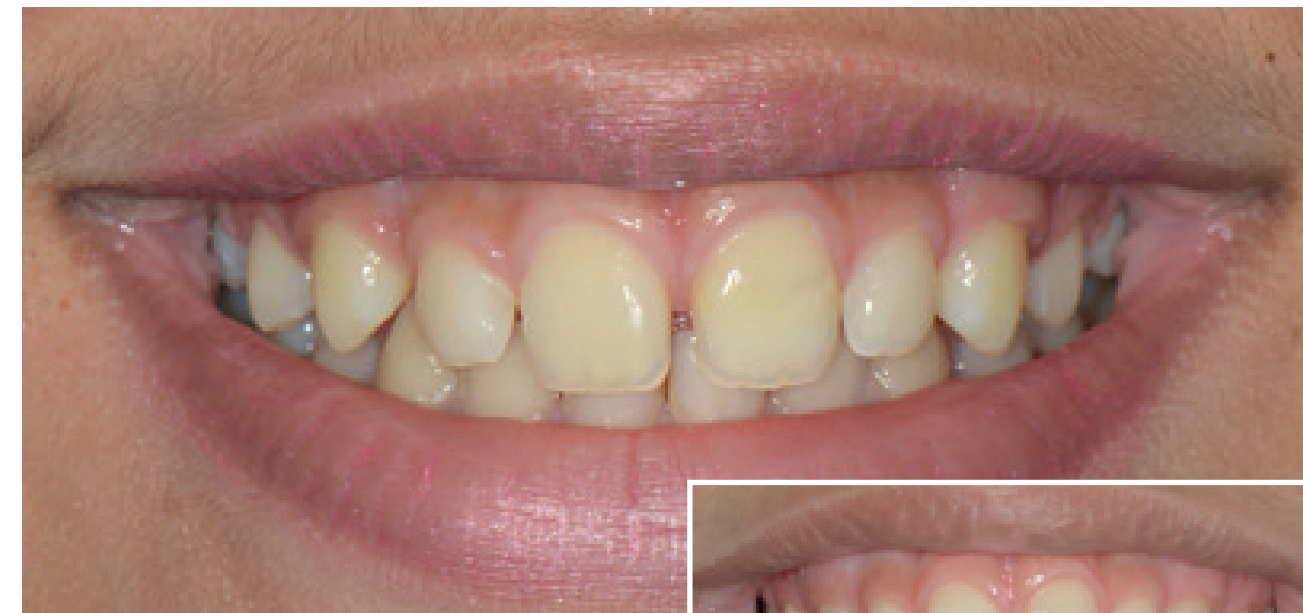

Fig. 12: Final outcome after one month.

References

- M. Hernandez, J.R. Boj, E. Espasa, Do We Really Know the Prevalence of MIH?, *The Journal of clinical pediatric dentistry* 40(4) (2016) 259-63.
- J.E. Mangum, F.A. Crombie, N. Kilpatrick, D.J. Manton, M.J. Hubbard, Surface integrity governs the proteome of hypomineralized enamel, *Journal of dental research* 89(10) (2010) 1160-5.
- S. Alaluusua, Aetiology of Molar-Incisor Hypomineralization: A systematic review, *European archives of paediatric dentistry : official journal of the European Academy of Paediatric Dentistry* 11 (2010) 53-8.
- C.B. Bozal, A. Kaplan, A. Ortolani, S.G. Cortese, A.M. Biondi, Ultrastructure of the surface of dental enamel with molar incisor hypomineralization (MIH) with and without acid etching, *Acta odontologica latinoamericana : AOL* 28(2) (2015) 192-8.
- F. Crombie, D. Manton, N. Kilpatrick, Aetiology of molar-incisor hypomineralization: a critical review, *International journal of paediatric dentistry / the British Paedodontic Society [and] the International Association of Dentistry for Children* 19(2) (2009) 73-83.
- F.A. Crombie, D.J. Manton, J.E. Palamara, I. Zaliziak, N.J. Cochrane, E.C. Reynolds, Characterisation of developmentally hypomineralised human enamel, *Journal of dentistry* 41(7) (2013) 611-8.
- A.M. Biondi, S.G. Cortese, K. Martinez, A.M. Ortolani, P.M. Sebelli, M. Ienco, V.H. Pavan, N. Mendel, M. Bertolino, P. Hecht, Prevalence of molar incisor hypomineralization in the city of Buenos Aires, *Acta odontologica latinoamericana : AOL* 24(1) (2011) 81-5.
- M. Restrepo, F. Jeremias, L. Santos-Pinto, R.C. Cordeiro, A.C. Zuanon, Effect of Fluoride Varnish on Enamel Remineralization in Anterior Teeth with Molar Incisor Hypomineralization, *The Journal of clinical pediatric dentistry* 40(3) (2016) 207-10.
- M.D. Lagerweij, J.M. ten Cate, Remineralisation of enamel lesions with daily applications of a high-concentration fluoride gel and a fluoridated toothpaste: an in situ study, *Caries research* 36(4) (2002) 270-4.
- J.M. Ferreira, A.K. Aragao, A.D. Rosa, F.C. Sampaio, V.A. Menezes, Therapeutic effect of two fluoride varnishes on white spot lesions: a randomized clinical trial, *Brazilian oral research* 23(4) (2009) 446-51.
- S. Paris, H. Meyer-Lueckel, A.M. Kielbassa, Resin infiltration of natural caries lesions, *Journal of dental research* 86(7) (2007) 662-6.
- S. Paris, H. Meyer-Lueckel, H. Colfen, A.M. Kielbassa, Penetration coefficients of commercially available and experimental composites intended to infiltrate enamel carious lesions, *Dental materials : official publication of the Academy of Dental Materials* 23(6) (2007) 742-8.
- H. Meyer-Lueckel, S. Paris, Improved resin infiltration of natural caries lesions, *Journal of dental research* 87(12) (2008) 1112-6.
- S. Paris, H. Meyer-Lueckel, Masking of labial enamel white spot lesions by resin infiltration--a clinical report, *Quintessence international* 40(9) (2009) 713-8.
- S. Paris, H. Meyer-Lueckel, H. Colfen, A.M. Kielbassa, Resin infiltration of artificial enamel caries lesions with experimental light curing resins, *Dental materials journal* 26(4) (2007) 582-8.
- N. Rey, N. Benbachir, T. Bortolotto, I. Krejci, Evaluation of the staining potential of a caries infiltrant in comparison to other products, *Dental materials journal* 33(1) (2014) 86-91.
- A.M. Kielbassa, J. Muller, C.R. Gernhardt, Closing the gap between oral hygiene and minimally invasive dentistry: A review on the resin infiltration technique of incipient (proximal) enamel lesions, *Quintessence international* 40(8) (2009) 663-681.
- J.H. Phark, S. Duarte, Jr., H. Meyer-Lueckel, S. Paris, Caries infiltration with resins: a novel treatment option for interproximal caries, *Compendium of continuing education in dentistry* 30 Spec No 3 (2009) 13-7.
- S. Paris, H. Meyer-Lueckel, Inhibition of caries progression by resin infiltration in situ, *Caries research* 44(1) (2010) 47-54.
- S. Paris, F. Schwendicke, J. Keltch, C. Dorfer, H. Meyer-Lueckel, Masking of white spot lesions by resin infiltration in vitro, *Journal of dentistry* 41 Suppl 5 (2013) e28-34.
- J.P. Attal, A. Atlan, M. Denis, E. Vennat, G. Tirlet, White spots on enamel: treatment protocol by superficial or deep infiltration (part 2), *International orthodontics / College europeen d'orthodontie* 12(1) (2014) 1-31.
- C.R. Torres, A.B. Borges, Color masking of developmental enamel defects: a case series, *Operative dentistry* 40(1) (2015) 25-33.
- L. Jia, B. Stawarczyk, P.R. Schmidlin, T. Attin, A. Wiegand, Effect of caries infiltrant application on shear bond strength of different adhesive systems to sound and demineralized enamel, *The journal of adhesive dentistry* 14(6) (2012) 569-74.



Dr. Ryan Li – North China University of Science and Technology (NCST), Tangshan, China

2010

Graduated from Endodontics College of China Medical University

2010 - 2018

Endodontics lecturer at college of Stomatology, North China University of Science and Technology (NCST)

2015 - 2018

Vice director of the Special Demand Departments, Affiliated Stomatology hospital, NCST

2015 - 2018

Visiting professor of Langfang Society of Stomatology

2015 - 2018

Senior lecturer of Sybronendo Dental Institute

Main areas of work:

Nonsurgical Root Canal Therapy, Nonsurgical Root Canal Retreatment, Minimally Invasive Cosmetic Dentistry, Regenerative Endodontic, Microscopic Apical Surgery

Contact:

Dr. Ryan Li, North China University of Science and Technology, School of Stomatology, Hebei Tangshan 063000, China



Dr. Marie Clement – Private Practice, Lyon, France

2005 - 2011

Studies of dentistry at the University of Lyon – France

Since 2011

Private practice in Lyon France (specialist in aesthetic and restorative dentistry)

2013

Post-Graduated in aesthetic dentistry in Strasbourg University France

2012 - 2016

Assistant professor at the Department of Prosthetic Dentistry - University of Lyon –France

Since 2016

Digital Smile Design Instructor

Since 2017

Style Italiano Silver member

Main areas of work :

Aesthetic, conservative and prosthetic dentistry

Contact:

Dr. Marie Clement, 8 avenue Maréchal Foch, 69006 Lyon, France



Dr. Omar Marouane – University of Monastir, Tunisia

2006 - 2012

Studies at the Faculty of Dentistry of Monastir

2013 - 2016

Postgraduate student and speciality training in Restorative Dentistry & Endodontics

2017

National Certificate in Restorative Dentistry & Endodontics

2017

Private Practice in Tunis; Applied learned skills and advancing the study of research involving enamel opacities

Since 2018

Assistant doctor at the Department of Restorative Dentistry and Endodontics

Main areas of work:

White Spots, Enamel Opacities, Resin Infiltration, MIH, endodontic irrigation

Contact:

Omar Marouane, University of Monastir, Dental faculty of Dentistry Monastir, Avenue Avicenne, 5019 Monastir, Tunisia



Dr. Fadwa Chtioui – University of Monastir, Tunisia

2008 - 2014

Studies at the Faculty of Dentistry of Monastir

2015

DDS degree and nomination for the faculty's annual thesis prize

Since 2016

Postgraduate student and speciality training in Restorative Dentistry & Endodontics

02 - 07.2018

selected for the annual postgraduate Scholarship of the Ministry of higher Education of Tunisia for a Clinical training in Paris

2018

Member of the French Society of Endodontics

Main areas of work:

White Spots, Enamel Opacities, Resin Infiltration, MIH, Dental Traumatology

Contact:

Dr. Fadwa Chtioui, University of Monastir, Dental faculty of Dentistry Monastir, Avenue Avicenne, 5019 Monastir, Tunisia



Prof. Dr. Nabiha Douki Zbidi – University of Monastir, Tunisia

1989

DDS National Degree and winner of the national of the best thesis prize

1990

Presidential Award in dentistry

1995 - 07

Postgraduate degree of a dental specialist in Restorative Dentistry & Endodontics

1995 - 11

Assistant professor at the Department of Restorative Dentistry and Endodontics

1997

Associate professor in Restorative dentistry and Endodontics at the University of Dentistry of Monastir and senior lecturer

Since 1999

Head of research unit 03/UR/16-02 (www.recherche-odontologique.com)

Since 2004

University professor in the school of dentistry of Monastir, Tunisia

Since 2006

Head of the Odontology department at the University Hospital of Sahloul - Sousse – Tunisia

Main areas of work:

Restorative Dentistry, Endodontics, Enamel Opacities, Resin Infiltration

Contact:

Prof. Dr. Nabiha Douki Zbidi, University of Monastir, Dental faculty of Dentistry Monastir, Avenue Avicenne, 5019 Monastir, Tunisia



Prof. Dr. Leandro Augusto Hilgert – University of Brasília, Brazil

1999 - 2003

Dental School at the University of Passo Fundo, Brazil

2004 - 2006

Specialization and MSc in Operative Dentistry at the Federal University of Santa Catarina, Brazil

2006 - 2009

PhD in Operative Dentistry at the Federal University of Santa Catarina, Brazil

2008

Visiting Researcher at the Prosthodontics Department of the University of Munich, Germany

2012 - 2015

PhD in Medical Sciences (Cariology/Dentistry) at the Radboud University Nijmegen, Netherlands

2009 - 2018

Adjunct Professor of Operative Dentistry at the University of Brasília, Brazil

Since 2018

Associate Professor of Operative Dentistry at the University of Brasília, Brazil

Main areas of work:

Preventive and Restorative Dentistry focused on Minimum Intervention, Adhesion to enamel and dentin, Tooth Bleaching, Resin Infiltration, Composite Resins.

Contact:

Prof. Dr. Leandro Augusto Hilgert, University of Brasília (UnB), Department of Operative Dentistry, Campus Darcy Ribeiro, 70910-900 - Asa Norte – Brasília, Brazil



MSc. Marília Bizinoto Silva Duarte – University of Brasília, Brazil

2008 - 2012

Dental School at the University of Brasília, Brazil

2013 - 2014

MSc in Health Sciences (Dentistry) at the University of Brasília, Brazil

Since 2016

Lecturer of Operative Dentistry at the University of Brasília, Brazil

Since 2016

PhD candidate in Health Sciences (Dentistry) at the University of Brasília, Brazil

Since 2018

Dentist of the Public Health System of the Federal District, Brazil

Main areas of work:

Resin Infiltration, Enamel Developmental Defects, Preventive and Restorative Dentistry focused on minimum intervention.

Contact:

MSc. Marilia Bizinoto Silva Duarte, University of Brasília (UnB), Department of Operative Dentistry, Campus Darcy Ribeiro, 70910-900 - Asa Norte – Brasília, Brazil



Prof. Dr. Vera Mendes Soviero – Universidade do Estado do Rio de Janeiro and Faculdade Arthur Sá Earp Neto, Brazil

1991

Graduation in Dentistry at Universidade do Estado do Rio de Janeiro, Brazil

1994

Master Degree at Universidade Federal do Rio de Janeiro, Brazil

1997

PhD Degree at Universidade Federal do Rio de Janeiro, Brazil

Since 1999

Associate professor at Universidade do Estado do Rio de Janeiro, Brazil

Since 2015

Dean of the Dental School at Faculdade Arthur Sá Earp Neto, Brazil

Main areas of work:

Clinical studies on Cariology and Enamel defects

Contact:

Prof. Dr. Vera Mendes Soviero, Universidade do Estado do Rio de Janeiro, Av. 28 de Setembro 157 – 2o andar, 20551-030 Rio de Janeiro, Brazil



Prof. Dr. Neeraj Gugnani – DAV (C) Dental College, Haryana, India

1991 - 1996

BDS study at DAV (C) Dental College Yamunanagar

1997 - 2000

MDS study in Pediatric and Preventive Dentistry at King George's Medical College, Lucknow

April 2000

faculty member at DAV (C) Dental College Yamunanagar and since 2008 Professor at the same institute

2009

Joined as Commonwealth Scholar at Dental Health Unit, University of Manchester, UK, for research training in the field of Dental caries, especially Early Caries Detection and Management.

2011

Awarded ORCA travel fellow award for research proposal regarding management of white spot lesions using Resin Infiltration and other non-invasive strategies

2012 - 2014

Completed MSc in Clinical Trials (with Distinction) from London School of Hygiene and Tropical Medicine, University of London, UK.

Main areas of work:

Caries detection and management including Caries risk assessment, Minimal Invasive Dentistry, Community level prevention of Caries, Dental traumatology and restoration, Pediatric dentistry, Conducting Phase III and IV Clinical Trials, Establishing academic and corporate partnerships, Clinical teaching and Training for effective research methodologies and Systematic Reviews.

Contact:

Prof. Dr. Neeraj Gugnani, DAV (C)Dental college, Department of Pedodontics & PCD, Yamuna Nagar 135001, Haryana, India



82

83

Dr. Arzu Tuna – myveneers, Cologne, Germany

1990 - 1997

Studies of dentistry at the University of Cologne

1998 - 2012

Assistant professor at the Department of Operative Dentistry and Periodontology, University of Cologne

2002

Graduation to Dr. med. dent.

Since 2012


private practice Attendorn with Dr. Umut Baysal

Since 2016

private practice myveneers in Cologne, Germany, with Dr. Umut Baysal

2017

Founding of MYV Smileclub



Main areas of work:

Paediatric dentistry, Aesthetic dentistry, Aligner Orthodontics

Contact:

Dr. Arzu Tuna, Praxis am Nordwall, Nordwall 2, 57439 Attendorn, Germany

Dr. Jean-Pierre Attal – University of Paris Descartes, France

1983 - 1988

Studies of dentistry at the University of Paris Descartes

1991 - 1995

Assistant professor at the Department of Dental Materials (Paris Descartes)

1995

PhD directed by Pr Michel Degrange

Since 1997

Senior lecturer

Since 2008

Accreditation to supervise research

Since 2015


Director of the dental materials lab URB2i (EA 4462)

Since 2015

President of the French Society of Biomaterials (SFBd)

Since 2016

Redactor in chief of the Biomaterials Clinic Journal, Director of a Master in Biomaterials Engineering (Paris Descartes), Private Practice from 1990 until now in Paris



Main areas of work:

Adhesion to calcified tissues, Glass ionomer cements, CAD-CAM materials, Dental bleaching and resin infiltration

Contact:

Dr. Jean-Pierre Attal, Université Paris Descartes, 9, boulevard Arago, 75013 Paris, France

Associate Prof. Carlos Rocha Gomes Torres – Sao Paulo State University - UNESP, Brazil

1992 - 1995

Undergraduate studies at Sao Jose dos Campos School of Dentistry, Sao Paulo State University – UNESP

1996 - 2002

Private practice in Sao Paulo State

1999 - 2002

PhD degree in Operative Dentistry at Sao Paulo State University – UNESP

2002 - 2013

Doctor assistant professor at the Department of Restorative Dentistry, Sao Paulo State University – UNESP

2009


Postdoctoral researcher at the University of Zurich – Switzerland

2013

Habilitation in Operative Dentistry at Sao Paulo State University – UNESP

Since 2013

Associate professor at the Department of Restorative Dentistry, Sao Paulo State University – UNESP



Main areas of work:

Esthetic treatments, Dental bleaching, Caries, Dental Erosion, Adhesives, Composites

Contact:

Prof. Carlos Rocha Gomes Torres, Universidade Estadual Paulista – UNESP, Faculdade de Odontologia de Sao José dos Campos, Av. Eng. Francisco José Longo, 777, Jd. Sao Dimas, Sao José dos Campos – Sao Paulo, Brazil

Prof. Dr. Zafer Cehreli – Hacettepe University, Ankara, Turkey

Professor of Pediatric Dentistry at Hacettepe University

Professor of Pediatric Dentistry at Louisiana State University Health Sciences Center


Chair, Education Committee, International Association of Dental Traumatology

Main areas of work:

Minimally invasive restorative dentistry, Pediatric Endodontics, Dental Traumatology, Biocompatibility and biomechanical testing

Contact:

Prof. Dr. Zafer Cehreli, Hacettepe Üniversitesi, Diş Hekimliği Fakültesi, Çocuk Ve Ergen Dişhekimisi, 06100 Sıhhiye Ankara, Turkey



Prof. Dr. David J. Manton – University of Melbourne, Melbourne, Australia

1984

Graduated BDS at the University of Melbourne

1984 - 1991

General practice

1991 - 1993

MDS in Paediatric Dentistry

1994 - 1996


Dental Adviser to Commonwealth Department of Human Services

2002 - 2006

Lecturer at the University of Melbourne

Since 2006

Elsdon Storey Chair of Child Dental Health and Head of the section of Growth and Development at The University of Melbourne



Main areas of work:

all aspects of paediatric dentistry, enamel de- and remineralisation, teledentistry, and MIH.

Contact:

Prof. Dr. David J. Manton, The University of Melbourne, Faculty of Medicine, Dentistry & Health Sciences, Room 5.103 | Level 5, 720 Swanston St Victoria 3010 Australia

Dr. Richard Johannes Wierichs – RWTH Aachen University, Aachen, Germany

2006 - 2011

Studies of dentistry at the University of Bonn (Rheinische Friedrich-Wilhelms-Universität Bonn), Germany

2012

Graduation to Dr. med. dent. at the University of Bonn (Rheinische Friedrich-Wilhelms-Universität Bonn), Germany

2012

Private practice in Neuwied, Germany

2012 - 2016


Assistant professor at the Department of Operative Dentistry, Periodontology and Preventive Dentistry, RWTH Aachen University, Aachen, Germany

Since 2016

Assistant professor and senior physician at the Department of Operative Dentistry, Periodontology and Preventive Dentistry, RWTH Aachen University, Aachen, Germany

Since 2017

Scholarship holder of the medical faculty at the Department of Biohybrid & Medical Textiles, Institute of Applied Medical Engineering, RWTH Aachen University, Aachen, Germany



Main areas of work:

Non-/microinvasive therapies of caries, Root caries, De-/remineralization of dental hard tissue, Antibacterial therapy of dental hard tissue, Healthcare research

Contact:

Dr. Richard Johannes Wierichs, Rheinisch-Westfälische Technische Hochschule Aachen (RWTH), Klinik für Zahnerhaltung, Parodontologie und Präventive Zahnheilkunde, Pauwelsstraße 30, 52074 Aachen, Germany

Dr. Carla Cohn – Kids Dental and Western Surgical Centre Winnipeg, Manitoba, Canada

1984 - 1987

University of Manitoba Faculty of Sciences undergraduate programme

1987 - 1991

University of Manitoba Faculty of Dentistry

1991

Graduated Faculty of Dentistry with DMD (Doctor of Dental Medicine)

1991 - 1992

Health Sciences Centre Children's Hospital Dental Internship

1992

Certificate of Internship of Children's Dentistry

1992


present: part-time clinical instructor University of Manitoba Faculty of Dentistry

1992

present: private dental practice Kids Dental and Western Surgical Centre

2009

present: key opinion leader / lecturer



Main areas of work:

Paediatric Dentistry, lecturer on »paediatric dentistry for the general practitioner«

Contact:

Dr. Carla Cohn, Kids Dental 128-2025 Corydon Avenue Winnipeg Manitoba Canada R3P 0N5,

Associate Prof. Dr. Giuseppe Allocca – University of Milan, Italy

2000 - 2001

Studies of Pharmacy at the University of Milan

2001 - 2003

Studies of Dental Hygiene at Medical- School University of Milan

2004

Graduated- Enabling of Dental Hygiene at Medical School - University of Milan

Since 2004

Private practice in Milano – Lodi- Bergamo, Italy

2014 - 2016


Professor a/c of Applied Medical Technical Sciences - Department of Operative Dentistry – University of Milan

Since 2015

Supervisor courses Hard Tissues -Periodontology and Preventive Dentistry

2014 - 2018

Professor a/c of Internship (Tirocinio clinico)- Department of Operative Dentistry – University of Milan



Main areas of work:

Microinvasive therapies of caries, Root caries, Fluorosis and MIH, remineralization of dental hard tissue, Antibacterial therapy of dental hard tissue, Dental Aesthetics-Healthcare research

Contact:

Prof. Dr. Giuseppe Allocca, the University of Milan Faculty of Medicine Dentistry & Health Sciences , Via Festa del Perdono 7 - 20122 Milano- Dental School via della commenda 10-12 Milan, Email: alloccagiuseppe@unimi.it

84

85

DMG

Chemisch-Pharmazeutische Fabrik GmbH

Elbgaustraße 248 22547 Hamburg Germany

For: +49. (0) 40. 84 006-0 Fax: +49. (0) 40. 84 006-222

info@dmg-dental.com www.dmg-dental.com

www.facebook.com/dmgdental

